



RESEARCH ARTICLE

DEVELOPMENT OF SPINOCELLULAR CARCINOMA WITH THE PRESENCE OF HPV PAIRS 16 AND 18, IDENTIFIED BY PCR, AFTER PREVIOUS DIAGNOSIS OF VULGAR WART

Rodolfo Georgevich Neto, Camila Correia dos Santos, Halbert Villalba, Mônica Grazieli Corrêa and Elcio Magdalena Giovani

Rua Augusto Tolle, 875, cj. 23, Santana, São Paulo, SP, Brazil

ARTICLE INFO

Article History:

Received 25<sup>th</sup> February, 2018  
Received in revised form  
10<sup>th</sup> March, 2018  
Accepted 20<sup>th</sup> April, 2018  
Published online 30<sup>th</sup> May, 2018

Key words:

PCR, neoplasia, HPV,  
Malignant neoplastic,  
Tissue analysis.

ABSTRACT

The human papilloma virus (HPV) has a high potential for transmission and contamination among the population. HPV infection is closely related to host cell differentiation and remodeling. The virus changes the proliferative capacity of the epithelium, the more superficial stratified layers remain proliferative, including the most differentiated strata, generating exophytic epithelial growth. The oncogenic potential is related to the insertion of viral DNA into the host genome. HPV integrates into the genomic DNA of the host epithelial cell and mediated by two viral proteins from the E6 and E7 viral region, prevents cell cycle arrest. HPV 16 and 18 subtypes have a high incidence in detections of malignant neoplastic lesions. This work assisted a case of HPV detection in a preventive process of malignant neoplasias, being part of the research supported by the Brazilian PROSUP / CAPES program. Clinical dentistry and laboratory procedures are described in detail in order to understand the possible relation between HPV and carcinogenesis in the oral region. The key role of patient follow-up after the appearance of an HPV lesion is highlighted.

Copyright © 2018, Rodolfo Georgevich Neto et al. This is an open access article distributed under the Creative Commons Attribution License, which permits unrestricted use, distribution, and reproduction in any medium, provided the original work is properly cited.

Citation: Rodolfo Georgevich Neto, Camila Correia dos Santos, Halbert Villalba, Mônica Grazieli Corrêa and Elcio Magdalena Giovani, 2018. "Development of spinocellular carcinoma with the presence of hpv pairs 16 and 18, identified by pcr, after previous diagnosis of vulgar wart", *International Journal of Current Research*, 10, (05), 69473-69478.

INTRODUCTION

Human papillomavirus (HPV) is a non-enveloped virus with a 55 nm diameter capsid showing a DNA double-strand of approximately 8,000 base pairs (bp), presenting tropism by the epithelial tissue. (Vidal *et al*, 2012). There are more than 150 HPV types identified, 24 were associated with oral lesions (HPV-1, 2, 3, 4, 6, 7, 10, 11, 13, 16, 18, 30, 31, 32, 33, 35, 45, 52, 55, 57, 59, 69, 72, 73), with HPV 16 and 18 being the most prevalent in both oral and genital lesions (Bouda, *et al.*, 1996). HPV infection is closely related to host cell differentiation and remodeling. The virus changes the proliferative capacity of the epithelium, the more superficial stratified layers remain proliferative, including the most differentiated strata, generating an exophytic epithelial growth of clinical aspect of cauliflower (Vidal *et al*, 2012; Stoopler *et al*, 2011). The virus penetrates the cell, migrates to the nucleus and remains circular in the nucleus of the host cell (episomal form), not integrated to the DNA of the same. After its establishment, the HPV begins its replication in the host cell reaching the number of 50/100 episomes per cell. As the basal cell divides, HPV episomes are also replicated and distributed between the daughter cells.

Through a process not yet known, HPV integrates into the genomic DNA of the host epithelial cell and mediated by two viral proteins, E6 and E7, prevents cell cycle arrest, even from differentiated cells that migrate to the more superficial layers of the epithelium (Vidal *et al*, 2012). HPV contamination is caused by micro-traumas, for example through the practice of oral sex, use of contaminated and shared toothbrushes, allowing invasion of the virus to host epithelial cells. Men have a higher incidence of infection compared to women (D'Souza *et al*, 2016). Most HPV infections are eliminated naturally by our immune system (Skinner, 2016). Villagómez-Ortiz (2016) reports that the oncogenic potential is related to the insertion of viral DNA into the host genome, specifically in the E6 and E7 region, with inhibition of tumor suppressor factors (p53) and pRb (retinoblastoma protein) - being these proteins are fundamental for the control of the cell cycle. The incidence of squamous cell carcinoma in the oropharynx region with the highest incidence of HPV has been reported in the last decade (Agalliu *et al*, 2016, Phusingha *et al*, 2016; Petito *et al*, 2016) detecting HPV DNA in the samples of oncogenic tissue. The average prevalence of HPV in the oral mucosa has been described between 20 to 30%. (Miller *et al.*, 2009). The most recent data show that oral cancer had an estimated 15,490 new cases in Brazil, with 11,140 men and

\*Corresponding author: Rodolfo Georgevich Neto  
Rua Augusto Tolle, 875, cj. 23, Santana, São Paulo, SP, Brazil

4,350 women (INCA - 2016). In the oral cavity, HPV is responsible for four types of clinically observed lesions: squamous papilloma, vulgar wart, condyloma acuminata and focal epithelial hyperplasia. The most advisable treatment for localized lesions in the mouth is surgical removal, as it offers the possibility of eliminating the problem in addition to confirming the clinical diagnosis through histopathological examination, but other options such as chemical cauterization, high-power laser, cryotherapy are also recommended and recommended. (Moura, 2005). PCR is a technique that has revolutionized virology because of its extremely high sensitivity. It is characterized by the amplification of minute quantities of target DNA sequence by several million times. It is a thermal-cyclic process that includes three steps: denaturation where the double strand of DNA is separated into single strands; annealing phase, when the primers specifically anneal to their complementary single stranded target DNA sequences, and finally primer extension, where a thermostable DNA polymerase generates DNA "daughter" strands that cross the region between two primers. Thereafter the newly generated double strands serve as templates for a subsequent PCR cycle. Primers may be: type-specific primers that detect a single type of HPV, or consensus primers (also called general or generic) that detect a panel of different types of HPV in a single reaction. HPV detection by PCR is generally performed using one of the consensus primers, MY09-MY or GP5 / GP6. Currently, CRP allows a thorough evaluation of epidemiological data, including the prevalence of subclinical or latent infections. However, it has the following disadvantages: amplification of tiny amounts of contaminating HPV DNA, which can lead to false positive results (Castro, *et al*, 2006). Therefore, the detection of HPV allows a stage of preventive treatment for malignant neoplasms, and it is fundamental to follow the patient in a proserivative way, as seen in the report of this clinical case.

## CASE REPORT

Patient ALG, 58 years old, male, leucoderma, native of the city of Montevideo, Uruguay, attended the dental clinic of the Faculty of Dentistry of the Paulista University in the city of São Paulo, Brazil, complaining of a lesion in bottom lip. started 6 months ago, and in continuous development. The patient reported that in 2015, a lesion with a similar appearance had already arisen in the same region and that it was treated by surgical removal (biopsy) for anatomopathological examination. The size of the lesion biopsied at that time was 1.5 x 1.2 x 0.4 cm, with brownish color, firm to the touch and granular appearance, the result of which was histological examination of hyperkeratosis, parakeratosis, acanthosis and papillomatosis. Epidermal projections were elongated toward the dermis, with recurved extremities converging to the central axis of the lesion. In the prickly and granular layers cells were observed with clear, vacuolated cytoplasm with round and intensely stained nuclei enveloped by light halo (characteristics of koilocytosis). In other cells abundant cytoplasm, basophil, hyaline, with vesiculous nuclei and increased. All histological alterations suggestive of HPV, but without signs of malignancy. In the recurrence of the lesion, in 2016, the presence of nodular lesion with exophytic growth, with irregular borders, rough surface, center of the lesion with brownish color, firm-elastic consistency, ulcerated, bleeding, without determination of the its borders, involving vermillion of the lower lip, according to Figure 1.

In view of the patient's history and clinical examination, the diagnostic hypothesis of squamous cell carcinoma, possibly etiology stimulated by HPV, was suggested. Therefore, an incisional biopsy was performed (Figure 2), collecting 0.6 x 0.5 x 0.3 cm from the lesion region of the lower lip and the material was referred for anatomopathological examination. The result observed in histological processing was compatibility with squamous cell carcinoma (Figures 3, 4 and 5). Cellular pleoformism, nuclear hyperchromatism, nucleus and cytoplasm alteration, atypical mitoses, peroneal corneal formation, acanthosis, stratified squamous epithelial cells with intranuclear vascularizations compatible with viral infection, digitiform projections, cells with a ballooned aspect and nuclei in halo (coylocytes) - which suggested compatibility with HPV presence, being indicative of confirmation, with the diagnosis via molecular biology (Polymerase Chain Reaction - PCR).

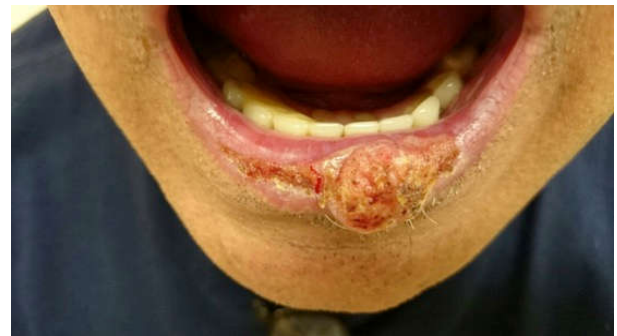

Figure 1. Clinical aspect of the lesion in continuous development for six months (2016)

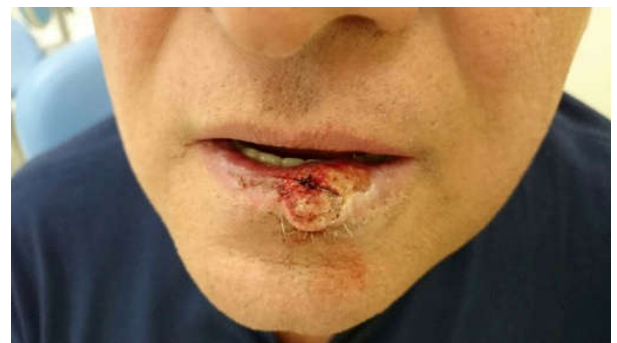

Figure 2. Injured region with simple suture with nylon 4.0. after incisional biopsy

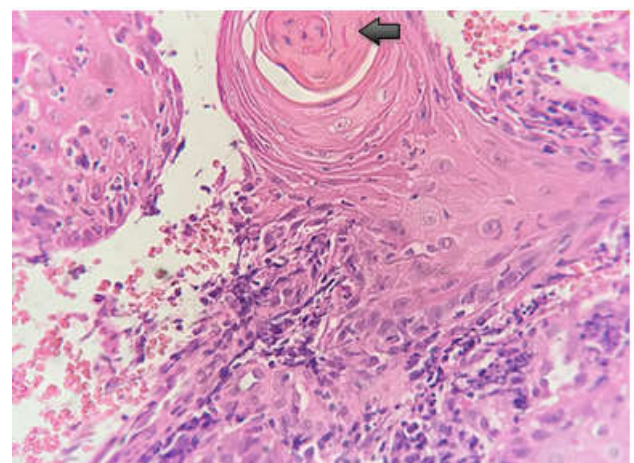
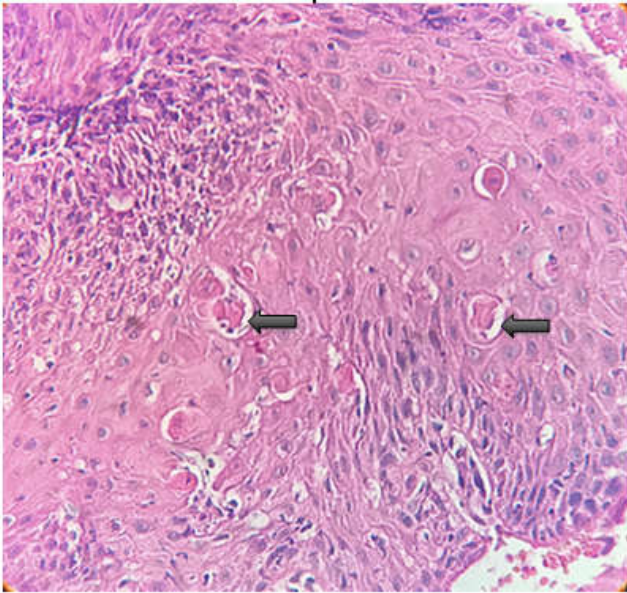
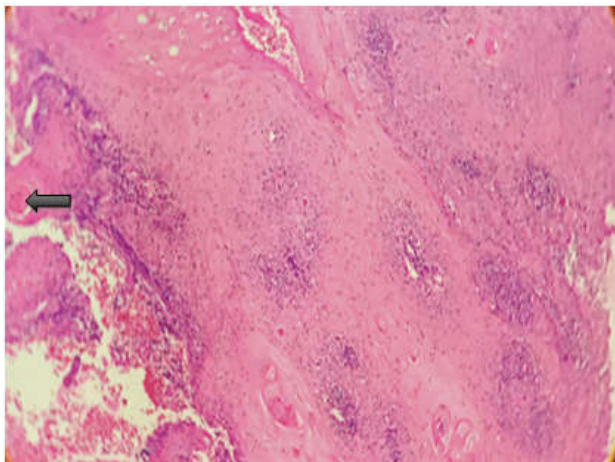


Figure 3. Photomicrograph of squamous cell carcinoma 400x magnification, H / E: Note the formation of keratin pearl (arrow) and cellular polymorphism, as well as polychromasia



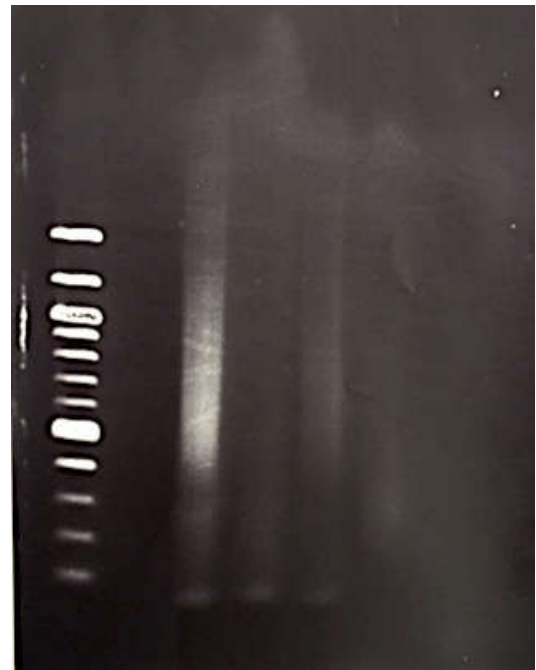
**Figure 4. Photomicrograph of Spinocellular Carcinoma, 400x magnification, H / E: We note proliferative neoplastic epithelium with areas of dyskeratosis (arrows) and cellular pleomorphism**



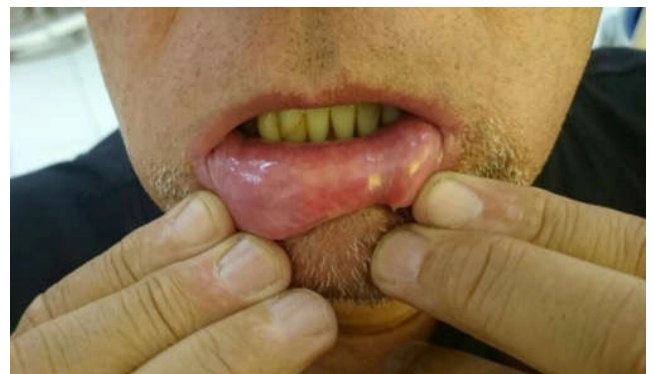**Figure 5. Photomicrograph of Spinocellular Carcinoma, 40x magnification, H / E: We note proliferative neoplastic epithelium with corneal pearl formation (arrow)**

HPV detection by PCR is generally performed using one of the consensus primers, MY09-MY or GP5 / GP6. Due to the paraffin waxing by anatomopathological examination, we performed DNA extraction with the QIAamp DNA FFPE Tissue kit protocol. The quality of the extracted DNA was evaluated with rapid test in Nanodrop®, indicating the viable amount of nucleic acid present for PCR. DNA integrity after extraction was confirmed through the PCR step, using the first PCO (Reverse: ACACAACGTGTGTTCACTAGC3; Forward: CAACCTCATCCACGTTCCACC5'- 110 base pairs). The presence of HPV DNA was evaluated by PCR using the first GP5 + and GP6 +, by the HPV L1 gene, (Reverse: CTTATACTAAATGTCAAATAAAAAG3'; Forward: TTTGTTACTGTGGTAGATACTAC5' - 150 base pairs). The amplification of HPV-16 and HPV-18 was performed after we found a positive result for HPV, via PCR, and thus with primers specific for the HPV-16 and HPV-18 subtypes. The specific primers used for amplification were: HPV-16 / -18 (Forward: GGTCGGTGGACCGGTCGATG5' CTTTGGACGTAATTTTTGG5', and HPV-16 / -18 (Reverse: (GCAATGTAGGTGTATCTCCA3') CACGCACACGC

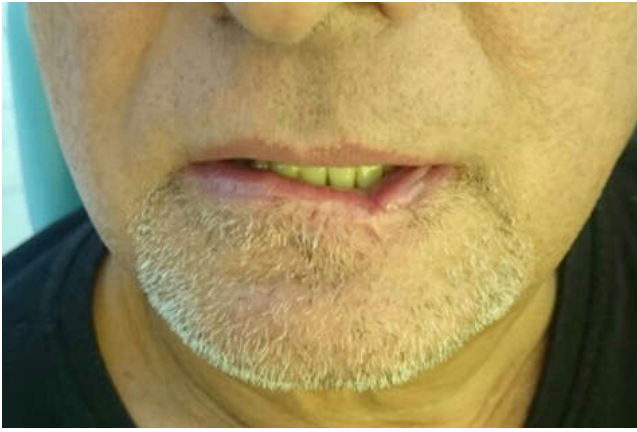TTGGCAGGT3' respectively - 108 base pairs for HPV- 16 and 104 base pairs for HPV-18.) The products of the PCR cycles were placed in culture medium at 1% agarose gel and stained by Loading Dye Purple Gel (BioLabs). For electrophoresis (120V, 400 mA for 2 h), a known molecular weight marker (100 bp) was used as reference, a negative control (pure water) and the resulting PCR samples, and the reading indicated the presence of HPV-16 DNA and - 18 (Figure 6). Immediately after the finding of the disease by pathological examination, the patient was referred to the oncologist who instituted the total removal of the lesion with safety margins in the volume of 2.6 x 1.5 x 1.2 cm removed, with an ulcerated area of 2.4 cm. To the cuts, constituted by whitish, friable tissue, measuring 0.5cm and distant 0.1cm from the nearest surgical margin. The hematoxylin and eosin staining method was performed again, indicating infiltrative and ulcerated lower lip ulcerated squamous cell carcinoma, with the exception of anterior and posterior surgical margins, right and left lateral margins, and deep free of neoplasias After 2 months of the surgical excision, the patient returned to the dental clinic to follow up the case. There was complete remission of the lesion on the labial mucosa. Loss of part of the vermilion of the lower lip, aesthetic and functional alteration of the region (Figure 7 and 8).



**Figure 6. Result of electrophoresis after PCR with primers of subtypes 16 and 18**

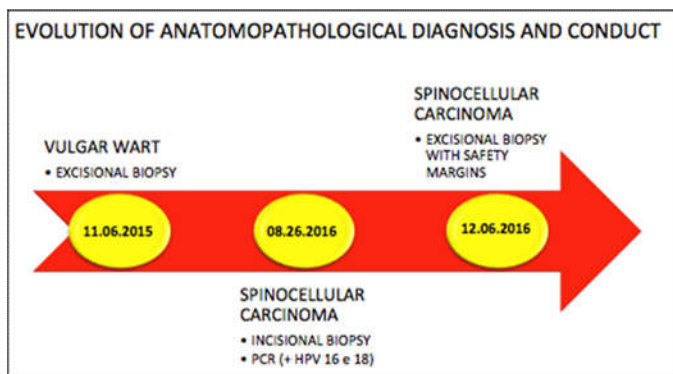


**Figure 7. Clinical aspect of repair after 2 months of total surgical removal with safety margin of squamous cell carcinoma lesion**



**Figure 8.** Clinical aspect after 2 months of the total surgical removal of the lesion, highlighting the alteration of the labial sealing

A summary of the development of lesions in the patient is highlighted in Figure 9.



**Figure 9.** Development of lesions and conducts performed over time

## DISCUSSION

Based on the studies of Miller and White (1996), the average prevalence of HPV in the oral mucosa has been described between 20 to 30%. Although it is an infection with benign manifestation, a potential malignancy potential is observed in a study that notices HPV lesions as comorbidity to other sexually transmitted diseases and a precursor role in oral cavity cancers. Of the more than 150 HPV types identified, 25 were associated with oral lesions (HPV-1, 2, 3, 4, 6, 7, 10, 11, 13, 16, 18, 30, 31, 32, 33, 35, 45, 52, 55, 57, 59, 69, 72, 73), with HPV-16 and -18 being the most prevalent in both oral and genital lesions (Ferraro *et al.*, 2011), which may mean orogenital transmission. In this study, in the confirmed cases of presence of HPV DNA by PCR, 93% were HPV-16 and / or -18 DNA. Subtypes 16 and 18 are considered the most oncogenic, as they are found in carcinomas in genital and oral regions, as seen by Schlecht (2012). In the oral cavity, HPV is responsible for four types of lesions: squamous papilloma, vulgar wart, condyloma acuminata and focal epithelial hyperplasia, according to Ferraro *et al.* 2011. In this research, the diagnostic hypothesis of papilloma was reported in 59% (17 reports). Followed by the hypothesis of condyloma (14% of the cases). Saini *et al.* 2010, emphasized that condylomata should be treated, due to their venereal transmission and the possibility of malignant transformation. Confirmation of condyloma acuminata lesions in the mouth may often suggest

the investigation of possible HIV seropositivity, as observed by Castro and Bussoloti (2006). Therefore, in the study, 67% of the cases of HPV detection correlated with the presence of the virus in group I, which also presented the condition of comorbidity with HIV / Aids. In the work of Villagómez-Ortiz *et al.* 2016, it was verified that the majority of the individuals with normal immunological activity are able to eliminate the infections of clinical manifestations, being only 10% incapable. Therefore, the lower prevalence of HPV manifestations in patients in group II can be correlated in this sense. We highlight the study published in The New England Journal of Medicine with more than 1900 patients, Muñoz *et al.* 2003, have reported the identification of specific HPV subtypes that are related to malignant neoplastic transformation. Being the -16 and -18 the most prevalent and oncogenic. This prevalence was also observed in this study. In another article in the same journal, a study was conducted on 100 men and women newly diagnosed with the cancerous disease and 200 healthy people; found that a common strain of HPV-16 was found in 72% of tumors. Patients whose blood or saliva samples indicated previous HPV infection were 32 times more likely to develop oropharyngeal cancer, which reaches the throat, tonsils and the back of the tongue, according to a study by D'Souza *et al.* 2007. Emphasizing the importance of HPV detection in the oral mucosa. In the meta-analysis of Jayaprakash *et al.* 2011, analyzed 22 studies that presented the prevalence of HPV-16 and / or -18 in 458 lesions of oropharyngeal dysplasias. The results indicated that infection by these HPV subtypes occurs at an early stage precursor to carcinogenesis in the region. Thus, it is fundamental to implement a preservation of HPV-infected patients and their -16 and -18 subtypes compatible with our findings in the oral region, reinforcing the need for continuous preventive conduct.

## Conclusion

- From the identification of HPV lesions, it is essential to take therapeutic surgical procedures or even other conduits such as chemical and high-power laser cauterization and effective preservation of the patient, with consultations at most every 6 months.
- The clinical identification, associated with the pathology and the PCR technique in the diagnosis of oral manifestations of HPV, are important instruments in the accomplishment and diagnostic confirmation of the manifestation.
- Diagnosis, counseling, and care about manifestations of sexually transmitted diseases, such as HPV infection, play a key role that the Dentist and every healthcare professional should play in a social context.
- Oral manifestations of HPV according to its subtypes, especially pairs 16 and 18 are important oncogenic factors, favoring the development of squamous cell carcinoma, and it is also considered an important cofactor to acquire other STDs, mainly HIV.

## REFERENCES

- Anaya-saavedra, g.; Ramírez-amador, v.; Irigoyen-camacho, m. e.; Guido-jiménez, m.; Méndez-martínez, r.; García-carrancá, A. 2008. High association of human papillomavirus infection with oral cancer: a case-control study. *Archives of medical research*, v. 39, n. 2, p. 189 – 197, Fevereiro.

- Ang, K. K.; Harris, J.; Wheeler, R.; Weber, R.; ROSENTHAL, D. I.; Nguyen-TAN, P. F.; Westra, W. H.; Chung, C. H.; Jordan, R. C.; Lu, C.; KIM, H.; Axelrod, R.; SILVERMAN, C. C.; Redmond, K. P.; Gillison, M. L. Human papillomavirus and survival of patients with oropharyngeal cancer. *The England Journal of the Medicine*, Inglaterra, v. 363, p. 24 – 35, Junho, 2010.
- Bouda, M.; Gorgoulis, V. G.; Kastrinakis N. G.; Giannoudis, A.; Tsoli, E.; Danassi-Afentaki, D.; FOUKAS, P.; Kyroudi, A.; Laskaris, G.; Herrington, S. H.; Kittas, C. “High Risk” HPV Types Are Frequently Detected in Potentially Malignant and Malignant Oral Lesions, But Not in Normal Oral Mucosa. *Modern Pathology*. v. 13, n. 6, p. 644 – 653, dezembro, 1999.
- Castro, L. A. de, Castro, J. G. L. de, Cruz, A. D. L. de, Barbosa, B. H. de S.; Spindula-Filho, J. V.; Costa, M. B. Focal Epithelial Hyperplasia (Heck’s Disease) in a 57-Year-Old Brazilian Patient: A Case Report and Literature Review. *Journal of Clinical Medicine Research*, Brasil, v. 8, n. 4, p. 346 – 350, Abril, 2016.
- Castro, T. P. P. G.; FILHO, I. B. Prevalência do papilomavírus humano (HPV) na cavidade oral e na orofaringe. *Revista Brasileira Otorrinolaringologia*, Maceio, v. 72, n. 2, p. 272 – 282, março/abril, 2006.
- Chaturvedi, A. K.; Engels, E. A.; Pfeiffer, R. M.; Hernandez, B. Y.; XIAO, W.; Kim, E.; Jiang, B.; Goodman, M. T.; Sibug-Saber, M.; Cozen, W.; Liu, L.; Lynch, C. F.; Wentzensen, N.; Jordan, R. C.; Altekruse, S.; Anderson, W. F.; Rosenberg, P. S.; Gilsson, M. L. Human Papillomavirus and Rising Oropharyngeal Cancer Incidence in the United States. *Journal of Clinical Oncology*. v. 29, n. 32, p. 4294 – 4301, novembro, 2011.
- D’souza, G.; Kreimer, A. R.; Viscidi, R.; Pawlita, M.; Fakhry, C.; Koch, W. M.; Westra, W. H.; Gilsson, M. Case-control study of human papillomavirus and oropharyngeal cancer. *The New England journal of medicine*, v. 356, p. 1944 – 1956, 2007.
- Esquenazi, D.; Filho, I. B.; Carvalho, M. G. C.; Barros, F. S. A frequência do HPV na mucosa oral normal de indivíduos sadios por meio da PCR. *Brazilian Journal of Otorhinolaryngology*, v. 76, n. 1, p. 78 – 84, janeiro/fevereiro, 2010.
- Ferraro, C. T. L.; Canedo, N. H. S.; Oliveira, S. P. de, CARVALHO, M. da G. da C.; DIAS, E. P. Infecção oral pelo HPV e lesões epiteliais proliferativas associadas. *Jornal Brasileiro de Patologia e Medicina Laboratorial*, Rio de Janeiro, v. 47, n. 4, p. 451 – 459, agosto, 2011.
- Georgevich, R. N.; Noro Filho, G. A.; Santos C. C.; Egashira, S.; Andia-Merlin, R.; Giovani, E. M. Levantamento das Manifestações bucais e gerais em pacientes vivendo com o hiv/Aids na era Haart em uma instituição de ensino privada. 33ª Reunião Anual da Sociedade Brasileira de Pesquisa Odontológica, 2016.
- Gillison, M. L.; Broutian, T.; Pickard, R. K. L.; tong, Z.-Y.; xiao, W.; Kahle, L. K.; Graubard, B. I.; Chaturvedi, A. K. Prevalence of oral HPV infection in the United States, 2009-2010. *The Journal of American Medical Association*, v. 307, n. 7, p. 693 – 703, fevereiro, 2012.
- Henn, I. W.; Galina, G.; Chaiben, C. L.; Kula, J.; Santos, J. N. dos, Lima, A. A. S. de. Multiple oral condyloma acuminatum in a patient with HIV/AIDS – A case report. *Elsevier*, v. 3, n. 2014, p. 160 – 164, maio, 2014.
- Herrero, R.; Castellsagué, X.; Pawlita, M.; Lissowska, J.; Kee, F.; Balaram, P.; Rajkumar, T.; Sridhar, H.; Rose, B.; Pintos, J.; Fernández, L.; Idris, A.; Sánchez, M. J.; Nieto, A.; Talamini, R.; Tavani, A.; Bosch, F. X.; Reidel, U.; Snijders, P. J. F.; Meijer, C. J. L. M.; Viscidi, R.; Muñoz, N.; Franceschi, S. Human Papillomavirus and Oral Cancer: The International Agency for Research on Cancer Multicenter Study. *Journal of the Nacional Cancer Institute*, San José, Costa Rica, v. 95, n. 23, p. 1772 – 1783, setembro, 2003.
- Husman, A.-M. de R.; Walboomers, J. M. M.; Brule, A. J. C. VAN DEN, MEIJER, C. J. L. M.; SNIJDERS, P. J. F. The use of general primers GP5 and GP6 elongated at their 3’ ends with adjacent highly conserved sequences improves human papillomavirus detection by PCR. *Journal of General Virology*, v. 76, p. 1057 – 1062, novembro, 1995.
- Jayaprakash, V.; Reid, M.; Hatton, E.; Merzianu, M.; Rigual, N.; Marshall, J.; Gill, S.; Frustino, J.; WILDING, G.; LOREE, T.; POPAT, S.; SULLIVAN, M. Human papillomavirus types 16 and 18 in epithelial dysplasia of oral cavity and oropharynx: a meta-analysis, 1985-2010. *Oral oncology*, v. 47, n. 11, p. 1048 – 1054, novembro, 2011.
- Machado, J.; Reis, P. P.; Zhang, T.; Simpson, C.; Xu, W.; Perez-ordonez, B.; Goldstein, D. P.; Brown, D. H.; Gilbert, R. W.; Gullane, P. J.; IRISH, J. C.; Kamel-REID, S. Low prevalence of human papillomavirus in oral cavity carcinomas. *Head & neck oncology*, v. 2, p. 1 – 6, n. 3, 2010.
- Miller, C. S.; White, D. K. Human papillomavirus expression in oral mucosa, premalignant conditions, and squamous cell carcinoma. *Oral Surgery Oral Medicine Oral Pathology Oral Radiology*, Lexington, USA, v. 82, n. 1, p. 57 – 68, Julho, 1996.
- Muñoz, N.; Bosch, F. X.; Sanjosé, S. de, Herrero, R.; Castellsagué, X.; Shah, K. V.; Snijers, P. J. F.; Meijer, C. J. L. M. Epidemiologic Classification of Human Papillomavirus Types Associated with Cervical Cancer. *The England Journal of the Medicine*, v. 348, n. 6, p. 518 – 527, fevereiro, 2003.
- Nascimento, S.; Suarez, E. R.; Pinhal, M. A. da S. Tecnologia de PCR e RT-PCR em tempo real e suas aplicações na área médica. *Especial Oncologia*, v. 67, p. 7 – 19, novembro, 2010.
- Paoli, J.; Bratel, A. T.; Löwhagen, G.-B.; Stenquist, O.; WENNERBERG, A.-M. Penile Intraepithelial Neoplasia: Results of Photodynamic Therapy. *Acta Dermato-Venereologica*, Suécia, v. 86, p. 418 – 421, maio, 2006.
- Reyes, M.; Rojas-Alcayaga, G.; Pennacchiotti, G.; Carrilo, D.; Muñoz, J. P.; Peña, N.; Montes, R.; LOBOS, N.; AGUAYO, F. Human papillomavirus infection in oral squamous cell carcinomas from Chilean patients. *Experimental and molecular pathology*, v. 99, p. 95 – 99, junho, 2015.
- Ritchie, J. M.; Smith, E. M.; Summerhill, K. F.; Hoffman, H. T.; Wang, D.; Klussmann, J. P.; Turek, L.; P.; Haugen, T. H. Human papillomavirus infection as a prognostic factor in carcinomas of the oral cavity and oropharynx. *International journal of cancer*, USA, v. 104, n. 3, p. 336 – 344, 2003.
- Rodrigues, A. D.; Cantarelli V. V.; Frantz M. A.; Pilger, D. A.; Pereira, F. de S. Comparação das técnicas de captura de híbridos e PCR para a detecção de HPV em amostras clínicas. *Jornal Brasileiro de Patologia e Medicina Laboratorial*, v. 45, n. 6, p. 457 – 462, 2009.
- Saini, R.; Khim, T. P.; Rahman, S. A.; Ismail, M.; Tang, T. H. High-risk human papillomavirus in the oral cavity of

- women with cervical cancer, and their children. *Virology journal*, v. 7, n. 131, p. 1 – 6, Junho, 2010.
- Schlecht, H. P. Oral Human Papillomavirus Infection Hazard of Intimacy. *The Journal of American Medical Association*, USA, v. 307, n. 7, p. 724 – 725, fevereiro, 2012.
- SILVA, I. D. C. G. da. *diagnóstico molecular do HPV*. São Paulo, 2015. Disponível em: <[http://www.centrodegenomas.com.br/m175/hpv/diagnostico\\_molecular\\_do\\_hpv](http://www.centrodegenomas.com.br/m175/hpv/diagnostico_molecular_do_hpv)>. Último acesso em: 11 ago. 2015.
- Soares, C. P.; Malavazi, I.; Reis, R. I. dos, Neves, K. A.; Zuanon, J. A. S.; Neto, C. B.; Spolidório, L. C.; Oliveira, M. R. B. de. Presença do papilomavirus humano em lesões malignas de mucosa oral. *Revista da Sociedade Brasileira de Medicina Tropical*, Araraquara, v. 35, n. 5, p. 439 – 444, outubro 2002. Disponível em: <<http://scielo.br/pdf/rsbmt/v35n5/13160.pdf>>. Acesso em: 15 ago. 2015.
- Souza, T. L.; Silva, A. F. A. da, Balarini, G. M.; Paes, C. H. da S.; Meissner, R. de V.; Fernandes, J. V.; Medina-Acosta, E. 2010. Genotipagem do vírus do papilloma humano de alto risco como ferramenta útil em estudos epidemiológicos antes e após a vacinação para prevenção do cancer do colo do útero. *Revista Científica da FMC*, v. 5, n. 2, p. 2 – 6, 2010.
- Stoopler, E. T.; Balasubramaniam, R. Human Papillomavirus Lesions of the Oral Cavity. *The New England Journal of Medicine*, n. 365, p. 17 – 17, Outubro, 2011.
- Taner, Z. M.; Taskiran, C.; Onan, A. M.; GURSOY, R.; HIMMETOGLU, O. Therapeutic value of trichloroacetic acid in the treatment of isolated genital warts on the external female genitalia. *The Journal of Reproductive Medicine*, Turquia, v. 52, p. 521 – 525, junho 2007. Disponível em: <<https://jjtir.files.wordpress.com/2010/12/therapeutic-value-of-trichloroacetic-acid-in-the-treatment-of-isolated-genital-warts-on-the-external-pdf>>. Acesso em 11 set. 2015.
- Vidal, F. C. B.; NASCIMENTO, M. do D. S. B.; FERRARO, C. T. L.; BRITO, L. M. O. Análise crítica dos métodos moleculares para detecção do papilomavírus humano: revisão da literature. *FEMINA*. v. 40, n. 5, p. 263 – 267, setembro/outubro, 2012.
- Villagómez-ORTÍZ, V. J.; Paz-Delgadillo, D. E.; Marino-Martinez, I.; Ceseñas-Falcón, L. Á.; FUENTE, A. S.-D. la, Reyes-Escobedo, A. Prevalence of human papillomavirus infection in squamous cell carcinoma of the oral cavity, oropharynx and larynx. *Cirugia y cirujanos*, Março, 2016.
- Xavier, S. D.; Filho, I. B.; Lancellotti, C. L. P. Prevalência de achados sugestivos de papilomavírus humano (HPV) em biópsias de carcinoma espinocelular de cavidade oral e orofaringe: estudo preliminar. *Revista Brasileira de Otorrinolaringologia*, Brasil, v. 71, n. 4, p. 510 – 514, julho/agosto, 2005.

\*\*\*\*\*