



RESEARCH ARTICLE

CEREBELLAR ABSCESS SECONDARY TO DERMAL SINUS ASSOCIATED WITH DERMAL CYST  
IN CHILDREN: REVIEW OF THE LITERATURE AND REPORT OF A RARE CASE

\*Blagia, M., Cascardi, P., Colamaria, A., Bozzi, M.T. and De Tommasi, A.

Medical Doctor, Division of Neurosurgery, University of Bari, Italy

ARTICLE INFO

Article History:

Received 14<sup>th</sup> December, 2017  
Received in revised form  
21<sup>st</sup> January, 2018  
Accepted 25<sup>th</sup> February, 2018  
Published online 28<sup>th</sup> March, 2018

Key words:

Cerebellar Abscess, Dermoid Cyst,  
Cranial Dermal Sinus,  
Posterior Fossa Dermoid Tumors.

ABSTRACT

**Introduction:** Dermal sinus occur in the cranial vault, and the occipital region. Rarely, is localized in the posterior fossa, particularly in the midline position, or in the cavity of the fourth ventricle. It could communicate with the skin through a fistula with potential risk of deeper abscesses. Posterior fossa abscess secondary to dermal sinus associated with intracranial dermal cyst is an uncommon pathology (0,1 to 0,7 %).

**Methods:** A 24-month old girl was admitted to our institution with a cutaneous fistula in the midline of the occipital region. A CT scan and brain MR showed a sottotentorial intradiploic cyst with peripheral enhancement and edema. The mass was hyperintensity on T1-weighted sequences, with lower signal on T2-weighted images. A suboccipital craniotomy was performed with evacuation of the abscess and an excision of the visible capsule with a total removal of a 3 cm whitish, midline, encapsulated cystic mass with hair component.

**Results:** The histologic examination confirmed the diagnosis of abscess associated with dermal cyst and dermal sinus. Post-operative course was uneventful. The patient experienced a sudden improvement of cephalalgia and 15 days after the microsurgical excision, was discharged. On postoperative RM imaging, it was found the total removal of the lesion. A 36 month follow-up no evidence of recurrence.

**Discussion:** Posterior fossa dermoid cyst should be considered in all children with a cutaneous fistula. Early neurosurgical treatment of these benign tumours should be performed to prevent the development of severe intracranial infection. Best results were obtained in cases of early diagnosis and the complete removal of the abscess. The reported case passes through a review of similar cases reported in the literature confirm the rarity of the case report.

Copyright © 2018, Blagia et al. This is an open access article distributed under the Creative Commons Attribution License, which permits unrestricted use, distribution, and reproduction in any medium, provided the original work is properly cited.

Citation: Blagia, M., Cascardi, P., Colamaria, A., Bozzi, M.T. and De Tommasi, A. 2018. "Cerebellar abscess secondary to dermal sinus associated with dermal cyst in children: Review of the literature and report of a rare case", *International Journal of Current Research*, 10, (03), 66662-66666.

INTRODUCTION

The authors present an unusual case of posterior fossa abscess secondary to a dermal sinus associated with intracranial dermal cyst. Intracranial dermoid cysts are rare (0.1 to 0.7% of all intracranial tumors) (Guidetti, 1977; Lunardi et al., 2002; Roberts, 1958; Yasargil, 1989). They mostly occur in the posterior fossa, particularly in the midline position in the vermis or adjacent meninges, or in the cavity of the fourth ventricle (Groen et al., 1995; Higashi et al., 1995; Logue, 1952). In the cranial vault, dermoid cysts are often found at the anterior fontanel and the occipital region (Martinez-Lage et al., 1997). More rarely, dermoid cysts may communicate with the skin through a narrow tract lined by epithelium (dermal sinus), which, therefore, contains the glandular architecture of skin, encouraging infection (Akhaddar et al., 1999; Logue, 1952).

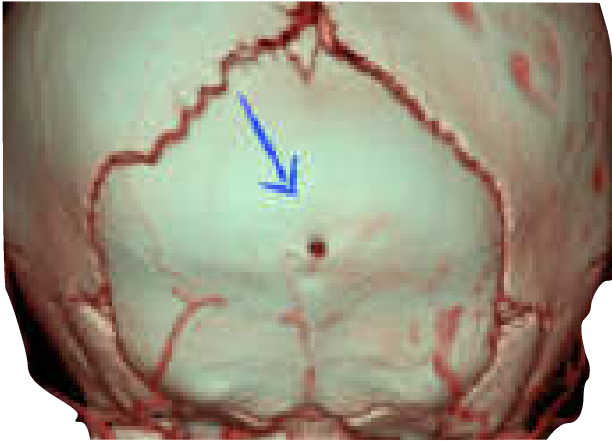These cysts rarely cause abscess formation or formation of daughter abscesses within the cerebellum (Smith, 1959; Starinsky et al., 1988). At present are reported only 16 cases with posterior fossa dermoid cysts causing cerebellar abscesses (Akhaddar et al., 1999; Erdem et al., 1994; Goffin et al., 1993; Groen et al., 1995; Guidetti et al., 1977; Hashmi et al., 1998; Hayek et al., 2001; Higashi et al., 1995; Hsu et al., 1998; Lepindre, 1970; Logue, 1952; Lunardi et al., 2002; Martens et al., 1987; Martin et al., 1943; Martinez-Lage et al., 1992; Martinez-Lage, 1997; Matson, 1951; Roberts, 1958; Rubin, 1989; Schijman, 1986; Smith, 1989; Tekkok, 1996; Tytus, 1956; Vinchon, 1995; Wiemer, 1988; Yasargil, 1989; Wright, 1971; French, 1990; Guidetti, 1977; Matson, 1969; Davidson et al., 1985; Smith et al., 1991).

Case report

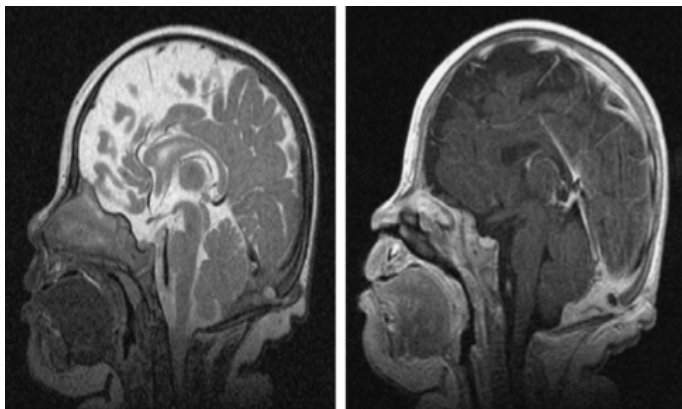
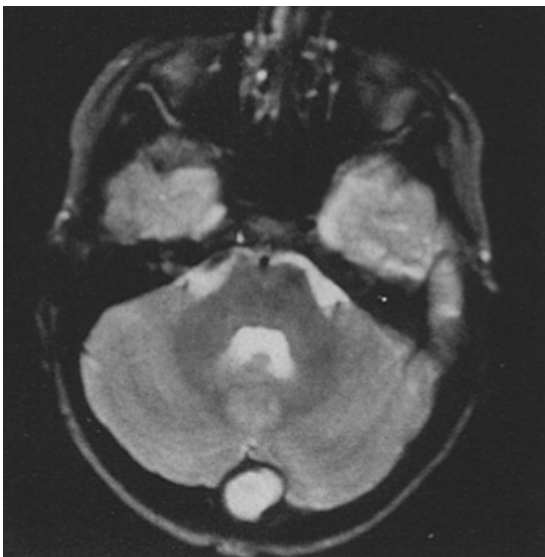A 24-month old girl with a 2-month history of psychomotor retardation signs and weight loss with unremarkable medical history was admitted to our institution.

\*Corresponding author: Blagia, M.,  
Medical Doctor, Division of Neurosurgery, University of Bari, Italy.

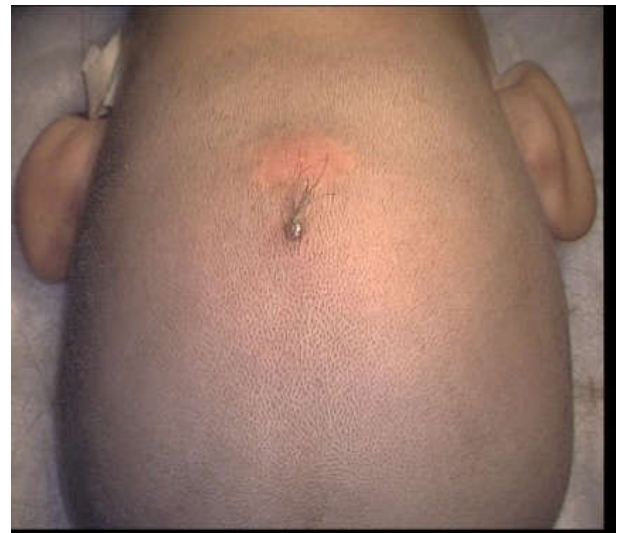Physical examination revealed mild confusion. She present horizontal nystagmus without sensory nor motor deficit. The lesion appeared to communicate with the skin and intracranial space. Emergency CT scan (Fig.1; blue arrow) and brain MR (Fig. 2) showed a cystic subtentorial mass with ring enhancement of the cystic walls. During surgery, a 5 mm small subcutaneous nodule was seen with a small skin fistula opening without pus (Fig. 3) A suboccipital craniotomy was performed.



**Fig. 1:** Emergency head CT scan showing point of communication (blue arrow) between dermoid cyst and skin through the dermal sinus

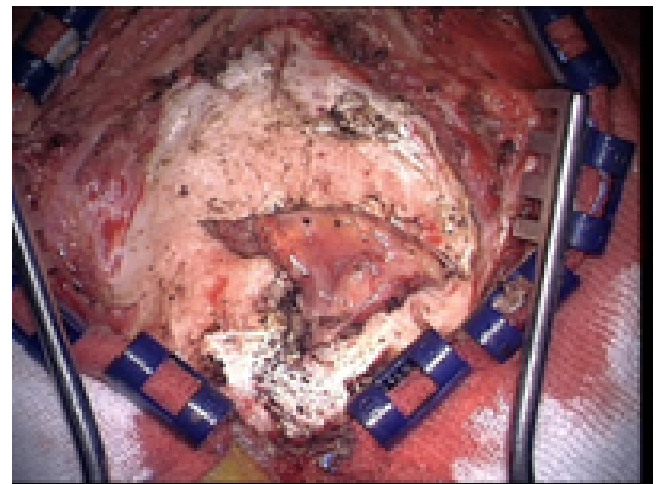


**Fig. 2.** brain MR showing cystic subtentorial mass

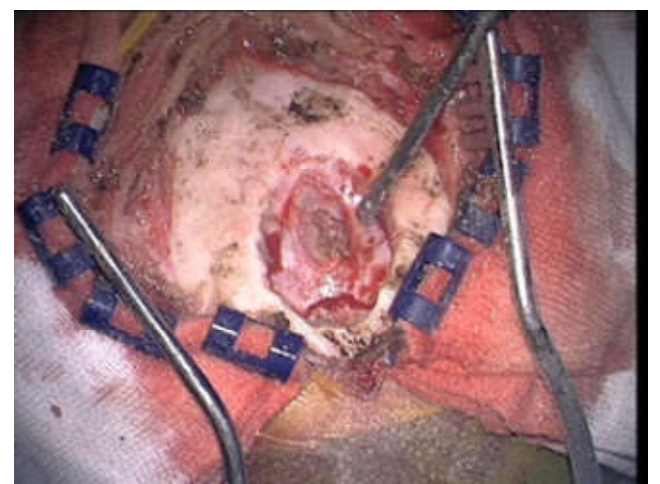


**Fig. 3.** Skin fistula

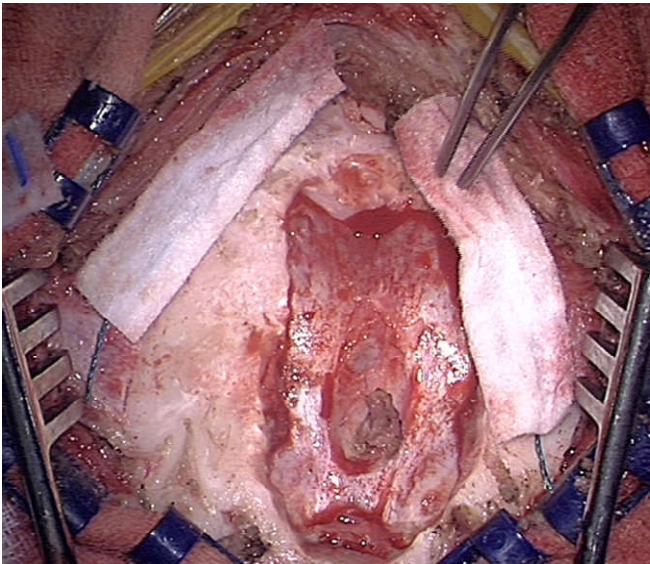
The cerebellar abscess was evacuated, followed by excision of the entire capsule (Fig.4, 5). Total removal of a 3 cm whitish, midline, encapsulated with hair cystic mass was carried out. The cyst was adherent to the dura and to the torcular venous sinus (Fig. 6, 7).



**Fig. 4.** Intraoperative image showing epicranial fistula identification

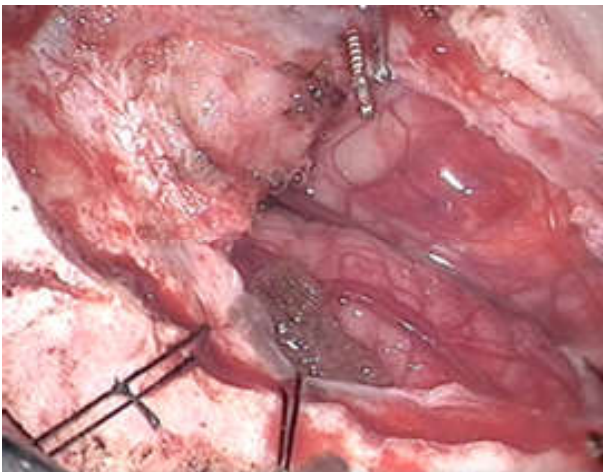


**Fig. 5.** Intraoperative image showing epicranial fistula isolation

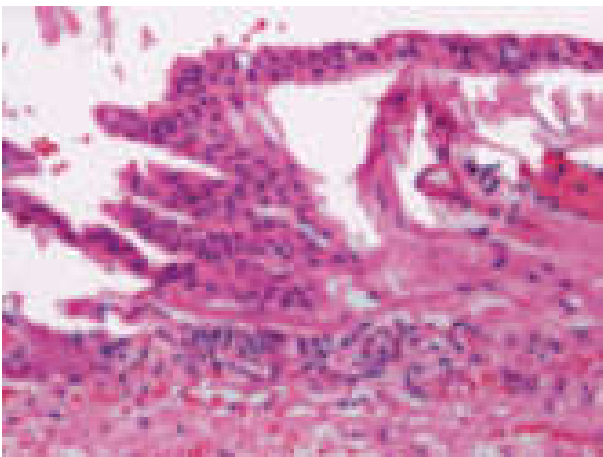


**Fig. 6. Intraoperative image showing dural communication**

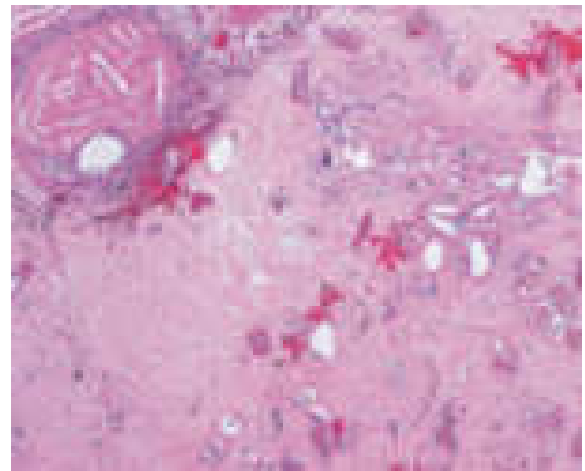
Bacterial investigation revealed *Staphylococcus aureus*. Histological examination confirmed the diagnosis of dermoid tumor (Fig. 8, 9, 10, 11). The patient's general physical condition and neurological symptoms improved rapidly. After 15 days, she was discharged without any deficit. After a 36-month follow-up, there is no evidence of recurrence (Fig. 12).



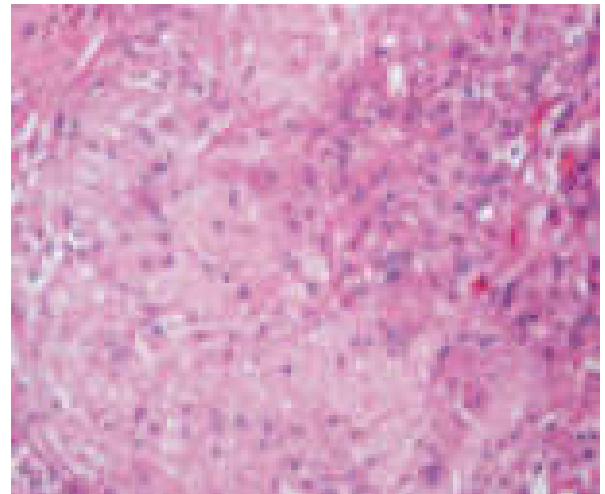
**Fig. 7. Complete excision of the fistula**



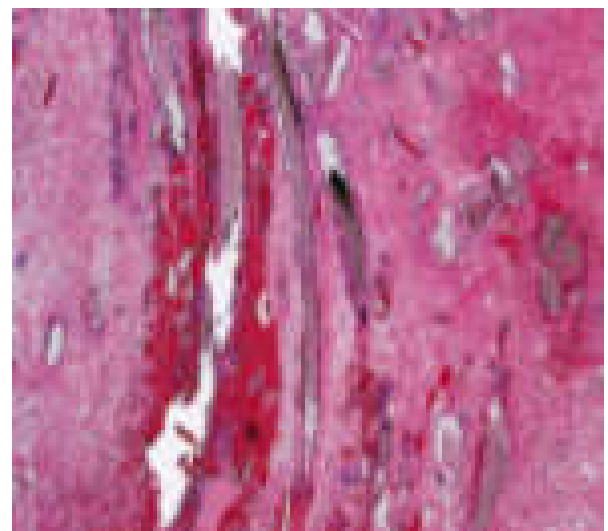
**Fig. 8.**



**Fig. 9.**



**Fig. 10.**



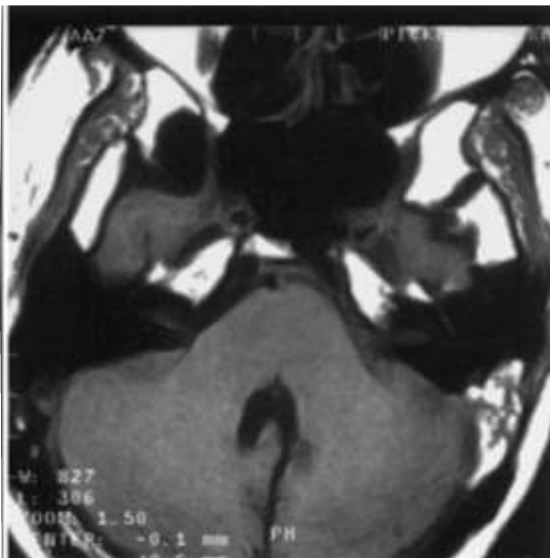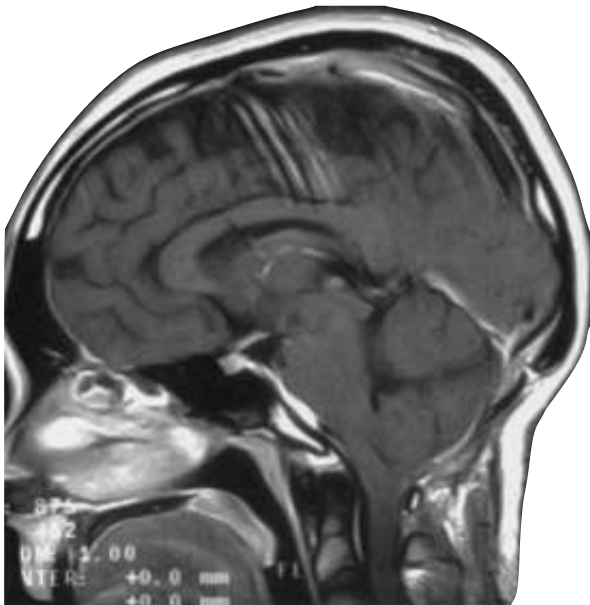
**Fig. 11.**

**Fig. 8-9-10-11. histological examination**

## DISCUSSION

### Classification

Logue and Till (1952) have classified posterior fossa dermoid cysts into four groups based on the presence of extradural/intradural cyst and degree of development of the dermal sinus: (1) extradural dermoid cyst with a complete



**Fig. 12. Post-operative head MR with no evidence of recurrence**

dermal sinus, (2) intradural dermoid cyst without a dermal sinus, (3) intradural dermoid cyst with an incomplete dermal sinus, and (4) intradural dermoid cyst with a complete dermal sinus. French (1977), reviewing the cases of intracranial congenital dermal sinuses, found that 85% of the dermal sinuses were located near the external protuberance of the occipital bone, 11% at the nasion, and 5% in the posterior parietal area. 89% of the reported cases were associated with inclusion tumors and that tumors were dermoid cysts except three classified as epidermoid cysts. Our case comes under the Logue e Till first group and was associated not only with dermoid sinus and cyst but also with a cerebellar abscess.

### Strumental diagnosis

Dermoid cyst, at plain skull films often it present as an oval or circular defect, small or moderate in size (less than 20 mm in diameter) with a sclerotic margin, localized along the midline, just below the inion. If it is very small, it could not be visible on plain radiographs (Davidson, 1985; Smith, 1991). Some cases are associated with vertebral deformities such as hemivertebrae, spina bifida, or Klippel-Feil deformity (Roberts, 1958; Smith, 1959; Vinchon, 1995).

Brain CT scan detects thinning or interruption of the skull tables, and presence of calcification and can reveal the homogeneous hypodensity of the cyst content; after contrast administration, if the cyst is infected, an homogeneous periferical enhancement is present. Smith *et al.* (1985) have analyzed the brain MR in seven patients with ruptured dermoid cyst. In all reported cases there was a thick, viscous, greenish-brown fluid composed of lipid metabolites and liquid cholesterol from decomposed epithelial cell; these liquid product can explain an hyperintensity on T1 sequences, with lower signal on T2 (Matson, 1969; Davidson *et al.*, 1985; Smith *et al.*, 1991).

If the dermoid cyst is infected, the density values in the central area of the lesion are higher (Erdem *et al.*, 1994; Goffin *et al.*, 1993; Lunardi *et al.*, 2002; Martinez-Lage *et al.*, 1997). Fistulography through the dermal sinus should be avoided because of the potential risk of infection and iatrogenic distention, or rupture of the cyst (Goffin *et al.*, 1993). Cerebral angiography usually shows an avascular mass (Yasargil, 1989). In our case, the head CT showed the occipital skull interruption while the MRI demonstrated the typically oblique stalk or tract that links cyst and skin and after contrast administration a periferical homogeneous ovalar enhancement was present.

### Surgical treatment

Treatment of dermoid cysts consists in micro-surgical excision and antibiotic therapy (Guidetti, 1977; Hayek *et al.*, 2001; Lunardi *et al.*, 2002; Yasargil *et al.*, 1989). A total removal of the cyst is not always possible because of firm adhesion of its (Akhaddar, 1999). Indeed a connection among the dermal sinus, dermoid cyst, and venous confluence can be present (Schijman *et al.*, 1986; Wiemer, 1988). The choice of treatment depends on the clinical status of the patient, as well as n the size, location, and the presence or absence of the capsule. When hydrocephalus is present, external drainage promotes more favorable operative conditions and perhaps decreases the likelihood of permanent CSF diversion (Hayek *et al.*, 2001; Smith, 1959; Tekkok *et al.*, 1996). For the presence of a communication between external and intracranial space due to the dermal sinus, we did an emergency intervention and a local and systemic antibiotic therapy was initiated.

### Conclusion

Posterior fossa dermoid cyst should be suspected in children with an occipital skin lesion in presence of a dermal sinus. Neuroradiological investigations are necessary to define the dermoid cyst site and any associated disorders. An early neurosurgical treatment should be performed to prevent the development of severe infections, such as bacterial meningitis and cerebellar abscess of the cyst (Erdem, 1994; Groen *et al.*, 1995; Hashmi, 1998; Hayek *et al.*, 2001; Logue *et al.*, 1952; Tekkok *et al.*, 1996). No recurrence of a posterior fossa dermoid cyst after surgery has been reported in the literature (Erdem *et al.*, 1994; Groen *et al.*, 1995; Hashmi *et al.*, 1998; Logue, 1952; Tekkok *et al.*, 1996). Only recently, Hashmi and Jones (Hashmi, 1998) have reported recurrence of a cerebellar abscess 20 years after excision of a dermoid cyst wit bilateral abscesses. Mortality and morbidity increase if meningitis develops. Better results were obtained in cases of early diagnosis and surgical treatment (Tekkok *et al.*, 1996).

## REFERENCES

- Akhaddar A, El Hassani R, Hommadi A, Chakir N, Jiddane M, Boukhrissi N. 1999. Dermoid cyst of the conus medullaris revealed by chronic urinary retention: imaging study. *J Neuroradiol*, 26:132–6.
- Akhaddar *et al* Rubin G, Scienza R, Pascualin A, Rosa L, DaPian R. Craniocerebral epidermoids and dermoids. *Acta Neurochir (Wien)* 1989;97:1–16.
- Altman RS. 1963. Dermoid tumor of the posterior fossa associated with congenital dermal sinus. *J Pediatr.*, 62:565–70.
- Cysts of the posterior fossa in children. 1990. Reported of nine cases and review of the literature. *Surg Neurol.*, 34:39 – 42.
- Davidson HD, Ouchi T, Steiner RE. 1985. NMR imaging of congenita Intracranial germinal layer neoplasms. *Neuroradiology*, 27: 301–303
- Erdem G, Topcu M, Topaloglu, Bertan V, Arikan U. 1994. Dermoid tumor with persistently low CSF glucose and unusual CT and MRI findings. *Pediatr Neurol*;10: 75–7.
- French BN. 1990. Midline fusion defects and defects of formation. In: Youmans JR, ed. *Neurological Surgery*. Philadelphia: *Saunders*, 1164 –1169
- Goffin J, Plets C, Calenbergh F, *et al*. 1993. Posterior fossa dermoid cyst associated with dermal fistula: report of 2 cases and review of the literature. *Child's Nerv Syst.*, 9:179 – 81.
- Groen RJ, Van Ouwerkerk WJ. 1995. Cerebellar dermoid tumor and occipital meningocele in a monozygotic twin: clues to the embryogenesis of craniospinal dys-raphism. *Child's Nerv Syst.*, 11:414–7.
- Guidetti B, Gagliardi FM. 1977. Epidermoid and dermoid cysts: clinical evaluation and late surgical results. *J Neurosurg.*, 47:12–8.
- Guidetti V, Gagliardi FM. 1977. Epidermoid and dermoid cysts: clinical evaluation and late surgical results. *J Neurosurg.*, 47:12–18 4.
- Hashmi S, Jones R. 1998. Delayed recurrence of cerebellar abscess 20 years after excision of dermoid cyst and sinus. *Br J Neurosurg.*, 12:358–60.
- Hayek G, Mercier Ph, Fournier HD, Menei Ph, Pouplard D, Guy G. 2001. Sinus dermique avec kyste dermoide de la fosse ce' re'brale poste'rieure re' ve'le' par un abce's. A propos de deux cas pe'diatriques avec revue de la litte' rature. *Neurochir*, 47:123–7.
- Higashi S, Takinami K, Yamashita J. 1995. Occipital dermal sinus associated with dermoid cyst in the fourth ven- tricle. *American Journal of Neuroradiology*, 16:945– 8.
- Hsu ST, Yu-Yun Lee J, Chao SC, Hsieh MY, Huang CC. 1998. Congenital occipital dermal sinus with intracranial dermoid cyst complicated by recurrent *Escherichia coli* meningitis. *Br J Dermatol.*, 139:922–4.
- Lepindre J, Labrune M. 1970. Fistules dermiques conge' niales communiquant avec le syste` me nerveux central. *Neurochir*, 16:335–48.
- Logue V, Till K. 1952. Posterior fossa dermoid cysts with special reference to intracranial infection. *J Neurol Neurosurg Psychiatry.*, 15:1–12.
- Lunardi P, Missori P, Galiardi FM, Fortuna A. 2002. Dermoid 270 *Surg Neurol.*, 2002;58:266 –70
- Martens F, Ectors P, Noel P, Hanquinet S, Faverly D. 1987. Unusual cause of cerebellar abscess: occipital dermal sinus and dermoid cyst. *Neuropediatrics*, 18: 107–9.
- Martin J, Davis L. 1943. Intracranial dermoid and epidermoid tumors. *Arch Neurol Psychiatry (Chicago)*; 49:56 –70.
- Martinez-Lage JF, Capel A, Costa TR, Perez-Espejo MA. 1992. The child with a mass over its head: diagnostic and surgical strategies. *Childs Nerv Syst.*, 8:247– 52.
- Martinez-Lage JF, Ramos J, Puche A, Poza M. 1997. Extra- dural dermoid tumours of the posterior fossa. *Arch Dis Child.*, 77:427–30.
- Matson D. 1969. *Neurosurgery of Infancy and Childhood*. 2nd ed. Springfield, Ill: Thomas, 96–112
- Matson DD, Ingraham FD. 1951. Intracranial complications of congenital dermal sinuses. *Pediatrics*, 8:463– 74.
- Mount LA. 1949. Congenital dermal sinuses as a cause of meningitis, intraspinal abscess and intracranial abscess, 139:1263– 8.
- Pediatr Neurosurg*. 2007. 43(4):323-6. Posterior fossa dermoid cysts causing cerebellar abscesses.
- Roberts AP. 1958. A case of intracranial dermoid cyst asso- ciated with the Klippel-Feil deformity and recurrent meningitis. *Arch Dis Child.*, 33: 222–5.
- Schijman E, Monges J, Craganz R. 1986. Congenital dermal sinuses, dermoid and epidermoid cysts of the poste- rior fossa. *Child's Nerv Syst.*, 2:83–6.
- Smith AS, Benson JE, Blaser SI, Mizushima A, Tarr RW, Bellon, EM. 1991. Diagnosis of ruptured intracranial dermoid cyst: value of MRover CT. *AJNR Am J Neuroradiol*, 12:175–180
- Smith GF, Altman DH. 1959. Occipital dermal sinus. *Am J Dis Child.*, 98:713–9.
- Starinsky R, Wald U, Michowitz SD, Lahat E, Schiffer J. 1988. Dermoids of the posterior fossa. Case reports and review. *Clin Pediatr.*, 27:579–82.
- Tekkok IH, Baesa SS, Higgins MJ, Ventureyra E. 1996. Abscedation of posterior fossa dermoid cysts. *Child's Nerv Syst.*, 12:318–22.
- Tytus JS, Pennybacker J. 1956. Pearly tumors in relation to the central nervous system. *J Neurol Neurosurg Psy- chiatry*, 19:241–59.
- Vinchon M, Lejeune JP, Krivosic I. 1995. Les kystes dermoïdes et e'pidermoïdes cranio-ence' phaliques: clas- sification et pathoge' nie. *Neurochir*, 41:29–37.
- Wiemer DR. 1988. An occipital dermoid tumor and sinus. *Ann Plast Surg.*, 21:465–7.
- Wright RL. 1971. Congenital dermal sinuses. *Prog Neurol Surg.*, 4: 175–191
- Yasargil MG, Abernathey CD, Sarioglu AC. 1989. Microneurosurgical treatment of intracranial dermoid and epi- dermoid tumors. *Neurosurgery*, 24:561–7.

\*\*\*\*\*