



## RESEARCH ARTICLE

### EFFECT OF TREATMENT OF HEREDITARY GINGIVAL FIBROMATOSIS ON THE ORAL HEALTH RELATED QUALITY OF LIFE: A CASE REPORT

Priya Malhotra\* and Vipin Bharti

Principal and Head, Department of Periodontology, Government Dental College and Hospital, Patiala, Punjab, India

#### ARTICLE INFO

##### Article History:

Received 19<sup>th</sup> November, 2017  
Received in revised form  
15<sup>th</sup> December, 2017  
Accepted 25<sup>th</sup> January, 2018  
Published online 28<sup>th</sup> February, 2018

##### Key words:

Gingival enlargement,  
Gingivectomy, Hereditary gingival  
fibromatosis, Quality of life.

**Copyright** © 2018, Priya Malhotra and Vipin Bharti. This is an open access article distributed under the Creative Commons Attribution License, which permits unrestricted use, distribution, and reproduction in any medium, provided the original work is properly cited.

**Citation:** Priya Malhotra and Vipin Bharti. 2018. "Effect of treatment of hereditary gingival fibromatosis on the oral health related quality of life: A case report", *International Journal of Current Research*, 10, (02), 66054-66057.

#### ABSTRACT

Hereditary gingival fibromatosis is a rare benign oral condition which is characterized by slow and progressive enlargement of the maxillary and mandibular arches covering the teeth to various extents. The condition may occur as an isolated disorder or as a part of a syndrome. This condition negatively affects the quality of life. This paper presents a case of 18 year old male with generalized hereditary gingival fibromatosis involving both the dentitions and covering the teeth upto incisal/occlusal third. The excess gingival tissue in this case was removed by sextant wise conventional external bevel gingivectomy under local anaesthesia. The post-operative result was uneventful and the patient's appearance improved considerably, also improving his mastication, oral hygiene practice and oral health related quality of life as assessed by the reduction in Oral Health Impact Profile (OHIP)-14 scores. After treatment regular recall visits are necessary to evaluate the stability of the treatment.

## INTRODUCTION

Gingival fibromatosis is a heterogeneous group of disorders which is characterized by the progressive enlargement of the gingiva caused by an increase in connective tissue elements (Takagi *et al.*, 1991). It is caused by several factors such as inflammation, drugs, leukemia, inheritance etc. The inheritance condition in which the gingival tissue spontaneously and progressively enlarges is known as hereditary gingival fibromatosis (HGF). It is a rare condition of the gingival tissue and has an incidence of 1:350000 (Varma and Nayak, 2009; Eley *et al.*, 2010). Both autosomal dominant and autosomal recessive forms have been reported (Jorgenson and Cocker, 1974). It is also known as elephantiasis gingivae, diffuse fibroma, familial elephantiasis, idiopathic fibromatosis, hereditary gingival fibromatosis, congenital familial fibromatosis (Varma and Nayak, 2009). It usually begins at the time of eruption of permanent dentition but may also develop with the eruption of primary dentition. The gingival enlargement may occur alone or in combination of other symptoms as a part of a syndrome. Examples are Zimmerman Laband syndrome (Laband *et al.*, 1964), Jones syndrome, Klippel-Trenaunay syndrome, Ramon syndrome, Rutherford syndrome, Cross syndrome, Cowden syndrome, Murray Puretic drescher etc. (Hakkinen and Csizsar, 2007).

The HGF clinically appears as a generalized nodular hyperplastic gingiva which is firm to bony hard in consistency. Usually the gingiva is pale pink to red and inflamed and has characteristic smooth to pebbled surface with exaggerated stippling and little tendency to bleed. This enlargement is usually painless and may project upto the mucogingival junction but rarely affects the alveolar mucosa or alveolar bone (Bozzo *et al.*, 1994). The gingival hyperplasia may be generalized (symmetric) or localized (nodular). Localized involvement mainly affects the maxillary tuberosities and lingual surfaces of lower molars and is typically characterized by the presence of multiple large masses (Varma and Nayak, 2009; Bansal *et al.*, 2011). The generalized form, the most common type, results in uniform enlargement of gingiva that covers the alveolar ridges and extends over the teeth. Excessive gingival growth results in pseudo pockets formation and periodontal problems due to difficulty in daily oral hygiene. The HGF may also result in diastema, delayed tooth eruption and facial disfigurement due to lip protrusion. Severe hyperplasia of gingiva can result in restricted movements of tongue, speech impediments, difficulty with mastication and can prevent normal closure of lips (Shafer, 1983). Thus, gingival fibromatosis severely influence the oral health related quality of life due to which the patients desire to seek the treatment. This report presents the clinical features, management and effect of treatment on oral health related quality of life of an 18 year old male patient with a severe variety of non syndromic Hereditary gingival fibromatosis.

\*Corresponding author: Priya Malhotra

Principal and Head, Department of Periodontology, Government Dental College and Hospital, Patiala, Punjab, India

**Case report:** An 18 year old male reported to the Department of Periodontology, Government Dental College and Hospital, Patiala with the complaint of gingival swelling causing difficulty in his speech, mastication and aesthetics. The patient reported that the gingival enlargement started with the eruption of permanent dentition but progressed slowly to cover the entire dentition. The enlargement was painless. His family history was significant because his mother and maternal uncle also suffered from gingival fibromatosis. His maternal uncle was treated in the same department 3 years ago (Sonia, Bharti *et al.*, 2016). His father and siblings did not reveal any evidence of gingival overgrowth. The patient's medical history did not reveal any history of drug being taken or hormonal changes and exhibited no signs of hypertrichosis, any deafness or mental retardation that could be associated with gingival hyperplasia.

**Examination:** The extra oral examination revealed a convex profile with partially incompetent lips (Figure 1). The intra oral examination revealed generalized gingival overgrowth including both the maxillary and mandibular arches extending upto the vestibular areas. The enlarged tissue was pink in colour with leathery consistency, hard on palpation and covered 3/4<sup>th</sup> of the crowns of the entire dentition (Figure 2). A scanty amount of plaque and food debris was present with no significant inflammation. No bleeding on probing was present.

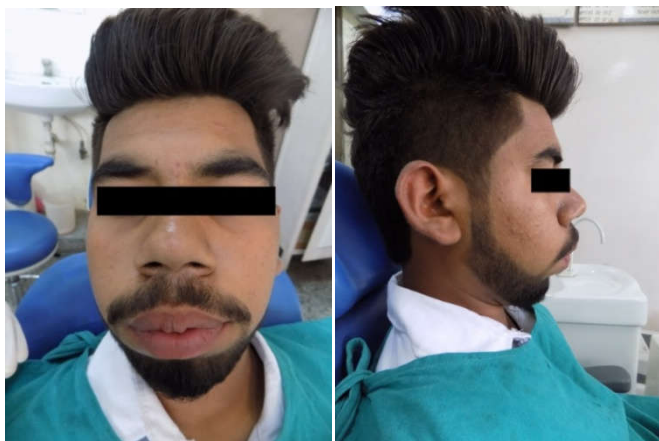

Figure 1: Extra oral picture

**Investigations:** Routine blood investigations were done and values were found within normal range. Panoramic radiograph was done which revealed normal bone height and tooth positioning (Figure 4).

**Treatment:** After explaining to the patient about the potential risks and benefits, an informed consent was obtained. Keeping in mind the desire of the patient for better esthetics, surgical treatment was planned. The enlarged tissue was removed by the external bevel gingivectomy under local anesthesia sextant wise and a part of gingival tissue was sent for histopathological examination. Periodontal dressing was applied and post operative instructions were given. The histological evaluation revealed moderately dense to highly dense collagenous connective tissue with dense collagen bundles arranged in haphazard manner. The connective tissue was relatively avascular with various degrees of focal areas of chronic inflammatory cells. The overlying epithelium exhibited hyperkeratosis with enlarged rete ridges (Figure 5). The histopathological picture was suggestive of gingival fibromatosis. Post-surgical healing was uneventful (Figure 3). The periodontal dressing was removed after one week and the surgical area was profusely irrigated with betadine and normal saline. The patient was recalled after 1, 3 and 6 months intervals for post-surgical evaluation.

**Oral Health Related Quality of Life:** Oral health related quality of life assessment was done by using Oral Health Impact Profile (OHIP)-14 (Slade, 1997) questionnaire which is composed of 14 questions divided into seven subscales. The scores were taken before and after 1 month of treatment. The total OHIP-14 greatly reduced from 41 to 5. There was also marked reduction in the scores of the following subscales after the treatment: functional limitation (7 to 2), physical pain (5 to 1), psychological discomfort (7 to 0), physical disability (6 to 0), psychological disability (6 to 1), social disability (5 to 0) and social handicap (5 to 1).

## DISCUSSION

This article reports a case of hereditary gingival fibromatosis of severe variety. The diagnosis was made on the basis of clinical

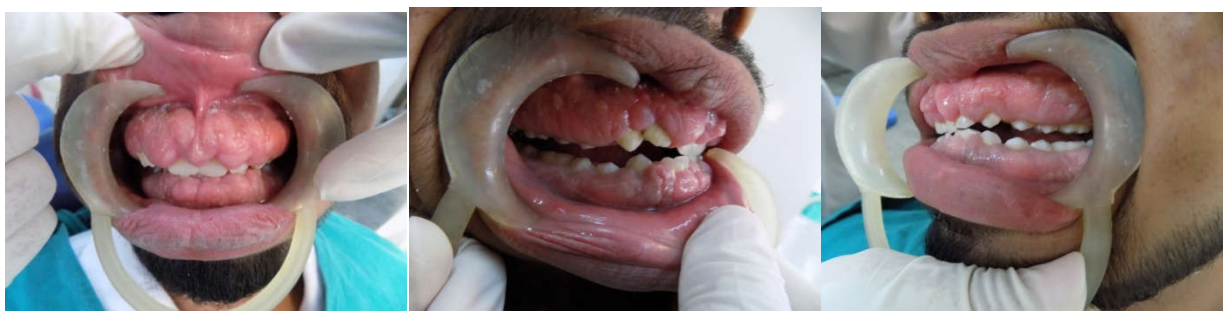


Figure 2: Pre-operative clinical picture

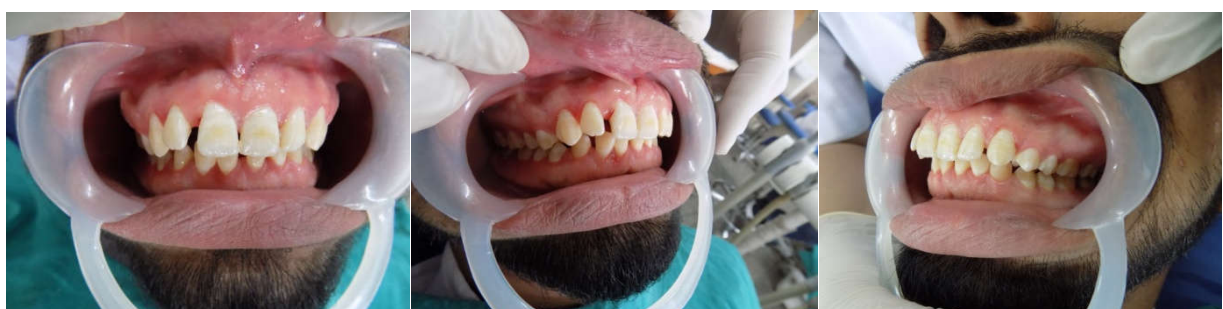


Figure 3: Post-operative clinical picture after 3 months

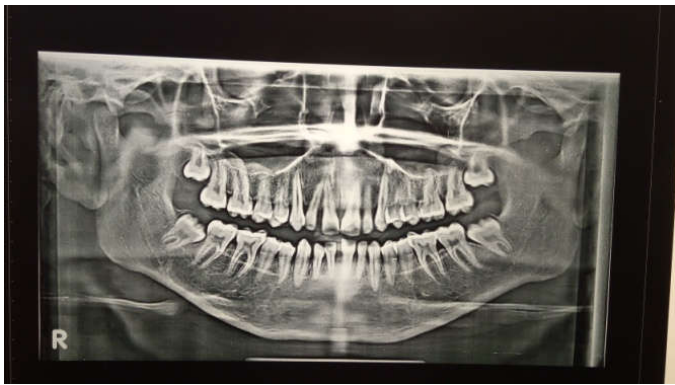

Figure 4: opg x-ray

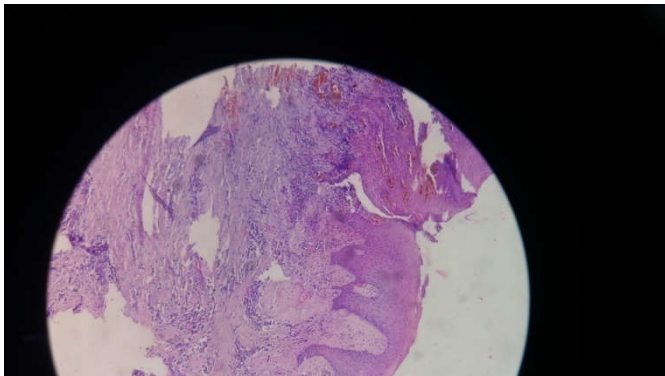


Figure 5: Histopathological picture

presentation, family history and histopathological features. HGF can be inherited as an autosomal dominant or autosomal recessive condition (Varma and Nayak, 2009; Shafer, 1983). Bozzo et al showed that in a four generation pedigree with 50 of 105 family members were at risk of developing gingival fibromatosis (Bozzo *et al.*, 1994). Recently two gene loci on the short arm of chromosome 2 responsible for gingival fibromatosis were identified in a Brazilian family. One locus was located in 2p21-2p22 (Shashi *et al.*, 1999) and the other locus was located more proximally in the region of 2p13-p16 (Blackwell *et al.*, 1989). Xiao *et al.* (2001) identified a new locus (GINGF2) on chromosome 5q13-q22. Also, a mutation in the Son of Sevenless 1 (SOS-1) gene has been suggested as a possible cause of non-syndromic gingival fibromatosis. However, no definite linkage has proven to be established (Hart *et al.*, 2000).

There is contradictory evidence regarding the cellular and molecular mechanisms of gingival fibromatosis. Some authors have reported that gingival fibroblasts from the hereditary fibromatosis have the characteristics of permanently activated fibroblasts which grow faster and produce more collagen than normal gingival fibroblasts (Coletta *et al.*, 1999). It occurs partly under the autocrine control of TGF-beta reducing the proteolytic activities of HGF fibroblasts reducing the proteolytic activities of HGF fibroblasts, which favour the accumulation of extracellular matrix. Tipton *et al.* (2004) have investigated the role of c-myc proto-oncogene in human gingival fibroblast cell line and found that increased proliferation was related to elevated c-myc expression (Tipton, 2004). The gingival enlargement causes difficulty in various functions like mastication, speech, aesthetics and it negatively affects the quality of life. In the present case OHIP-14 was used to assess the quality of life which is a well validated measure and is multidimensional construct that reflects comfort when

eating, sleeping and engaging in social interaction, self esteem and satisfaction with oral health (Slade, 1997). The treatment of gingival fibromatosis varies according to the severity of the condition. When the enlargement is minimum, oral prophylaxis and home care measures may be sufficient to maintain oral health. When the enlargement is moderate to severe, the treatment comprises of surgical excision of the enlarged tissue often in a series of gingivectomies alongwith an effective program of oral hygiene. Few studies have documented the use of carbon dioxide laser (Miller and Truhe, 1994), however most widely used method is the conventional external bevel gingivectomy with gingivoplasty when there are pseudo pockets and no attachment loss is present (Shafer, 1983; Bapista, 2002). If fibromatosis is accompanied with attachment loss and osseous defects, then a periodontal flap procedure may be preferred (Bansal *et al.*, 2011). The treatment should always be performed after the eruption of permanent teeth to prevent recurrence. Recurrence of the fibromatosis is a common feature over varying periods. In our case, sextant wise gingivectomies were performed under local anaesthesia which greatly improved the quality of life of the patient as assessed by the reduction in OHIP-14 scores. The case was followed for 6 months and there was no recurrence seen.

## Conclusion

Hereditary gingival fibromatosis is a rare disorder which is characterized by varying degrees of gingival overgrowth. Patients with gingival hyperplasia should be examined carefully. Aesthetic and functional impairment affects the oral health related quality of life of the patients and often demands surgical intervention. After treatment, regular recalls of the patient are necessary in order to evaluate oral hygiene and stability of the periodontal treatment.

## REFERENCES

- Bansal, A., Narang, S., Sowmya, K. and Sehgal, N. 2011. Treatment and two year follow up of a patient with hereditary gingival fibromatosis. *J Indian Soc Periodontol.*, 2011;15:406-409.
- Bapista, IP. 2002. Hereditary gingival fibromatosis: A case report. *J Clin Periodontol.*, 9:871-4.
- Blackwell, CC., Weir, DM., James, VS. and Cartwright, KA. Stuart, JM. and Jones, DM. 1989. The Stonehouse study: Secretor status and carriage of Neisseria species. *Epidemiol Infect.*, 102:1-10.
- Bozzo L, de Almedia OP, Scully C, Alred MJ. Hereditary gingival fibromatosis. Report of an extensive four generation pedigree. *Oral Surg Oral Med Oral Pathol.* 1994;78:452-454.
- Coletta, RD., Almeida, OP., Reynolds, MA. and Sauk, JJ. Alteration in expression of MMP-1 and MMP-2 but not TIMP-1 and TIMP-2 in hereditary gingival fibromatosis is mediated by TGF-beta 1 autocrine stimulation. *J Periodontol Res.*, 34:457-63.
- Eley BM, Soory M, Manson JD. Periodontics. 6<sup>th</sup> ed. China : Churchill Livingstone: Elsevier; 2010. P. 113-114.
- Hakkinen, L. and Csiszar, A. 2007. Hereditary gingival fibromatosis: characteristics and novel putative pathogenic mechanisms. *J Dent Res.*, 86(1):25-34.
- Hart, TC., Pallos, D., Bozzo, L., Almeida, OP., Marazita, ML. and O'Connell, JR. Evidence of genetic heterogeneity for hereditary gingival fibromatosis. *J Dent Res.*, 2000;79:1758-1764.

- Jorgenson, R.J. and Cocker, M.E. Variation in the inheritance and expression of gingival fibromatosis. *J Periodontol.*, 45(7):472-477.
- Laband, P., Habib, G. and Humphrey, G. 1964. Hereditary gingival fibromatosis: Report of an affected family with affected splenomegaly and skeletal and soft tissue abnormalities. *Oral Surg Oral Med Oral Pathol.*, 17:339-351.
- Miller, M. and Truhe, T. 1994. Lasers in dentistry: An overview. *J Am Dent Assoc.*, 124:32-35.
- Shafer, WG. 1983. A Textbook of Oral Pathology. 4<sup>th</sup> ed. Philadelphia: W. B. Saunders.
- Shashi, V., Pallos, D., Pettanati, MJ. Cortelli, JR. Fryns, JP. and Von Kap-Herr, C. Genetic heterogeneity of gingival fibromatosis on chromosome 2p. *J Med Genet.*, 36:683-686.
- Slade, GD. 1997. Derivation and validation of a short-form oral health impact profile. *Community Dent Oral Epidemiol.*, 25:284-90
- Sonia, Bharti V., Singla, M. and Sharma, H. 2016. An unusual presentation of hereditary gingival fibromatosis with maxillary buccal alveolar bone exostosis: A Case Report. *Int J Oral Health Med Res.*, 2(5):119-121.
- Takagi, M., Yamamoto, H., Mega, H., Hsieh, KJ., Shioda, S. and Enomoto, S. 1991. Heterogeneity in the gingival fibromatosis. *Cancer*, 68:2202-2212.
- Tipton, DA., Howell, KJ. and Dobbous, MK.1997. Increase proliferation, collagen and fibronectin production by hereditary gingival fibromatosis fibroblast. *J Periodontol.*, 68:524-530.
- Tipton, DA., Woodard, ES., Baber, MA. and Dabbous, MK. 2004. Role of c-myc proto-oncogene in the proliferation of hereditary gingival fibromatosis fibroblast. *J Periodontol.*, 75:360-369.
- Varma, BR. and Nayak, RP. 2009. Clinical Periodontology. 2<sup>nd</sup> ed. New Delhi: Arya (Medi) Publishing House, p 177.
- Xiao, S., Bu, L., Zhu, L., Zheng, G., Yang, M. and Qian, M. A new locus for hereditary gingival fibromatosis (GINGF2) maps to 5q13-q22. *Genomics*, 74:180-185.

\*\*\*\*\*