



ISSN: 0975-833X

Available online at <http://www.journalcra.com>

International Journal of Current Research
Vol. 9, Issue, 12, pp.63453-63455, December, 2017

INTERNATIONAL JOURNAL
OF CURRENT RESEARCH

CASE STUDY

A CONSERVATIVE APPROACH TO PEDIATRIC MANDIBULAR DENTOALVEOLAR FRACTURE AND ITS MANAGEMENT: A CASE REPORT

*¹Dr. Prashanth Sadashiva Murthy, ²Dr. Naseemoun Shaik, ¹Dr. Seema Deshmukh and ³Dr. Srilatha K Thotappa

¹Reader, Department of Pedodontics & Preventive Dentistry, JSS Dental College & Hospital, JSS University

²PG Student, Department of Pedodontics & Preventive Dentistry, JSS Dental College & Hospital, JSS University

³Professor & Head of the Department, Department of Pedodontics & Preventive Dentistry, JSS Dental College & Hospital, JSS University

ARTICLE INFO

Article History:

Received 14th September, 2017

Received in revised form

03rd October, 2017

Accepted 17th November, 2017

Published online 31st December, 2017

Key words:

Mandibular Dento alveolar fracture,
Child management,
Semi rigid occlusal splint.

ABSTRACT

Mandibular fractures in children are rare and their treatment remains controversial. Most of the fractures are greenstick type, so conservative approach is preferred as the fracture heals rapidly as the child grows normally. Treatment of mandibular fracture differ from that of adults due to concerns regarding development of dentition and mandibular growth. This article reports a case of Mandibular Dentoalveolar fracture in a 10 years boy and its conservative management.

Copyright © 2017, Dr. Prashanth Sadashiva Murthy et al. This is an open access article distributed under the Creative Commons Attribution License, which permits unrestricted use, distribution, and reproduction in any medium, provided the original work is properly cited.

Citation: Dr. Prashanth Sadashiva Murthy, Dr. Naseemoun Shaik, Dr. Seema Deshmukh and Dr. Srilatha K Thotappa. 2017. "A conservative approach to pediatric mandibular dentoalveolar fracture and its management: A case report", *International Journal of Current Research*, 9, (12), 63453-63455.

INTRODUCTION

Traumatic dental injury (TDI) is a major public health problem today that occurs with great frequency in preschool, school-age children, and young adults consist 5% of all injuries. The prevalence of these injuries ranges between 6% and 37% (Marcenes, 1999). For the primary dentition a high incidence of dental injuries occurs related to accidents within and around the home, where in case of permanent dentition accidents occurs at home and school. Child's face has protective anatomic features, growth considerations, higher cranial to facial skeleton size, softer and more elastic bones, protective thick soft tissues, etc. Immature bone has an increased proportion of cancellous bone, which leads to an increased incidence of Greenstick fractures. This article, reports a case of dento-alveolar trauma involving mandibular anterior region in a 10 years old male patient and its management.

***Corresponding author:** Dr. Prashanth Sadashiva Murthy
Reader, Department of Pedodontics & Preventive Dentistry, JSS Dental College & Hospital, JSS University

Case report

A 10 years old male patient reported to department of Pedodontics and Preventive Dentistry with a chief complaint of pain and swelling on the lower right side of the face. History of self falls at home following which the swelling appeared. Patient complained of difficulty in mouth opening associated with pain.

On examination

On extra-oral examination a diffused swelling present on the right side of the lower jaw that measured approximately 7×7 cms extending supero-inferiorly from the corner of the mouth to submandibular and submental region, antero- posteriorly it extends from left submental region to right angle of the mandible (Fig 1). Skin over the swelling appeared taut and erythematous and abrasion was noted over symphysis region. On intra oral examination, posterior bilateral open bite was observed due to interference from displaced mandibular anterior segment. The mouth opening was restricted to one finger width (11 mm) associated with severe pain. Permanent

mandibular left central incisor was extruded with grade II mobility (Fig 1). Sublingual hematoma was present and was associated with step deformity of the occlusal cant suggestive of mandibular parasymphysis fracture. However the lower border of the mandible didn't present any step deformity indicating the probability of greenstick fracture at the parasymphysis.

Radiographic examination

The clinical finding was confirmed by Preoperative orthopantomograph and mandibular anterior occlusal radiograph (Fig 2). OPG showed vertical fracture between 31, 32 and 83, 84 extending down to the body of the mandible and horizontal fracture line extending from distal to the 31 to the mesial to 84 suggestive of dento-alveolar fracture and displacement of mandibular anterior region.

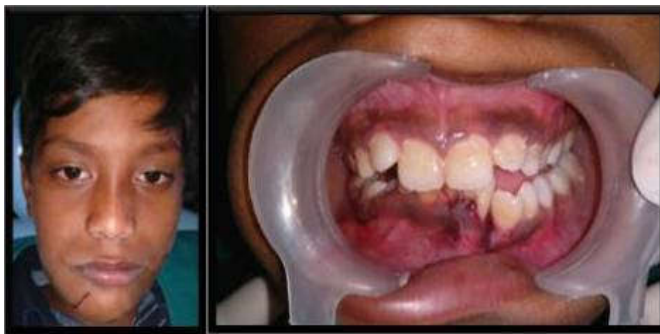

Figure 1. Pre operative photo graph showing facial asymmetry, step defect and extruded 31

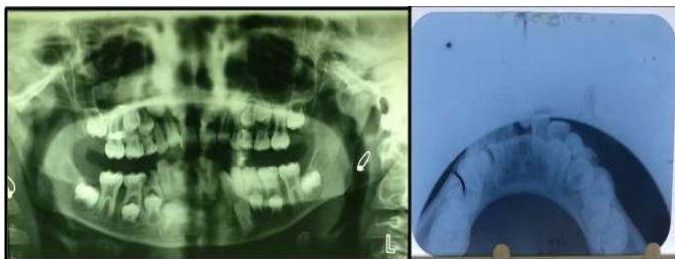


Figure 2. Pre operative OPG, Occlusal radiograph

Management

As the pediatric mandible has high osteogenic potential non-surgical conservative management was the treatment of choice. 31 was in the line of fracture and hampered the fracture fragments reduction. Hence 31 was extracted under local anesthesia. Displaced fractured fragments were then reduced with bi-digital manipulation under local anesthesia. Upper and lower alginate impressions were made. The mandibular occlusal plane was checked against the maxillary cast and split cast method was adopted to regulate the occlusion extra orally. The mandibular cast with adjusted occlusion was used to fabricate a modified semi rigid splint using Bio plast foil (code 162, with the dimensions of 1.5×125 mm. Figure 3). The semi-rigid splint was used to accurately and non-surgically reduce the fracture fragments as well provide immobilization for healing. The splint was cemented with help of luting GIC (VOCO MERON) (Figure 4). A 5-day course of antibiotic and analgesics was prescribed. Splint was maintained for duration of 3 weeks.

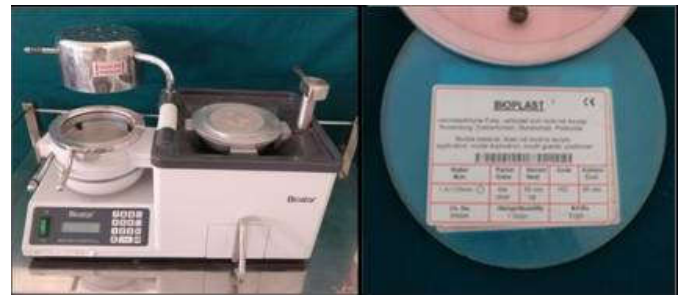

Figure 3. Bio star pressure moulding device, bioplate sheet for semirigid cap splint

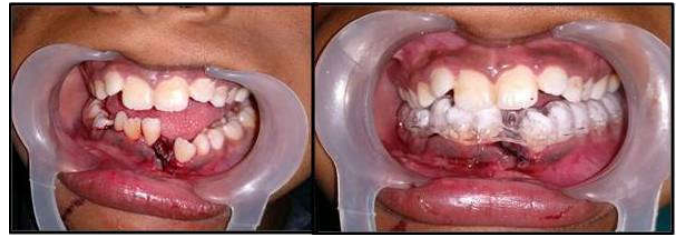

Figure 4. Extracted 31, cemented Semi rigid cap splint

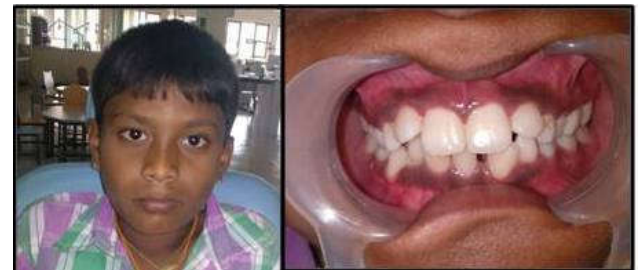

Figure 5. 6 Months follow up with the good occlusion.

DISCUSSION

Facial fractures in the children comprise less than 15% of all the facial fractures (Adekeye, 1980 and Bataineh, 1998), which may have a misfortune to cause as a complication of tooth extraction. According to Anderson and colleagues, children exhibit a bimodal distribution in trauma to oral cavity with falls the primary mechanism of injury occurring when the child is beginning to start walking and second peak occurs at a age of 8 to 10 years with 2:1 male to female ratio. The most common fractures in children requiring hospitalization and surgical intervention involves the mandible, in which the angle, condyle and the sub-condylar region account for approximately 80% of mandibular fractures followed by Symphysis and parasymphysis fractures account for 15-20% and body fractures are rare (Bataineh, 1998). In the present case a 10 years boy patient reported with the dentoalveolar fracture of mandibular anterior region. As the tooth was present at fracture line extraction of 31 under local anesthesia was done. In children, the pre-injury skeletal and dento-alveolar anatomy and function are re-established by the anatomic reduction of fracture based on the occlusion. (Cawood, 1990 and Denny, 1993).

Children have a greater osteogenic potential and faster healing rate than adults (Knban, 1990; Maniglia, 1983) and hence anatomic reduction in the children should be accomplished earlier (Heitsch, 1990 and Messinger, 1989), and the immobilization times should be shorter i.e. 2-3 weeks as compared to 4-6 weeks in adults (Gussack, 1987; OJIC,

1998). The high osteogenic potential in children allows rapid union within three weeks and non-union or fibrous union is almost never seen in pediatric patients. Before initiating treatment, mandibular range of motion, open bite or occlusal deformity and associated injuries should be evaluated. In the present case report patient had limitation of mandibular motion, treated with closed reduction followed by stabilization. Method employed for immobilization depends upon child's age and stage of dental development. The advantage of closed reduction over open reduction is its cost-effectiveness, lesser surgical trauma to the patient and reduced risk of any iatrogenic trauma to the developing teeth and other anatomical structures. Furthermore, the rate of associated complications is less in cases of closed reduction compared to open reduction. Various methods have been suggested for closed reduction using prefabricated acrylic cap splints with interdental wiring, IMF, modified orthodontic brackets, orthodontic resin and rubber elastics, modified orthodontic splint appliance. A study by Kocabay et al showed that IMF is not easily tolerated by children, as it blocks mandibular movements, causing discomfort and increased anxiety; further more it is determinental to the child's quality of life, as a liquid diet adversely affects the nutritional intake and should be used caution because it may cause TMJ ankylosis. The main disadvantage of rigid splints is trauma to the underlying gingival, force transmission to the fracture fragment is more and time taking procedure. To overcome the disadvantage, in the present study fractured fragment was stabilized using vacuum formed semi rigid occlusal splint for 3 weeks. Semi rigid poly vinyl splints have a low density and an amorphous structure, the splints are compressed or worn before the mandibular muscles are stretched or stressed beyond their physiologic limits. It is quick and easy to fabricate, saves a lot of chair side time. The appliance was fabricated with Bioplast foil (1.5×125 mm diameter) using pressure molding device (BIOSTAR No:40415). As the splint was covering completely to the tooth that gives greater anchorage on the tooth structure. This semi rigid splint acted as a shock absorber for the occlusal loads that prevent transmission of forces to fracture segment. In the present study instead of wiring, splint was cemented. While removing it doesn't exert any force to the healing fracture segment and well taken by the patient. Easy to maintain, they are less likely to cause significant occlusal changes that are sometimes noted with hard occlusal splint. A 5-day course of antibiotic and analgesics was prescribed. The child was recalled on a weekly basis to ascertain stability of the splint. After 3 weeks splint was removed and checked for occlusion, the consolidation of the fracture was confirmed clinically and radiographically. Satisfactory occlusion and healing was observed. 6 months postoperative follow-up demonstrated adequate healing of the fracture site with all associated functions intact (Figure 5).

Conclusion

Traumatic dental injuries present a challenge to clinicians worldwide. In the most of the cases, it is minimally displaced and can be managed conservatively. A severely displaced fracture may require open reduction and rigid internal fixation. But most of situations can be best managed with cap splint fixation. Consequently, proper diagnosis, treatment planning and follow up are critical to assure a favorable outcome.

REFERENCES

- Adekeye, E.O. 1980. Pediatric fractures of the facial skeleton: A survey of 85 cases from Kaduna. *Nigeria. J Oral Surg.*, 38:355-8.
- Bataineh, A.B. 1998. Etiology and incidence of Maxillofacial fractures in the north of Jordan. *Oral Surg Oral Med Oral Pathol Oral Radiol Endod.*, 86:31-5.
- Cawood, J. Stoelinga, P.J. 1990. Facial trauma. *Int J Oral Maxillofac Surg.*, 19:193
- Denny, A.D., Rosenberg, M.W., Larson, D.L. 1993. Immediate reconstruction of complex cranioorbital fractures in children. *J Craniofac Surg.*, 4 :8-20.
- Knban, L.B. 1990. Facial trauma I: Midfacial fracture. In : Kaban LB. editors: *Pediatric Oral and Maxillofacial Surgery*. W.B Saunders: Philadelphia. PA. p. 209-32
- Maniglia, A.J., Kline, S.N. 1983. Maxillofacial trauma in the pediatric age group. *Otolaryngol Clin Nonh Am.*, 16: 717-30.
- Marcenes, W., Al Beiruti, N., Tayfour, D., Issa, S. 1999. Epidemiology of traumatic injuries to the permanent incisors of 9-12-year-old schoolchildren in Damascus, Syria. *Endod Dent Traumatol.*, 15:117-23.
- Heitsch, M., Mohr, C., Schettler, D. 1990. Indications for the surgical treatment of midfacial fracture in children. *Dtsch ZahnärztlZ.*, 45: 803-5.
- Messinger, A. Radkoski, M.A. Greenwald, M.J. Pensler JM. Orbital roof fracture in the pediatric population. *Plast Reconstr Surg* 1989;84:213-8.
- Gussack GS. Luteran A, Powell RW. Rodgers K. Ramenofsky ML. Pediatric maxillofacial trauma: Unique feature in diagnosis and treatment. *Laryngoscope* 1987; 97:925-30.
- OJIC. 1998. Fractures of the facial skeleton in children: A survey of patients under the age of 11 years. *J Craniomaxillofac Surg* 26:322-5.
