



## CASE STUDY

### DECOMPRESSION FOLLOWED BY ENUCLEATION: A CONSERVATIVE TREATMENT FOR UNICYSTIC AMELOBLASTOMA

\*Vinay Kharsan, Akshay Daga, Kamini Dadsena, Usha and Naveen Lalchandani

Department of Oral and Maxillofacial Surgery, New Horizon Dental College and Research Institute, Bilaspur Chhattisgarh, 495001, India

#### ARTICLE INFO

##### Article History:

Received 25<sup>th</sup> August, 2017  
Received in revised form  
10<sup>th</sup> September, 2017  
Accepted 15<sup>th</sup> October, 2017  
Published online 30<sup>th</sup> November, 2017

##### Key words:

Unicystic ameloblastoma,  
Decompression, Mandibular molar-ramus  
region, Enucleation, 2 stage surgery.

#### ABSTRACT

Unicystic ameloblastoma is the benign, locally invasive odontogenic tumors which histologically shows typical ameloblastomatous epithelium lining part of the cyst cavity, with or without luminal and/or mural tumor growth. A case of symptomatic unicystic ameloblastoma in 16- year-old-female, who has treated by surgical decompression followed by enucleation in 2 stage surgery is presented. The present case report describes the clinical and radiological behaviors, its importance and complexity of a differential diagnosis and treatment protocol of lesions in the mandibular molar-ramus area in teenagers.

Copyright © 2017, Vinay Kharsan et al. This is an open access article distributed under the Creative Commons Attribution License, which permits unrestricted use, distribution, and reproduction in any medium, provided the original work is properly cited.

Citation: Vinay Kharsan, Akshay Daga, Kamini Dadsena, Usha and Naveen Lalchandani, 2017. "Decompression followed by enucleation: A conservative treatment for unicystic ameloblastoma", *International Journal of Current Research*, 9, (11), 61454-61457.

## INTRODUCTION

According to the 2005 World Health Organisation (WHO) histological classification of head and neck tumours, ameloblastoma can be classified into 4 subtypes: solid/multicystic (follicular or plexiform), extra osseous/ peripheral, desmoplastic and unicystic (Barnes, 2005). The Unicystic ameloblastoma, a variant of ameloblastoma first described by Robinson and Martinez in 1977, is reported to have a less aggressive biologic behaviour and lower recurrence rate than the classic solid or multicystic ameloblastoma (Ackermann, 1988). Unicystic variant can be further divided into three subtypes- Subtype 1 cysts are lined by variable epithelium with no infiltration into the cystic wall. Those in subtype 2 show intraluminal, plexiform, epithelial proliferation without infiltration, and those in subtype 3 show either a follicular or plexiform pattern of invasion by epithelium into the cystic wall (Ackermann, 1988). According to Carlson and Marx (Carlson and Marx, 2006) and Hong and associates (Hong *et al.*, 2007) treatment and prognosis of ameloblastoma is heavily influenced by its histological classification (Shatkin, 1965). The solid multicystic, and subtype 3 unicystic ameloblastomas are considered aggressive with a high potential to recur, so the approach has been to resect the lesion and repair the defect

with a microvascular graft (Shatkin, 1965). The unicystic forms are thought less likely to recur, but although a more conservative approach is recommended, in reality it is seldom adopted (Gardner, 1996). Hereby we report a case of extensive Unicystic ameloblastoma of mandible in which conservative treatment has been preferred over traditionally used aggressive treatments.

## Case Report

A 16 year-old girl was referred with a large swelling in the right cheek of about six months duration along with aesthetic impairment. Patient had complain of pain in lower right back jaw region. But she did not had a complain of dysphagia, dysphonia, dyspnoea, or any trauma to the face or neck. On examination there was a large, well-circumscribed mass in the right body and ramus of the mandible, covered with normal mucosa, which measured 12 × 6 × 5 cm. (Figure 1,2,3) There were no local skin changes, and palpation indicated a well-circumscribed, slightly tender and hard lesion. Orthopantomogram (OPG) revealed a well defined, unilocular radiolucency involving right mandibular ramus and body with a tooth content. (Figure 4) Computed tomographic (CT) scan showed a well-defined, unilocular, hypodense lesion that extended from the posterior body to the right sub condylar region. On fine needle aspiration a yellowish fluid was aspirated. A provisional diagnosis of a cystic lesion was made. Excisional biopsy was done and the lesion was diagnosed as

\*Corresponding author: Vinay Kharsan,

Department of Oral and Maxillofacial Surgery, New Horizon Dental College and Research Institute, Bilaspur Chhattisgarh, 495001, India.

Unicystic Ameloblastoma. Treatment was carried out in 2 phase. The first phase involved decompression in which under general anaesthesia, bony window was created and fragments of the mucosa and cystic lining capsule were removed and the remainder was sutured around the entire surgical window to maintain a permanent communication between the lumen and the oral cavity (Figure 5).

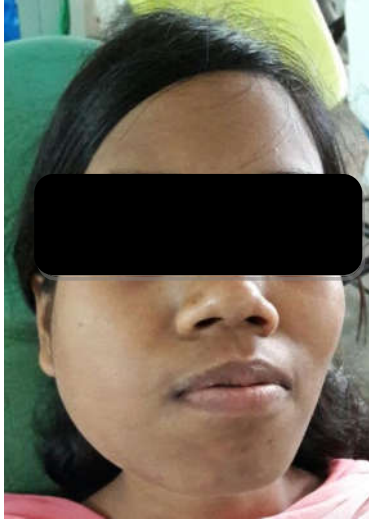

Figure 1. Preoperative extraoral frontal view

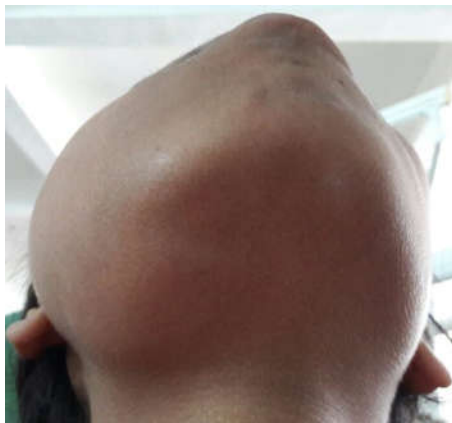

Figure 2. Preoperative extraoral wormian view

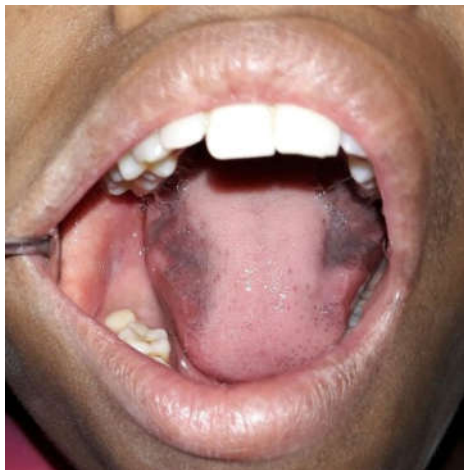

Figure 3. Preoperative intraoral view

Histopathological examination showed fibro cellular connective tissue stroma with small island of hyperchromatic cuboidal and columnar odontogenic epithelial cells. Also

showed one follicle lined peripherally by cuboidal hyperchromatic cells and centrally placed loose stellate reticulum like cells with cystic degeneration suggestive of Unicystic ameloblastoma of mural variant.

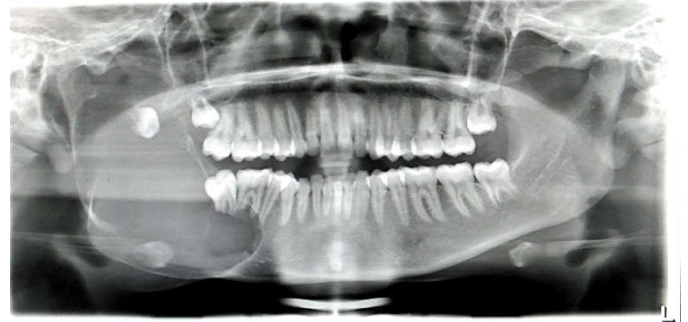

Figure 4. Preoperative OPG view

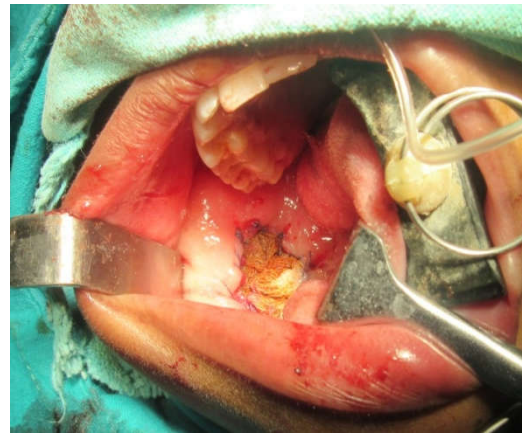


Figure 5. Intraoperative surgical decompression stage 1

Decompression was done for 10 months, during which periodic orthopantomographs were taken. (Figure 6) Ten months after the decompression, her facial asymmetry had regressed considerably and there were signs of remodelling of the mandibular bone.

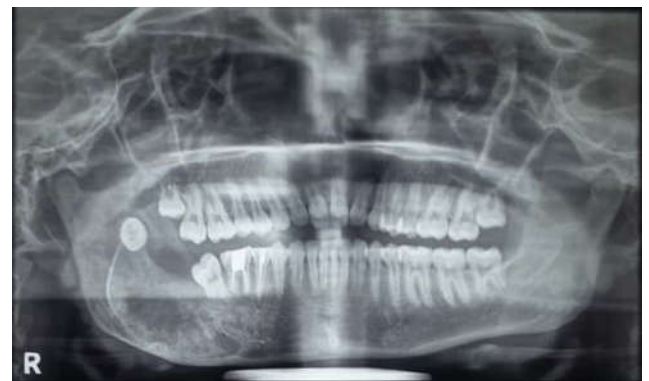

Figure 6. OPG after 10 months of surgical decompression

In 2nd phase of surgery, under general anaesthesia and through an intraoral approach the remainder of the lesion was completely enucleated and peripheral osteotectomy was done to ensure complete removal of the margins. (Figure 7 and 8) No adjuvant treatment was given. Final histopathological evaluation confirmed the diagnosis of mural unicystic ameloblastoma, and during the 13-month follow-up, we have seen no evidence of recurrence and the mandibular growth has been preserved (Figure 9).

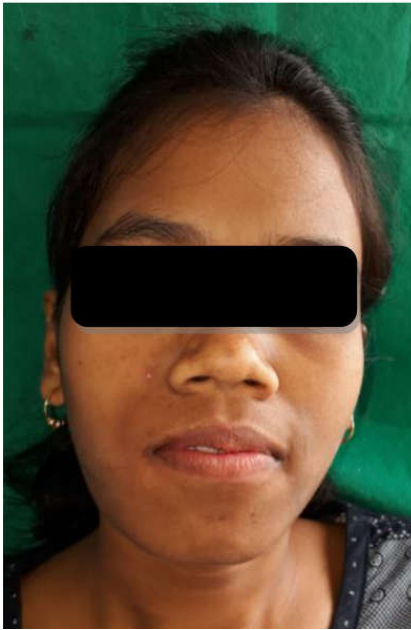

Figure 7. Post enucleation extraoral view

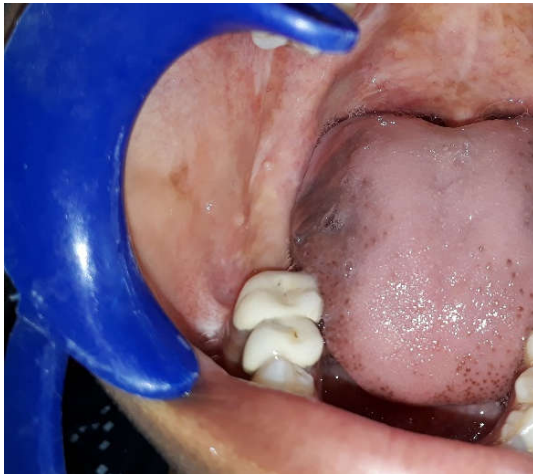

Figure 8. Post enucleation intraoral view

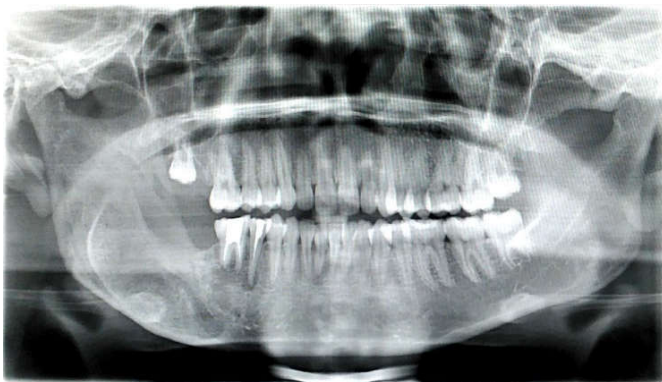


Figure 9. OPG after 3 months of enucleation

## DISCUSSION

The therapeutic management of ameloblastomas is a complex issue, as it must be as minimally destructive as possible due to the benign nature of this lesion, but must be sufficiently extensive to prevent subsequent recurrence. Two alternative approaches are therefore proposed at the present time. The conservative approach can consist of enucleation or curettage,

sometimes preceded by marsupialization (Gardner, 1980). However, several studies nevertheless recommend conservative treatment depending on the macroscopic appearance of the ameloblastoma. Gardner *et al.* recommended conservative treatment for unicystic forms, and radical treatment for solid/multicystic forms (Gardner, 1984). Similarly, Reichart *et al.* distinguished unicystic forms from the other forms of ameloblastoma and recommended conservative treatment for this group of tumours (Reichart, 1995). The histological type also appears to be an important factor determining the potential for recurrence of ameloblastomas (Hong, 2007). The histological subtype of the tumour guides contemporary management, and the treatment of solid multicystic lesions is more aggressive (Lau, 2006). Conservative management does not eliminate the risk of recurrence, whereas in most cases, resection does, but resection can have a considerable impact on young people, (Lau, 2009). The unicystic ameloblastoma can be managed by either radical or conservative approach. The radical approaches can be achieved by resection of the lesion followed by reconstruction with reconstructive plates or microvascular graft. Conservative treatment consists of enucleation, enucleation followed by application of Carnoy's solution, or marsupialisation followed by enucleation. The decompression of the internal contents by marsupialisation promotes remodelling of bone and osteogenesis. Marsupialisation can be effective, as it preserves the mandibular contour and growth (Lau, 2009). Lau and Samman reported that the recurrence rates for unicystic ameloblastomas were 3.6% after resection, 30.5% after enucleation alone, 16% after enucleation followed by application of Carnoy's solution, and 18% after marsupialisation with or without further treatment (Lau, 2006). Seintou *et al.* reported a recurrence rate of 29.4% after enucleation or excision, and several other series have shown that resection is the treatment followed by the lowest recurrence rate.

However, the recurrence rates after marsupialisation cannot be considered to be high, and the management is less invasive. The mean period to recurrence reported by some studies is five years, which suggests that all patients should be followed up in the long term (Seintou, 2014). Resection seems to be excessive for unicystic ameloblastoma, which behaves much better than the solid variant, and in young patient the conservative approach offers good aesthetic results and maintains their craniofacial development. The question that remains is whether the treatment that offers the lowest rate of recurrence is the best for young patients (Seintou, 2014).

## Conclusion

The ideal treatment for this case is resection followed by reconstruction with microvascular graft. Several treatments have been suggested, and success has been associated with recurrence rates, but the approach should not be based solely on these. In young patients resection causes important functional and aesthetic damage. So Resection seems to be excessive for unicystic ameloblastoma, which behaves much better than the solid variant. Conservative management does not eliminate the risk of recurrence, whereas in most cases, resection does, but resection can have a considerable impact on young people. Patient is kept under review, if the recurrence occurs that can be eliminated by a second enucleation, and even if resection is ultimately required, it can be postponed until later in life when the patient is settled.

**REFERENCES**

- Ackermann, G.L., Altini, M. and Shear, M. 1988. The unicystic ameloblastoma: a clinicopathological study of 57 cases. *J Oral Pathol*, 17:541–6.6
- Barnes, L., Everson, J.W., Reichart, P. and Sidransky, D. 2005. World Health Organization classification of tumours. Lyon: Pathology and Genetics of Head and Neck Tumours IARC Press., p. 287–9.
- Gardner, D.G. 1984. A pathologist's approach to the treatment of ameloblastoma. *J Oral Maxillofac Surg.*, 42:161–6
- Gardner, D.G. 1996. Some current concepts on the pathology of ameloblastoma. *Oral Surg Oral Med Oral Pathol Oral Radiol Endod.*, 82:660–9
- Gardner, D.G. and Pecak, A.M. 1980. The treatment of ameloblastoma based on pathologic and anatomic principles. *Cancer.*, 46:2514
- Hong, J., Yun, P.Y., Chung, I.H., et al. 2007. Long-term follow up on recurrence of 305 ameloblastoma cases. *Int J Oral Maxillofac Surg.*, 36:283–8.
- Lau, S.L. and Samman, N. 2006. Recurrence related to treatment modalities of unicystic ameloblastoma: a systematic review. *Int J Oral Maxillofac Surg* 35: 681e690.
- Reichart, P.A., Philipsen, H.P. and Sonner, S. 1995. Ameloblastoma: biological profile of 3677 cases. *Eur J Cancer B Oral Oncol.*, 31:86–99.
- Seintou, A., Martinelli-Klay, C.P. and Lombardi, T. 2014. Unicystic ameloblastoma in children: systematic review of clinicopathological features and treatment outcomes. *Int J Oral Maxillofac Surg.*, 43: 405-412.
- Shatkin, S. and Hoffmeister, F.S. 1965. Ameloblastoma: A rational approach to therapy. *Oral Surg Oral Med Oral Pathol.*, 20:421–35.7

\*\*\*\*\*