



## RESEARCH ARTICLE

### FAVORABLE OUTCOME FOR BOTH MOTHER AND FETUS AFTER SUCCESSFUL MANAGEMENT OF GASTRIC STRANGULATION CAUSED BY RUPTURED DIAPHRAGMATIC HERNIA IN PREGNANCY

\*<sup>1</sup>Setare Nassiri, <sup>2</sup>Mohammad Vakili, <sup>3</sup>Hamide Gholami and <sup>3</sup>Setare Akhavan

<sup>1</sup>Gynecology Department of Valiasr part of Emam Khomeini Hospital, Gynecologist Oncologist of Tehran University of Medical Sciences

<sup>2</sup>Thorax Surgery, Department of Valiasr Part of Emam Khomeini Hospital

<sup>3</sup>Gynecologist Oncologist of Tehran University of Medical Sciences, Gynecology Department of Valiasr part of Emam Khomeini Hospital

#### ARTICLE INFO

##### Article History:

Received 07<sup>th</sup> August, 2017  
Received in revised form  
23<sup>rd</sup> September, 2017  
Accepted 13<sup>th</sup> October, 2017  
Published online 30<sup>th</sup> November, 2017

##### Key words:

Diaphragmatic Hernia,  
Strangulation,  
Pregnancy.

#### ABSTRACT

Rupture of diaphragmatic hernia is a very rare life threatening situation in pregnancy. It usually is followed by abstraction and strangulation of the herniated intra-abdominal organs such as colon, stomach and small bowel. Almost 50% of cases are misdiagnosed because of the non-specific manifestation of diaphragmatic hernia. The symptoms can be varied as the spectrum, from slight abdominal pain to acute abdomen or severe respiratory distress. High suspicion should be considered when the patient's symptoms don't respond to usual supportive management. Delay in surgical intervention leads to high maternal and fetal mortality while timely diagnosis is resulted in favorable prognosis. Herein we present a pregnant woman with progressive epigastric pain and severe respiratory distress, who were undertaken thoracotomy and gastrotomy due to gastric strangulation via ruptured diaphragmatic hernia on 22<sup>nd</sup> week of gestation. Eventually both of them, mother and baby had a good prognosis. We concluded that although this condition is very rare but is very dangerous and it is mandatory to emergent surgery to avoid life threatening implications.

Copyright © 2017, Setare Nassiri et al. This is an open access article distributed under the Creative Commons Attribution License, which permits unrestricted use, distribution, and reproduction in any medium, provided the original work is properly cited.

Citation: Setare Nassiri, Mohammad Vakili, Hamide Gholami and Setare Akhavan, 2017. "Favorable outcome for both mother and fetus after successful management of gastric strangulation caused by ruptured diaphragmatic hernia in pregnancy", *International Journal of Current Research*, 9, (11), 61381-61383.

## INTRODUCTION

Diaphragmatic hernia can be congenital or acquired. In congenital cases it develops due to a defect in diaphragm competency while another type is caused by trauma in most cases (Kaloo and Studd, 2001). Diaphragmatic hernia is usually asymptomatic with only unspecific manifestation but during pregnancy because of the increasing intra-abdominal pressure, can be symptomatic but such this situation occurs exceptionally too (Jai et al., 2007). One of the life threatening situations which may be developed accompanying diaphragmatic hernia are herniated visceral obstruction and strangulation from the ruptured diaphragm during pregnancy. The fundamental etiology of rupture is not exactly recognized only it occurs often during delivery (Eglinton et al., 2006). This condition can be resulted in high maternal and fetal mortality because often comes with a delayed diagnosis and management (Mónica Hernández-Aragon Bochdalek, 2015). Upon comprehensive searching in this issue there is only a few cases with strangulation of the stomach within the pregnancy

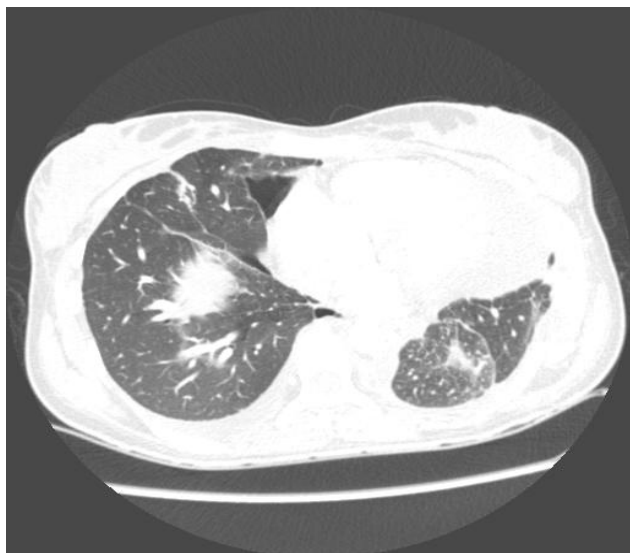
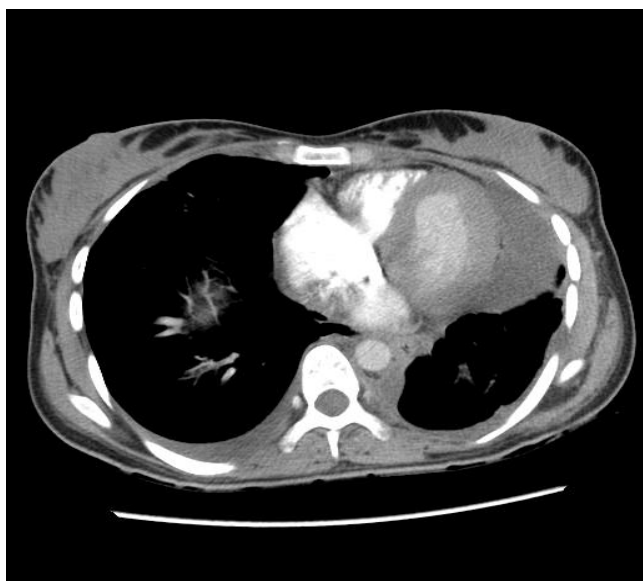
caused by ruptured diaphragmatic hernia in which both mother and fetus have had a favorable outcome (Inmaculada Morcillo-López et al., 2010). Although other cases were reported about stomach rupture without diaphragmatic rupture with survival of either mother and fetus too (Cha et al., 2002; Theresa D. Luu et al., 2006).

### Case presentation

A 19 years old woman referred us in Urgency Department of Emam Khomeini Hospital of Tehran University of Medical Sciences, Tehran, Iran with persistent nausea, vomiting and epigastric pain on her 22<sup>nd</sup> week of gestation. Upon obtaining a complete clinical history, she had no notable findings to declare. She was pale and sinus tarry cardia was discovered in initial electrocardiogram. She suffered of palpitation and her blood pressure was in normal range. Except severe tenderness on the epigastric area her physical exam was otherwise normal. According to the sudden onset vomiting and hematemesis, we performed gastric lavage with normal saline solution and the coffee ground secretion was detected in nose gastric tube had inserted into the stomach. Apart from white blood cells with a tendency to rise her comprehensive laboratory tests were

\*Corresponding author: Setare Nassiri,  
Gynecology Department of Valiasr part of Emam Khomeini Hospital,  
Gynecologist Oncologist

without significant findings. On ultra sound there was a normal alive fetus with regular fetal heart rate. Cervix was mid and closed on speculum examination. Therefore, given the particular manifestation, our presumption was ruptured peptic ulcer despite of its rare incidence during pregnancy. To manage this dilemma consultation with the department surgery was considered and a chest radiography to detect free air under diaphragm for confirming the assertion was planned. Our hospital is a very busy training center so she was waiting in the queue for radiography. During the waiting time she became rehydrate. Ranitidin, Demitron and ceftriaxone were infused her. Suddenly severe respiratory distress was developed resulted in cyanosis. The patient was immediately treated with Oxygen therapy and because of the lack of increase in blood Oxygen saturation, intubation was undertaken.



**Figure 1 and 2.** In these cuts of thoracic computerized tomography severe shift of mediastinum is seen and left lung is compressed due to the pressure of herniated stomach

On portable sonography free fluid were seen in the peritoneal cavity and in the base of left lung like hematoma or empyema. computerized tomography scan (CT scan) was done too, but According her life threatening situation, emergent laparotomy was planned without any special preoperational preparedness. Entrance into the abdominal cavity was done with an upper

midline incision by the general surgeon. There was also a gynecologist on operation. Despite everyone's expectation, the stomach was not in its site and herniated into the chest cavity from the hole created in the diaphragm. Report of CT scan was ready right at the same time and reveled as severe shifting of mediastinum into the left hemi thorax (Figure 1,2) so intra operational Thorax surgery consultation was done resulted in left thoracotomy. There was a strangulated and incarcerated stomach as such the gangrene part of the stomach was resected and gastrorrhaphy was done. He repaired diaphragmatic rupture no need to mesh tool. Finally, a chest tube was embedded in the left hemi thorax. During the entire duration of the operation, uterine manipulation was avoided carefully with only sometimes warm normal saline solution was poured on the uterus and she was transferred into the intensive care unit ward. After 2 days she was extubed and the computerized tomography reveled as favorable prognosis. She discharged one week later and her fetus was in acceptable status. Her cesarean delivery was planned on 39nd week of gestation due to her previous section delivery four years ago. Nevertheless, she was under cesarean section two weeks' sooner caused by premature rupture of membrane. A healthy 2900-gram baby was born. Six months later, the lungs were completely normal on chest radiography.

## DISCUSSION

Ruptured of diaphragm is a very rare condition which may lead to the visceral obstruction and during pregnancy usually can result in high maternal and fetal mortality (Anuradha Kakani *et al.*, 2012). Difference between the two types of hernia, congenital or acquired, is possible by an exact interview with the patient particularly about previous trauma. Our patient had nothing to remember. diaphragmatic ruptured is often caused by a hernia, congenital or aquared.it locates at left side in 90% of cases and our case was in the same side. The presence of caudate lobe of the liver avoids of herniation in the right side of diaphragm (Robert and Heller, 1996). Missed diagnosis occurs in 50% of cases and the most common symptoms are vomiting and epigastric pain. Colon more than other viscera may be herniated and the stomach is the second (Yue Chen *et al.*, 2011). Rupture detection is often difficult and the reason is substantially related to its non-specific manifestation, for example vomiting is a known usual symptom in pregnancy but it alleviates by supportive care whereas vomiting caused by rupture of viscera is sustained and becomes more and more intense such as our patients. If asymptomatic hernia discovered during pregnancy, surgery was recommended in second trimester because increasing in intra-abdominal pressure within normal delivery can be resulted in diaphragmatic rupture but in symptomatic patients' surgery is recommended irrespective of fetus age (Sano *et al.*, 2008). Symptoms are as the spectrum from a slight epigastric pain and nausea to acute abdomen and respiratory distress which is a sign of a tear and imminent death may occur. For diagnosis a chest radiography is sufficient but in our patient we did not it because of our Hospital condition as mentioned ago. We considered urgent surgical intervention in these circumstances although our initial diagnosis was perforated peptic ulcer not strangulated stomach via ruptured diaphragmatic hernia. Probably because our urgent intervention the final out com was exelent.in repaired diaphragmatic rupture, there is challenge in route of delivery but elective caesareans delivery is recommended more, that exploration of repaired site is done during surgery to detect possible secondary defects. Our patient was under cesarean delivery due

to her previous section and integrity of the repaired diaphragm was present.

### Conclusion

Although diaphragmatic rupture is rare in pregnancy but exists and resulted in high maternal and fetal mortality because it is related to herniation followed by obstruction of intra-abdominal viscera. the only way to detect it, is to think about it particularly when the patient symptom is acute and dose not response to usual treatment. Immediate surgical intervention must be considered when the diagnosis comes up.

### Acknowledgments

Miss Rezayof provided technical help, writing assistance and Reproductive Health Research Center, Tehran University of medical sciences provided general support.

### Conflict of interest

All authors have not any conflict of interest to declare.

### REFERENCES

- Anuradha Kakani\*, Richa Choudhary, Jyoti Singh, Deepti Shrivastave, 2012. Late occurrence of a congenital diaphragmatic hernia complicating pregnancy: A case report, *Int J Reprod Contracept Obstet Gynecol.*, 1(1):47-49 DOI: 10.5455/2320-1770.ijrcog000212
- Cha, Ae Seon MD; Krew, Michael A. MD; Tamlyn, Todd MD; Gill, Prabhcharan MD, 2002. Gastric Rupture Associated With Pregnancy *Obstetrics & Gynecology Case Reports: Volume 100 - Issue 5 - p 1072–1074*
- Eglinton T, Coulter GN, Bagshaw P, Cross L. 2006. Diaphragmatic hernias complicating pregnancy. *ANZ J Surg.*, 76(7):553-7.PMID:1681361DOI:10.1111/j.1445-2197.2006.03776.x
- Inmaculada Morcillo-López Juan José Hidalgo-Mora Andrés Baamonde César Díaz-García, 2010. Gastric and diaphragmatic rupture in early pregnancy. *Intracative Cardiovascular and Thoracic Surgery*, 713-715. DOI: 10.1510/icvts.2010.246140
- Jai SR; Bensardi F; Hizaz A; Chehab F; Khaiz D. 2007. A late post-traumatic diaphragmatic hernia revealed during pregnancy by post-partum respiratory distress. *Arch Gynecol Obstet.*, 276:295-298
- Kaloo PD, Studd R, Child, 2001. A Postpartum diagnosis of a maternal diaphragmatic hernia. *Aust N Z J Obstet Gynaecol.*, 41(4):461-3. PMID:11787929
- Mónica Hernández-Aragon, 2015. Bochdalek Diaphragmatic Hernia Complicating Pregnancy in the third Trimester: Case Report. *Obstetric and Gynecology case reviews*. DOI: 10.23937/2377-9004/1410057
- Robert HILL, Heller MB. 1996. Diaphragmatic Rupture Complicating Labor. *Annals of Emergency Medicine*, Volume 27, Issue 4, Pages 522-524, [https://doi.org/10.1016/S0196-0644\(96\)70248-2](https://doi.org/10.1016/S0196-0644(96)70248-2)
- Sano A<sup>1</sup>, Kato H, Hamatani H, Sakai M, Tanaka N, Inose T, Kimura H, Kuwano H. 2008. Diaphragmatic hernia with ischemic bowel obstruction in pregnancy: report of a case. *Surg Today.*, 38(9):836-40. doi: 10.1007/s00595-007-3718-y. Epub 2008 Aug 28, PMID:18751950
- Theresa D. Luu, V. Seenu Reddy, Daniel L. Miller, Seth D. Force, 2006. Gastric Rupture Associated With Diaphragmatic Hernia During Pregnancy. *the Annals Of ThoracicSurgery* DOI: <http://dx.doi.org/10.1016/j.athoracsu.r.2006.02.083>
- Yue Chen, Qiannan Hou, Zhu Zhang, Jian Zhang, Mingrong Xi, 2011. Diaphragmatic hernia during pregnancy: A case report with a review of the literature from the past 50 years, *the journal of obstetrics and gynecology research*. vplum 37, Oissue 7, Pages 709-71416 March 2011 DOI: 10.1111/j.1447-0756.2010.01451.x

\*\*\*\*\*