



RESEARCH ARTICLE

CORRELATION OF RADIOLOGICAL (CT AND MRI) AND HISTOPATHOLOGICAL  
FINDINGS IN TWO CASES OF ANGIOMYXOMA

\*Dr. Rohit Lokhande, Dr. Gunja Dwivedi and Dr. Sagar Satpute

Department of Pathology & Radiology, Rabindranath Tagore Medical College, Udaipur, Rajasthan

ARTICLE INFO

Article History:

Received 15<sup>th</sup> February, 2017  
Received in revised form  
19<sup>th</sup> March, 2017  
Accepted 18<sup>th</sup> April, 2017  
Published online 23<sup>rd</sup> May, 2017

Key words:

Angiomyxoma,  
MRI,  
CT,  
Soft Tissue Neoplasm.

ABSTRACT

Aggressive angiomyxoma (AAM), a rare soft tissue benign neoplasm mesenchymal in origin, predominantly occurs in the female pelvic peritoneum and perineum region during reproductive age. It is slow growing, locally infiltrative, and has a high risk of local recurrence and the neoplastic character of blood vessels. We here present two unusual cases of angiomyxoma presenting as huge abdominal lump. Magnetic Resonance Imaging (MRI) & Computed Tomography (CT) depicted findings of AAM which were confirmed on histopathologic evaluation.

Copyright©2017, Rohit Lokhande et al. This is an open access article distributed under the Creative Commons Attribution License, which permits unrestricted use, distribution, and reproduction in any medium, provided the original work is properly cited.

Citation: Dr. Rohit Lokhande, Dr. Gunja Dwivedi and Dr. Sagar Satpute, 2017. "Correlation of Radiological (CT and MRI) and Histopathological findings in two cases of Angiomyxoma", *International Journal of Current Research*, 9, (05), 50611-50613.

INTRODUCTION

Aggressive angiomyxoma (AAM) was first described in 1983 by Steeper and Rosai. This mesenchymal tumor originates from connective tissue of lower pelvis or perineum and has a locally aggressive course. The neoplasm has predilection in reproductive age females with peak incidence during the third decade of life. The female to male ratio is 6:1 (Bothale, 2012). We report here two cases presented as abdominal lump a very unusual presentation.

Case Report

Case 1

A 40 year old woman presented in surgical OPD with complaints of abdominal lump, weight gain of 12 kg since 1 year associated with dragging abdominal pain. The mass was gradually increasing in size but she did not seek medical advice until she felt difficulty in sitting & walking. There was no difficulty in micturition & defecation. She had normal menstrual history & no history of loss of appetite or weight loss.

\*Corresponding author: Dr. Rohit Lokhande,  
Department of Pathology & Radiology, Rabindranath Tagore Medical College, Udaipur, Rajasthan.

General examination (GE) was not remarkable except she was mild anemic. On Palpation there was firm nontender mass extending from umbilical region into pelvic region of abdomen. There was no hepatosplenomegaly & lymphadenopathy. On Percussion there was dull note. MRI showed axial gadolinium-enhanced T1-weighted spin-echo MR image with fat suppression shows mass with swirled texture displacing uterus anteriorly Sagittal T2 -Weighted shows large tumor with high signal intensity interspersed with swirled strands of lower signal intensity (figure 1 & 2). The patient underwent exploratory laparotomy which showed huge mass extending intraperitoneally from to pelvis & retroperitoneally behind cervix & vagina. This mass weighing 11kg was excised & sent histopathological examination. Grossly, Grey brown encapsulated Soft Tissue Mass (STM) measuring 25×18×12cm cut surface shows grey white solid areas & at one place cystic space seen which was filled with mucinous material.

Case 2

Another case of 40 year old woman presented in surgical OPD with same complaints as that of first case since 9 months but she had 7kg weight gain. GE was unremarkable. Palpatory & percussion findings were same as that of first case.

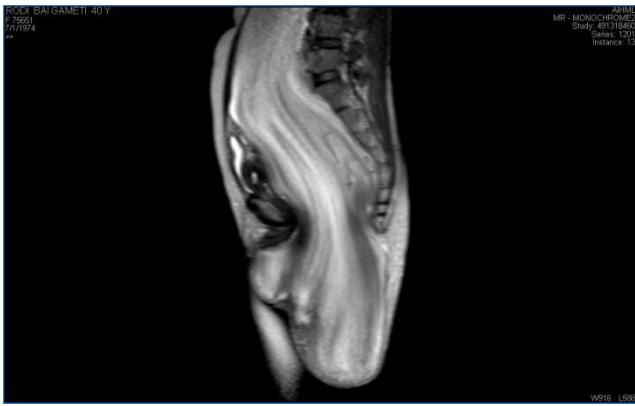


Figure 1. Sagittal T2WI shows large tumor with high signal intensity interspersed with swirled strands of lower signal intensity

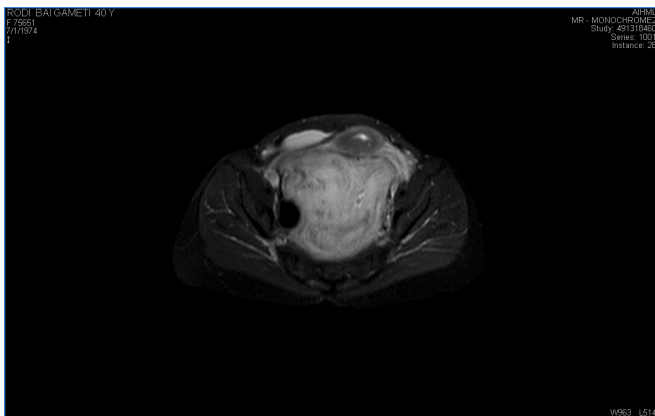


Figure 2. Axial gadolinium-enhanced T1-weighted spin-echo MR image with fat suppression shows mass with swirled texture displacing uterus anteriorly

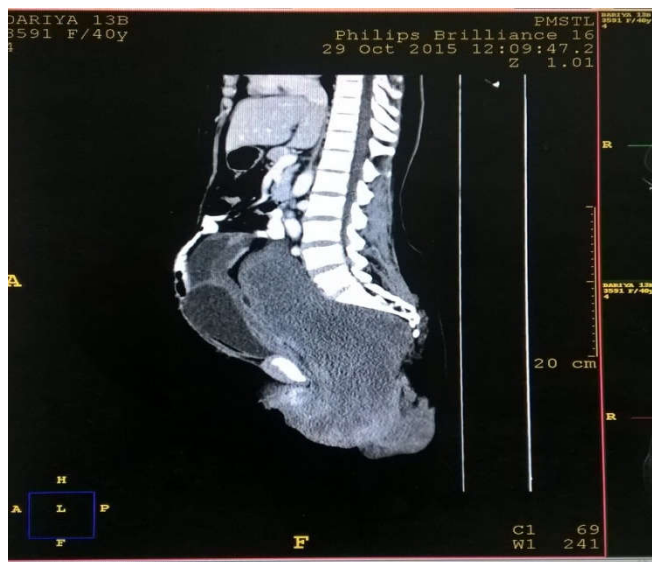

Figure 3. Sagittal contrast enhanced CT image shows low attenuating (compared to muscle) mildly enhancing perineal mass with swirled pattern in pelvis; extending into perineum. The mass is retroperitoneal displacing rectum, bladder, uterus and adnexa anteriorly

CT findings, Sagittal contrast enhanced CT image shows low attenuating (compared to muscle) mildly enhancing perineal mass with swirled pattern in pelvis; extending into perineum. The mass is retroperitoneal displacing rectum, bladder, uterus and adnexa anteriorly (Figure 3).

The patient underwent exploratory laparotomy which showed huge mass which was arising from pelvis weighing 7kg was excised & sent for histopathological examination. Grossly, Grey brown encapsulated Soft Tissue Mass (STM) measuring 14×10×6cm the appearance is edematous and ill defined. On cut section the STM is multicystic these cysts were filled with mucinous material. Microscopy of both cases revealed hypocellular stroma devoid of mitotic activity is seen intermingling with sizable vessels having dilated lumina in myxoid background (Figure 4 & 5). Immunohistochemistry was done in first case which was positive for vimentin (Figure 6).

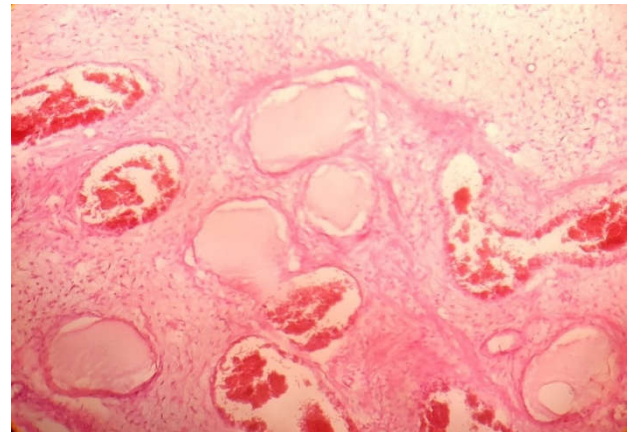


Figure 4. Shows hypocellular stroma & abundant vessels of varying sizes in myxoid matrix

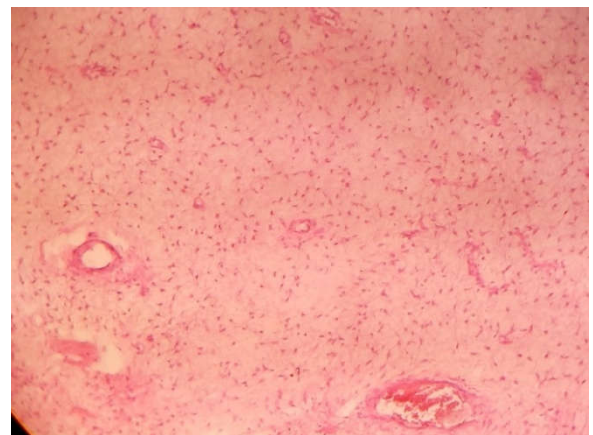


Figure 5. Shows hypocellular stroma with few vessels in myxoid matrix

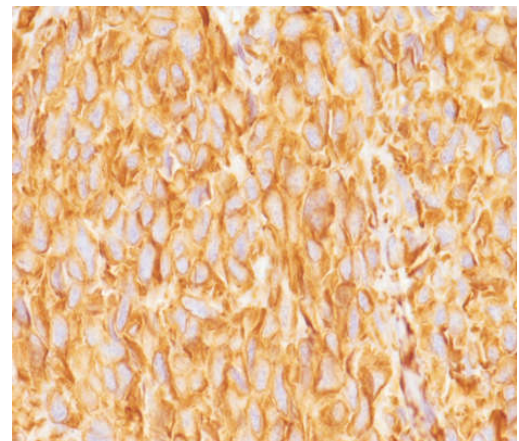


Figure 6. Shows vimentin positivity on Immunohistochemistry in first case

## DISCUSSION

AAM is a compliant tumour that grows slowly in the perineal or pelvic region can cross the pelvic diaphragm. The pathogenesis of AAM is not clear. The true origin is likely mesenchymal. Rare and recent molecular analyses have identified translocation in the 12q13–15 region involving the HMGA2 gene (Brunelle *et al.*, 2013). The role of oestrogens in cancer genesis has already been demonstrated the most widely accepted theory is that estradiol, acting through oestrogen receptor- $\alpha$ , stimulates cell proliferation and leads to mutations arising from replicative errors during premitotic DNA synthesis. A similar mechanism can be hypothesized in AAM (Argiró *et al.*, 2015). Aggressiveness is related to the high rate of local recurrence after surgery because of frequent incomplete excision. This can be due to the absence of a preoperative diagnosis and estimation of the actual extent of the tumour, or to a particular strategic location of the mass near the urethra, vagina, anal sphincter and rectum, with frequent extension through the pelvic diaphragm, making complete resection difficult. Relapses generally occur within 3 years after surgery, but may be more delayed (Brunelle *et al.*, 2013). Reviewing 106 cases, Chan *et al.* found a recurrence rate of 50% between 1984 and 1998. Nowadays, the rate of recurrence is undoubtedly lower (Chan *et al.*, 2000). On CT scan, AAM has a well-defined margin and an attenuation less than that of muscle. The swirled appearance was evident only on enhanced scans. The reason behind swirled appearance is not clear but may relate to the fibrovascular stroma that develops in tumors that are stretched as they protrude through the pelvic diaphragm (Outwater *et al.*, 1999). It also checks for the absence of pelvic hernia, gynaecological prolapse or myoma (Brunelle *et al.*, 2013).

AAM can show typical MRI features: images usually show a perineal mass lesion displacing rather than invading adjacent organs (such as urethra, vagina, anal sphincter, rectum and surrounding fat) and frequently crossing the pelvic diaphragm. The tumour is usually is intense compared with muscle on T1 weighted images, hyper intense on T2 weighted images and avidly enhances after contrast media administration, with typical swirling and layering internal patterns. The hyper intensity on T2 weighted images is most likely owing to the high water and myxoid matrix content of the tumour, while the avid enhancement reflects its high vascularity. The presence of swirling or layering strands in the tumour after contrast media administration can be considered a distinctive diagnostic feature (occurring in about 83% of patients); these strands usually present lower signal intensity in comparison with the remaining tumour on T2 weighted and post-contrast T1 weighted images (Argiró *et al.*, 2015).

The lack of macroscopic fat on CT and MRI sequences with and without fat suppression can rule out infiltrating angiolipoma and lipoma or liposarcoma with or without myxoid component (Brunelle *et al.*, 2013). Histologically, AAM is a benign hypocellular tumour, composed of scattered spindle or stellar cells, embedded in a loose myxoid matrix with a few collagen fibers and abundant vessels of varying sizes. Mitotic figures and necrosis are absent. Infiltration into fat, muscle, and nerves is seen (Monayem *et al.*, 2013). AAM must be distinguished from the more common benign and malignant myxoid tumors including myxoma, myxoid liposarcoma, myxoid neurofibroma, myxoid leiomyoma, leiomyosarcoma, myxoid liposarcoma, myxoid malignant fibrous histiocytoma, and botryoides rhabdomyosarcoma (Bothale *et al.*, 2012). Frequently, tumour cells show positive immunohistochemical staining for desmin, smooth muscle actin, muscle-specific actin, vimentin & hormone receptors. Some tumours are positive for CD345. S100 staining is always negative (Monayem, 2013).

## REFERENCES

- Argiró, R., Sacconi, B., Iannarelli, A., Collini, P., Bezzi, M. 2015. Perineal and pelvic aggressive angiomyxoma: spontaneous regression after hormonal replacement therapy withdrawal assessed by 3T magnetic resonance. *BJR Case Rep*;1: 20150110.
- Bothale, K.A., Mahore, S.D., Joshi, A.M. 2012. A Rare Presentation of Aggressive Angiomyxoma as a Cervical Polyp. *Journal of Basic and Clinical Reproductive Sciences*; 1(1&2):65-7.
- Brunelle, S., Bertucci, F., Chetaille, B., Lelong, B., Piana, G., Sarran, A. 2013. Aggressive Angiomyxoma with Diffusion-Weighted Magnetic Resonance Imaging and Dynamic Contrast Enhancement: A Case Report and Review of the Literature. *Case Rep Oncol*; 6:373–81.
- Chan, Y.M., Hon, E., Ngai, S.W., Ng, T.Y., Wong, L.C. 2000. Aggressive angiomyxoma in females: is radical resection the only option? *Acta Obstet Gynecol Scand*; 79:216–220.
- Monayem, F.B., Parveen, Z., Mahmud, R., Ahmed, S.A.M. 2013. A Case Report on Angiomyxoma. *Faridpur Med. Coll. J*.8(2): 99-101.
- Outwater, E.K., Marchetto, B.E., Wagner, B.J., Siegelman, E.S. 1999. Feb Aggressive angiomyxoma: findings on CT and MR imaging. *AJR Am J Roentgenol.*, 172(2):435-8.

\*\*\*\*\*