



RESEARCH ARTICLE

ASSESSMENT OF THE SYMPHYSIS AND ITS CORRELATION WITH ANTEGONIAL NOTCH IN DAKSHINA KANNADA POPULATION: THE INFLUENCE OF GENDER AND FACIAL TYPE

*Dr. Venisha Ann Alexander, Dr. Anil Kumar and Dr. K. Nillan Shetty

Department of Orthodontics and Dentofacial Orthopedics, A. J. Institute of Dental Sciences,
Mangalore, Karnataka, India-575004

ARTICLE INFO

Article History:

Received 03rd November, 2016
Received in revised form
16th December, 2016
Accepted 15th January, 2017
Published online 28th February, 2017

Key words:

Mandibular symphysis,
Antegonial notch,
Gender, Facial type.

ABSTRACT

Background: The aim was to describe the morphology of the mandibular symphysis and its correlation with the antegonial notch in adults from Dakshina Kannada with well-balanced faces and normal occlusion, individualized in terms of gender and facial type variables.

Methodology: 90 pre-treatment cephalometric radiographs of Dakshina Kannada patients in the age group of 18-35 years, who presented with well-balanced face and normal occlusion were included. The sample was standardized according to gender and facial types. Various angular and linear measurements were carried out.

Results: No significant difference were found among the male and female subjects, except for the inclination and height of mandibular symphysis as well as the antegonial notch depth. Also, the brachyfacial group presented a higher degree of inclination of the alveolar and basal symphysis with increased thickness whereas more anterior projection of mandibular symphysis was exhibited by the dolichofacial group. Significant correlation was seen between the notch depth and anterior projection, height and thickness of the symphysis.

Conclusion: The symphyseal height and the depth of the antegonial notch were more in males. The brachyfacial types exhibited a greater dentoalveolar inclination and a broader basal symphysis while dolichofacial types presented with an increased projection of the symphysis anteriorly. A highly significant correlation was seen between the antegonial notch and the height, thickness and anterior projection of mandibular symphysis.

Copyright©2017, Dr. Venisha Ann Alexander et al. This is an open access article distributed under the Creative Commons Attribution License, which permits unrestricted use, distribution, and reproduction in any medium, provided the original work is properly cited.

Citation: Dr. Venisha Ann Alexander, Dr. Anil Kumar and Dr. K. Nillan Shetty, 2017. "Assessment of the symphysis and its correlation with antegonial notch in dakshina kannada population: The influence of gender and facial type", *International Journal of Current Research*, 09, (02), 46318-46324.

INTRODUCTION

Mandibular symphysis (MS) morphology has an impact on the diagnosis and treatment planning in orthodontic patients. It also serves as a reference anatomical landmark for esthetics of the face in general and of the lower third of the face in particular. Mandibular symphysis morphology may be helpful in predicting the direction of mandibular growth rotations (Al-Khateeb *et al.*, 2014; Endo *et al.*, 2007; Aki, 1994 and Buschang, 1992). Ricketts associated a thick symphysis with an anterior growth direction (Ricketts, 1960). Proclination of symphysis is an indicator of a backward rotating mandible. It has been reported that tooth eruption plays a critical role in the continuous growth of the mandibular symphysis, resulting in an increase in the height of the mandibular body and the centre of the cross section of the symphysis which can be used to

determine changes in the position of the mandibular teeth within the mandible (Moshfeghi, 2014). The shape of mandibular symphysis may also be indirectly affected by factors such as vertical jaw relation and dentoalveolar compensation which occurs during the growth period. Moreover these morphological changes have been linked to physiological adaptation. An increase in the function of the masticatory muscles have been associated with an anterior growth rotation pattern of the mandible (Rosenstein, 1964). Several investigations related anterior growth rotation with a thick symphysis than subjects with longer and narrower symphysis (Kiliaridis, 1995 and Mangla, 2011). It is noteworthy that a recent study using finite element analysis to examine symphyseal loads during masticatory function showed that changes in symphyseal form have profound effects on the strain (Gröning, 2011). The finding that the presence of a prominent chin may help resist higher symphyseal masticating loads indeed corroborates the assumption that individuals with pronounced chin, experience heavier masticatory forces. The origin of antegonial notching has also been an interesting topic

*Corresponding author: Dr. Venisha Ann Alexander

Department of Orthodontics and Dentofacial Orthopedics, A. J. Institute of Dental Sciences, Mangalore, Karnataka, India-575004

for those studying growth and development of the mandible. In the recent years, the mandibular antegonial notch has been associated with different facial characteristics. Studies have shown that shallow antegonial notch (AN) is usually associated with horizontal growth pattern as well as a protrusive mandible whereas deep AN shows large gonial angles, deep ramus notches, large occlusal inclination, long total anterior facial height and less mandibular growth. In addition, females are seen to have shallow AN as compared with males (Lambrechts, 1996). A tendency towards backward mandibular rotation was associated with a pronounced apposition below the symphysis with more overall concavity of the inferior border of the mandible. Deep AN is also commonly seen in congenital and acquired abnormalities of the mandible like condylar hypoplasia and temporomandibular joint ankylosis (TMA), muscular hypoactivity and brachial arch syndrome (Singh, 2011). The pull of the elevators and the depressors mutually resisting their actions due to loss of reciprocal inhibition results in a zone of compression at the fulcrum which is formed ahead of the attachment of the masseter. These compressive forces causes bone resorption leading to a deepening of the antegonial notch (Elsheikh, 1996). Björk's implant studies have shown that in forwardly rotating mandibles, apposition occurs below the symphysis and resorption takes place under the angle (Kolodziej, 2002). Conversely, the mandible which demonstrates a backward and downward rotation during growth experience pronounced apposition beneath the angle with excessive resorption under symphysis. This causes an upward curving of the inferior border of the mandible anterior to the angular process. The direction of mandibular growth and rotation is thus reflected in the location and degree of remodeling on the inferior surface of the mandible. Many studies have been carried out regarding the association of antegonial notch and mandibular symphysis with different growth patterns. However, there are no studies describing the relationship between depth of the antegonial notch and the symphyseal morphology.

MATERIALS AND METHODS

The investigation was conducted on patients reporting to the Department of Orthodontics, A.J. Institute of Dental Sciences, Mangalore seeking orthodontic treatment for the betterment of esthetics. All patients underwent clinical examination and their case history was recorded. Routine records, which included study models, photographs and lateral cephalograms were made (Fig. 1).

Sample selection

The total sample comprised of 90 pretreatment lateral cephalograms of subjects with well balanced faces in the age group of 18-35 years, equally divided between the genders and facial types (Brachyfacial, Mesofacial and Dolichofacial) (Table 1) from Dakshina Kannada population. The inclusion criteria had to be fulfilled by all participants, i.e. apparently symmetrical faces, ANB angle between 0 and 4 degrees, normal occlusion with Class I canine and molar relationship, overjet and overbite up to 3 mm and crowding up to 4 mm and presence of all permanent teeth up to the second molars. Any syndromic or medically compromised patients with a history of facial and dental trauma and previous orthodontic and prosthetic treatment, facial plastic surgery or orthognathic surgery were excluded from this study. To define the facial type, concordance between the subjective facial analysis and

the angle of the mandibular plane (SN.GoGn) were used. Subjects were classified as brachyfacial (SN.GoGn<30°), mesofacial (SN.GoGn between 30° and 34°) and dolichofacial (SN.GoGn>34°).

Table 1. Sample distribution according to gender and facial type

Gender	Brachyfacial	Mesofacial	Dolichofacial	Total
Male	15	15	15	45
Female	15	15	15	45
Total	30	30	30	90

For profile evaluation, the menton neck line (length and angle) was used. Subjects were characterized as brachyfacial when the line was elongated and angle is obtuse. For mesofacial subjects, the line was proportional and angle close to 90°. For dolichofacial subjects, the line was shortened and angle is acute. The shape of the face was assessed by the morphologic facial index and classified into brachyfacial (<83%), mesofacial (84% - 87.9%) and dolichofacial (>88%). The pretreatment lateral cephalometric radiographs were manually traced and the landmarks were located (Fig 2). Various angular and linear measurements with regard to the symphysis morphology and the antegonial notch were obtained (Table 2 and 3). The antegonial notch depth (ND) was also measured for each subject (Fig 3). Data was compiled and statistical analyses i.e. ANOVA, Tukey's 't' test and Pearson's correlation test with an associated confidence level of 95% were performed. Differences were considered statistically significant when the P value was less than 0.05.

RESULTS

Composition and characteristics of the sample

The average ANB angle of the selected sample was 2.52 ±1.37° indicating harmony in the sagittal position of both maxilla and mandible. In this study, the buccolingual inclination of the lower incisors represented the long axis of alveolar symphysis. The cephalometric measurements which contributed to this evaluation were IMPA, FMIA, IiAiMOP and IiAiMe. In general, the average value of lower incisors implanted to the mandibular base (IMPA= 98.95±6.7°), buccally in relation to the Frankfort horizontal plane (FMIA = 53.41±6.6°) and lower occlusal plane (IiAiMOP= 59.18 ±6.13°) and the projection of the long axis of these teeth is about 11.5±3.29 mm after the Me point (Table 4). The amount of buccal and lingual bone at the apex of the lower incisor was measured by BBD and LBD widths, respectively. In this sample, the amount of buccal bone (BBD = 6.17±2.62mm) was almost double than the amount found for lingual bone (LBD= 3.76±1.26 mm) (Table 4). The long axis of the basal symphysis in relation to both the mandibular and Frank fort planes represented by SfMe.GoMe and SfMe.OrPo were measured to be 65.45±6.95° and 86.61±8.59° respectively. The width of the basal symphysis baseline was 13.48±1.7mm (PogPog"), considered more than (BBD LBD = 9.93mm) that of the dentoalveolar symphysis at the apex of the lower incisors. Symphysis height (IiMe) was 42.68±4.1mm and in terms of soft tissue, the projection of the Pog' remained about 9.12±4.37mm below the vertical subnasal line [Pog'Sn (perpOrPo)] (Table 4). The mean antegonial notch for the selected sample was measured to be 1.633±1.09mm.

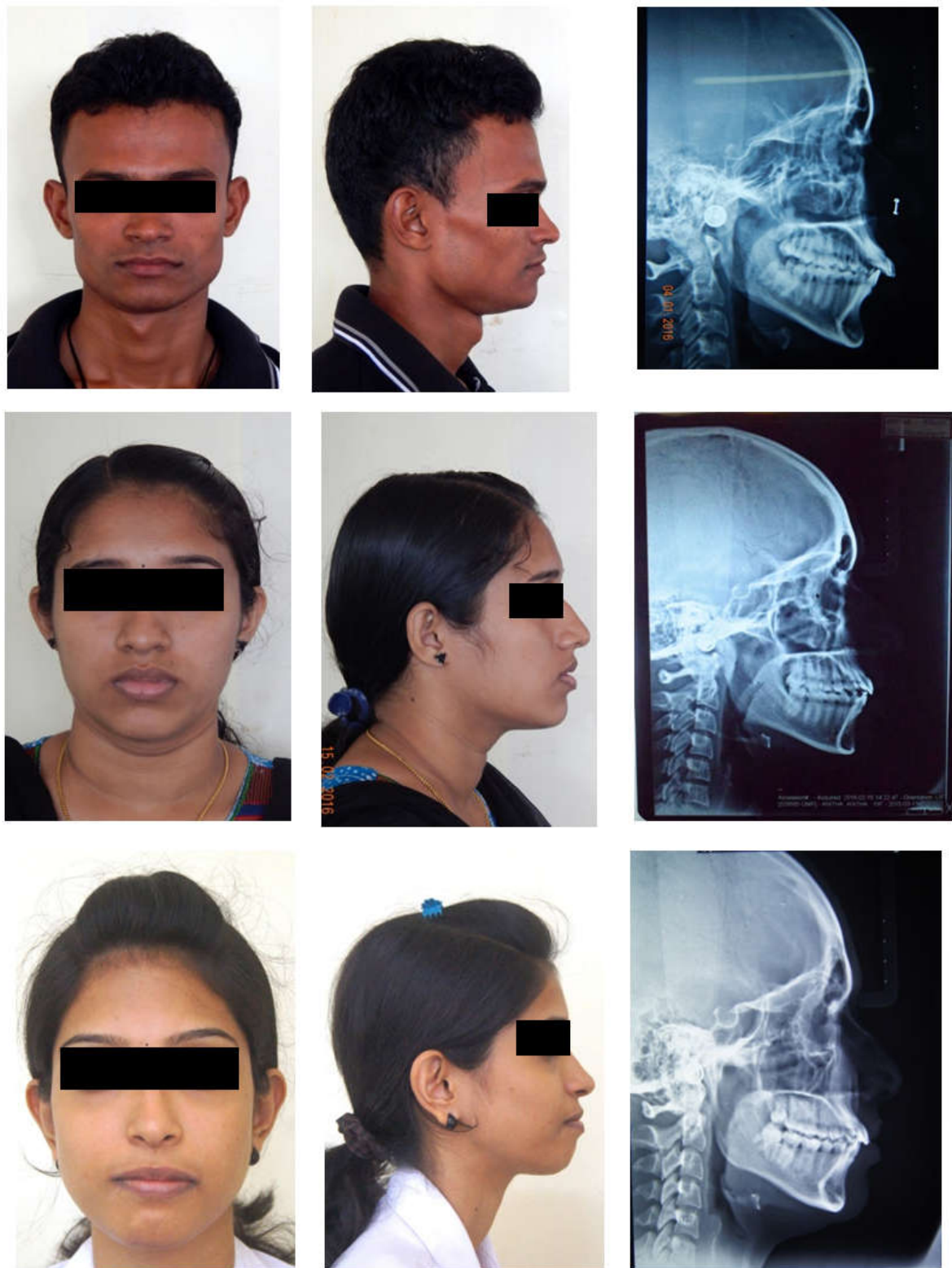

Fig. 1. Extraoral photographs (frontal and lateral view) and lateral radiographs with cephalometric tracing, representative of a) brachyfacial, b) mesofacial and c) dolichofacial

Gender

Regarding gender, the results showed no major statistically significant difference for most cephalometric measurements except in three parameters namely, IiiAliMe (12.18mm for males and 10.82mm for females), IiiMe (44.29mm for males and 41.09mm for females) and antegonial notch (1.87mm for males and 1.4mm for females) (Table 5). Therefore, the inclination and height of the mandibular symphysis as the depth of the antegonial notch were considered a distinguishing feature between genders.

Facial Type

The results of the statistical analysis showed the existence of significant difference in the following parameters (Table 6):

- IMPA was seen to be different between the three growth patterns with brachyfacial (102.26°), mesofacial (98.1°), dolichofacial (96.5°) and this difference was significant with a p value of 0.002.

- BBD was found to be different with brachyfacial (7.26mm), mesofacial (6.36mm), dolichofacial (4.9mm) with a significant p value of 0.042.
- A significant p value of 0.001 was observed in the mean values of PogPog".
- SfMe.GoMe values between the three growth patterns were statistically significant with a p value of 0.031.
- SfMe.Orpo values were statistically different with a p value of 0.000.
- Pog'Sn (perpOrPo) also showed a significant difference with a p value of 0.027.

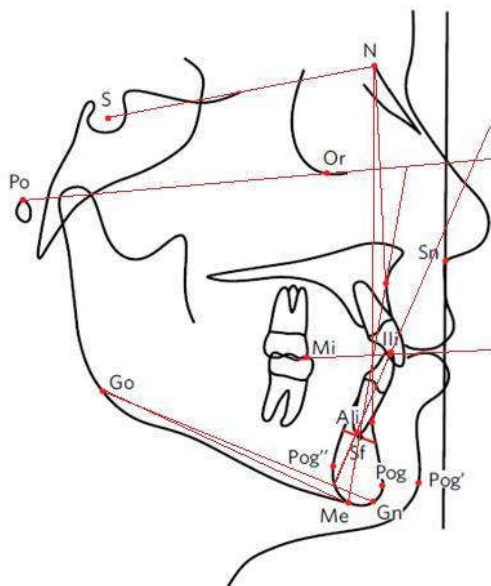


Fig. 2. Angular and linear measurements used to assess symphyseal morphology

Table 2. Description of angular measurements (Aruda, 2012)

Variable	Description
ANB	Angle formed by point A, nasion and point B.
Sn.GoGn	Mandibular plane inclination in relation to the base of the skull
IMPA	Lower incisor inclination in relation to the mandibular plane, also representing the alveolar symphysis inclination.
FMIA	Lower incisor inclination in relation to Frankfort plane.
IliAliMop	Lower incisor inclination in relation to the mandibular occlusal plane
SfMe.GoMe	Inclination of the basal symphysis in relation to the mandibular plane.
SfMe.Orpo	Inclination of the basal symphysis in relation to the Frankfort plane.

Table 3. Description of linear measurements (Aruda, 2012)

Variable	Description
IliAliMe	Distance from the projection of the long axis of the lower incisors on the mandibular plane to the Me point.
BBD-buccal bone distance	The thickness of the buccal alveolar bone, measured from the Ali point to the external buccal cortical point, using the path of the IliAliperp line.
LBD- lingual bone thickness	Comprising the thickness of the lingual alveolar bone at the apex of the lower incisors, measured from the Ali point to the external lingual cortical point, using the path of the IliAliperp line.
PogPog"	Distance between the pogonion and the lingual pogonion points representing the thickness of the basal symphysis.
IliMe	Height of the long axis of the mandibular symphysis.
Pog'Sn (perpOrPo)	Distance from the menton soft tissue to the subnasal line perpendicular to the Frankfort plane.

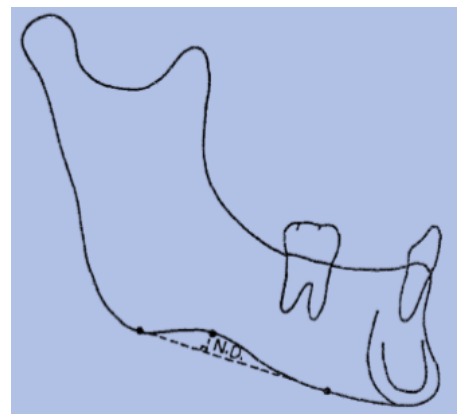


Fig. 3. Linear measurement used for antegonial notch depth

Pearson's correlation test was done to know if any correlation exists between the antegonial notch and the morphology of mandibular symphysis in the selected sample. The obtained results show that a highly significant correlation is seen between the notch depth and anterior projection, height and thickness of the symphysis with a p value of 0.008, 0.001 and 0.044 respectively (Table 7).

DISCUSSION

This study sought to assess symphyseal morphology in Dakshina Kannada population with different mandibular growth patterns (MGPs) and the depth of the antegonial notch in order to see if a relation exists. The selected subjects were divided into 3 groups based on their facial types according to subjective facial analysis and SN.GoGn values. The normative values for mandibular morphology are necessary to identify menton deformities and to carry out surgical orthognathic planning in such cases. Thus, the extent of the surgical movement depends on the pre-surgical measurement of the height and anterior symphysis projection of the face. The normative value guideline of samples from North American Caucasian has been questioned for therapeutic applications in white Brazilians. This is due to the difference in ethnic origin. This suggests that these normative values cannot be applied universally (Arruda, 2012). Hence our study was done to find out the normative values for the same in Dakshina Kannada population to individualize orthodontic planning. Sexual dimorphism in the facial dimensions is a fact that has been established by various analyses (Samal, 2007).

Therefore, the present data had to be divided by gender in order to maintain the homogeneity of the sample. The male and female mandibular symphysis are similar except in cases of distance of the basal symphysis from the Me point and the height of the symphysis. The results showed significant morphological similarity between the dentoalveolar and basal symphysis, both in thickness and inclination. The width of basal symphysis is also similar between the genders. Although the generalized notion is that the male symphysis is much more prominent than in female subjects, the perception of a more projected mandibular symphysis may be due to a greater vertical tendency. Arnett *et al* stated that the height of the mandibular symphysis recommended for male and female Caucasian North Americans is 44mm and 40mm respectively (Arruda, 2012). The current study found 44.29mm and 41.09mm for males and females which are almost similar to the symphyseal height values of North Americans. This can be considered as a differentiating factor between genders.

Table 4. Cephalometric characteristics of the total sample

Variable	Mean	Standard Deviation (\pm)	Maximum Value	Minimum Value
SN.GoGn (degrees)	30.73	5.56	42.00	14.00
IMPA (degrees)	98.95	6.7	117.00	98.50
FMIA (degrees)	53.41	6.6	71.00	38.00
IliAli.MOP (degrees)	59.18	6.13	79.00	45.00
IliAliMe (mm)	11.50	3.29	25.00	1.00
BBD (mm)	6.17	2.62	16.00	3.00
LBD (mm)	3.76	1.26	7.00	1.00
PogPog" (mm)	13.48	1.7	18.00	10.00
SfMe.GoMe (degrees)	65.45	6.95	84.00	52.00
SfMe.OrPo (degrees)	86.62	8.59	105.00	66.00
IliMe (mm)	42.68	4.1	54.00	34.00
Pog'Sn(perpOrPo)(mm)	9.12	4.37	19.00	-1.00
Antegonial Notch (mm)	1.63	1.09	5.00	0.00

Table 5. Cephalometric values of the sample according to gender

Variable	Total	Gender				P Value
		Male		Female		
		Mean	SD(\pm)	Mean	SD(\pm)	
SN.GoGn (degrees)	30.73	30.44	5.84	31.02	5.33	0.625
IMPA (degrees)	98.95	98.24	6.55	99.67	6.96	0.321
FMIA (degrees)	53.41	53.62	6.22	53.20	7.14	0.766
IliAli.MOP (degrees)	59.18	59.04	5.36	59.33	6.88	0.825
IliAliMe (mm)	11.50	12.18	3.36	10.82	3.12	0.050
BBD (mm)	6.17	5.89	2.08	6.47	3.06	0.298
LBD (mm)	3.76	3.78	1.33	3.76	1.21	0.934
PogPog" (mm)	13.48	13.42	1.64	13.56	1.79	0.714
SfMe.GoMe (degrees)	65.45	65.29	7.05	65.62	6.93	0.822
SfMe.OrPo (degrees)	86.62	86.78	8.49	86.60	8.80	0.923
IliMe (mm)	42.68	44.29	4.42	41.09	3.18	0.000
Pog'Sn (perpOrPo) (mm)	9.12	9.96	4.63	8.29	3.98	0.07
Antegonial Notch(mm)	1.63	1.87	1.04	1.40	1.11	0.042

Table 6. Cephalometric values of the sample according to Growth pattern

Variable	Total	Facial Types						P Value
		Brachyfacial		Mesofacial		Dolichofacial		
		Mean	SD(\pm)	Mean	SD(\pm)	Mean	SD(\pm)	
SN.GoGn (degrees)	30.73	24.47	3.82	31.33	1.18	36.40	2.22	0.000
IMPA (degrees)	98.95	102.3	6.58	98.10	5.70	96.50	6.79	0.002
FMIA (degrees)	53.41	55.30	8.17	53.30	5.20	51.63	5.96	0.102
IliAli.MOP (degrees)	59.18	59.63	7.53	58.53	4.53	59.40	6.13	0.769
IliAliMe (mm)	11.50	11.50	4.26	11.90	2.66	11.10	2.78	0.241
BBD (mm)	6.17	7.27	2.90	6.37	2.30	4.90	2.11	0.042
LBD (mm)	3.76	4.23	1.38	3.40	1.10	3.67	1.18	0.648
PogPog" (mm)	13.48	14.37	2.04	13.50	1.43	12.60	1.07	0.001
SfMe.GoMe (degrees)	65.45	67.17	7.84	64.27	6.62	64.93	6.19	0.031
SfMe.OrPo (degrees)	86.62	88.77	10.06	87.77	7.13	83.53	7.67	0.00
IliMe (mm)	42.68	41.27	3.27	43.23	4.21	43.57	4.61	0.066
Pog'Sn(perpOrPo)(mm)	9.12	7.03	4.23	8.33	4.26	12.00	2.98	0.027
Antegonial Notch(mm)	1.63	1.50	1.07	1.73	1.11	1.67	1.12	0.383

Table 7. Correlation of Antegonial notch (mm) with different variables. (Pearson Correlation Values and Significance level)

Variable	Pearson Correlation Value	Significance Level
Antegonial Notch vs. Pog'Sn(perpOrPo) (mm)	0.28	0.008
Antegonial Notch vs. IliMe (mm)	0.33	0.001
Antegonial Notch vs PogPog" (mm)	-212.00	0.044
Antegonial Notch vs LBD (mm)	0.05	0.687
Antegonial Notch vs BBD (mm)	-0.12	0.252
Antegonial Notch vs IliAliMe (mm)	0.01	0.907
Antegonial Notch vs SfMe. Orpo (degrees)	-0.13	0.907
Antegonial Notch vs SfMe. GoMe (degrees)	0.11	0.318
Antegonial Notch vs. IMPA (GoMe.IliAli) (degrees)	-0.04	0.733

The average value for the anterior projection of mandibular symphysis is 9.12mm with no significant difference between the genders (Table 5). Lesser anterior projection was found in white Caucasian Brazilians which is in contrast to North Americans, the values of which were 3.5 \pm 1.8mm for males and 2.6 \pm 1.9mm for females (Artun, 1987).

The lesser projection of menton in white Caucasian Brazilians has also been confirmed by other studies (Arruda 2012 and Handelman, 1996). Although previous study has shown that there is no sexual dichotomy found with regard to antegonial notch, our study revealed that there was a difference seen between male and female genders with a significant level of

0.042 (Table 5). One of the main objectives of this study was to identify possible variations in mandibular symphyseal morphology in different facial types. Between the three groups, a statistically significant difference was found with regard to the thickness and inclination of the basal symphysis to the mandibular plane. Tweed's concept is summarized as inclining the incisors and the alveolar portion in the buccal direction as the tendency to grow becomes more horizontal. But there were no statistically significant changes in the FMIA measurement between the three groups (Tweed, 1954). The distance from the menton soft tissue to the subnasal line perpendicular to the Frankfurt plane, was significantly increased in dolichofacial group with a value of 12 ± 2.98 mm. This denotes that the projection of the symphysis is more anterior as compared to the other two groups. Reference values of symphyseal dimensions are essential, as it is commonly agreed that an especially narrow symphysis is an etiological factor in the development of fenestrations and dehiscences (Gutermann, 2014).

Handelman in 1996 found that in patients with a high mandibular plane, the average thickness of the alveolar symphysis was 5.5mm (Handelman, 1996). The findings of our study indicate a value which is much higher, i.e. 8.57mm. This difference was attributed to the methodological changes between the studies, such as inclusion of patients with malocclusions, extreme vertical growth patterns and different criteria for measuring the alveolar symphysis. This denotes that the alveolar symphysis in the apical region of lower incisor is narrower in dolichofacial groups. The brachyfacial group showed a greater buccal bone distance and alveolar symphysis inclination as compared to the other two groups (Table 6). The thickness of dentoalveolar symphysis can be used to determine the extent of safe orthodontic movement of the lower incisors (Steiner, 1981; Sarikaya, 2002). In our study, the average values were 6.17 mm and 3.76mm for buccal and lingual bone distance respectively. These values were not statistically significant between genders. Previous studies have described dolichofacial types, features of which include narrower and higher alveolar and basal symphysis with greater lingual inclination of lower incisors.

Hence, the distance from the projection of long axis of lower incisors on the mandibular plane to the Me point in dolichofacial group is lesser than that in brachyfacial or mesofacial group. With respect to the antegonial notch, a slight increase was seen in mesofacial group as compared with brachyfacial and dolichofacial groups. To determine the correlation of antegonial notch and symphyseal morphology in the selected sample, Pearson's correlation test was done. It was seen that a correlation exists between the antegonial notch and the anterior projection, height and thickness of the symphysis with a significance level of 0.008, 0.001, and 0.044 respectively (Table 7). Hence, this suggests that an increase in antegonial notch can probably be seen with an increase in the anterior projection, height as well as thickness of the mandibular symphysis.

Conclusion

Based on the results obtained and in accordance with the methodology used, both the symphyseal height and the antegonial notch were differentiating features between the genders and was, on average, higher in males. Well-balanced brachyfacial types showed a greater dentoalveolar inclination,

thickness of the bone near the apex of the lower incisor buccally, thickness of the basal symphysis and inclination of the symphysis in relation to both mandibular plane and Frankfort horizontal plane whereas the dolichofacial types presented with a narrower mandibular symphysis in the alveolar and basal portion and an increased projection of the symphysis anteriorly. No significant difference was revealed with regard to the antegonial notch among the facial types. A significant correlation was seen between the antegonial notch and the height, thickness and projection of mandibular symphysis anteriorly.

Acknowledgment

It is with supreme sincerity and a humble sense of gratitude that I acknowledge my esteemed teacher and research guide Dr. Anil Kumar, Reader, Department of Orthodontics and Dentofacial Orthopedics, A.J. Institute of Dental sciences, Mangalore, for his valuable guidance, constructive suggestions, and commendable professional insight which helped to bring this dissertation to a successful completion. I am also indebted to him for his kind heartedness, meticulous care, and his tireless pursuit for academic excellence throughout my post-graduate course. I would like to sincerely thank my co-guide Prof. Dr. K. NillanShetty HOD, Department of Orthodontics and Dentofacial Orthopedics, A.J. Institute of Dental Sciences, for his valuable suggestions extended to me through his vast knowledge during the period of my post-graduation. I extend my profound gratitude and reverence to Prof. Dr. BharathShetty, Principal for the facilities rendered in this esteemed institution and for providing me the opportunity to perform this study. I extend my sincere gratitude to my family and colleagues for their utmost support. I dedicate this work to my dear family for their selfless sacrifices, unceasing prayers, guidance, love and support which enabled me to reach the present position in life.

REFERENCES

- Aki, T., Nanda, R., Currier, G., Nanda, S. 1994. Assessment of symphysis morphology as a predictor of the direction of mandibular growth. *Am J Orthod Dentofacial Orthop.*, 106(1):60-69.
- Al-Khateeb, S., Al Maaitah, E., Abu Alhaija, E., Badran, S. 2014. Mandibular symphysis morphology and dimensions in different anteroposterior jaw relationships. *Angle Orthod.*, 84(2):304-09.
- Arnett, G., Jelic, J., Kim, J., Cummings, D., Beress, A., Worley, C. Jr. et al. 1999. Soft tissue cephalometric analysis: diagnosis and treatment planning of dentofacial deformity. *Am J Orthod Dentofacial Orthop.*, 116:239-53.
- Arruda, K., ValladaresNeto, J., Almeida, G. 2012. Assessment of the mandibular symphysis of Caucasian Brazilian adults with well-balanced faces and normal occlusion: the influence of gender and facial type. *Dental Press J Orthod.*, 17(3):40-50.
- Artun, J., Krogstad, O. 1987. Periodontal status of mandibular incisors following excessive proclination. A study in adults with surgically treated mandibular prognathism. *Am J Orthod Dentofacial Orthop.*, 91(3):225-32.
- Batista, K., Paiva, J., Rinoneto, J., Queiroz, G., Bozzini, M., Farias, B. 2007. Avaliação estegumentares, esqueléticas e dentárias do perfil facial. *Rev Clin Ortodon Dental Press.*, 5:95-105.

- Buschang, P., Julien, K., Sachdeva, R. and Demirjian, A. 1992. Childhood and pubertal growth changes of human symphysis. *Angle Orthod.*, 62:203-210.
- Chole, R., Patil, R., BalsarafChole, S., Gondivkar, S., Gadbaile, A. and Yuwanati, M. 2013. Association of Mandible Anatomy with Age, Gender, and Dental Status: A Radiographic Study. *ISRN Radiology*. 2013:1-4.
- Elsheikh, M., Medra, AM., Warda, MH. 1996. Bird face deformity secondary to bilateral temporomandibular joint ankylosis. *Journal of Cranio-Maxillofacial Surgery*, 24(2):96-103.
- Endo, T., Ozoe, R., Kojima, K., Shimooka, S. 2007. Congenitally Missing Mandibular incisors and mandibular symphysis morphology. *Angle Orthod.*, 77(6):1079-1084.
- Gröning, F., Fagan, M., O'Higgins, P. 2011. The effects of the periodontal ligament on mandibular stiffness: a study combining finite element analysis and geometric morphometrics. *J Biomech.*, 44(7):1304-1312.
- Gütermanna, C., Peltomäkib, T., Markic, G., Hänggia, M., Schätzlec, M., Signorellia, L., Patcasc, R. 2014. The inclination of mandibular incisors revisited. *The Angle Orthodontist*, Vol. 84, No. 1, pp. 109-119.
- Handelman, C. 1996. The anterior alveolus: its importance in limiting orthodontic treatment and its influence on the occurrence of iatrogenic sequelae. *Angle Orthod.*, 1996;66:95-110.
- Kiliaridis, S. 1995. Masticatory muscle influence on craniofacial growth. *Acta Odontol Scand.* 53(3):196-202.
- Kolodziej, R., Southard, T., Southard, K., Casco, J., Jakobsen, J. 2002. Evaluation of antegonial notch depth for growth prediction. *Am J Orthod Dentofacial Orthop.*, 121(4):357-63.
- Lambrechts, A., Harris, A., Rossouw, P., Stander, I. 1996. Dimensional differences in the craniofacial morphologies of groups with deep and shallow mandibular antegonial notching. *Angle Orthod.*, 66:265-72.
- Mangla, R., Dua, V., Khanna, M., Singh, N., Padmanabhan, P. 2011. Evaluation of mandibular morphology in different facial types. *Contemp Clin dent.*, 2(3):200.
- Moshfeghi, M., Nouri, M., Mirbeigi, S., Baghban, A.A.Z. 2014. Correlation between symphyseal morphology and mandibular growth. *Dent Res J.*, 11(3):375-379.
- Mulie, R., Hoeve, A. 1976. The limitations of tooth movement within the symphysis, studied with laminography and standardized occlusal films. *J Clin Orthod.*, 10:882-93.
- Nojima, K., Nakakawaji, K., Sakamoto, T., Isshiki, Y. Relationships between mandibular symphysis morphology and lower incisor inclination in skeletal Class III malocclusion requiring orthognatic surgery. *Bull Tokyo Dent Coll.*, 39:175-81.
- Ricketts, R. 1960. Cephalometric synthesis. *Am J Orthod Dentofacial Orthop.* 46(9):647-673.
- Rosenstein, S., Chicago, Illinois. 1964. A longitudinal study of Anteroposterior Growth of the Mandibular symphysis. *Angle Orthod.*, 34:155-167.
- Samal, A., Subramani, V., Marx, D. 2007. An Analysis of Sexual Dimorphism in the Human Face *Journal of Visual Communication and Image Representation.* 18(6)453-63.
- Sarikaya, S., Haydar, B., Ciger, S. and Ariyürek, M. 2002. Changes in alveolar bone thickness due to retraction of anterior teeth. *Am J Orthod Dentofacial Orthop.* 122(1):15-26.
- Scavone, H., Zahn-Silva, W., do Valle-Corotti, K., Nahás, A. 2008. Soft tissue profile in white Brazilian adults with normal occlusions and well-balanced faces. *The Angle Orthod.*, 78(1):58-63.
- Singh, S., Kumar, S., Pandey, R., Passi, D., Mehrotra, D., Mohammad, S. 2011. Dimensional differences in mandibular antegonial notches in temporomandibular joint ankylosis. *Journal of Oral Biology and Craniofacial Research*, Original Article Volume 1, Number 1; pp. 7-11.
- Steiner, G., Pearson, J., Ainamo, J. 1981. Changes of the marginal periodontium as a result of labial tooth movement in monkeys. *J. Periodontol.*, 52(6):314-20.
- Tweed, C. 1954. The Frankfort-mandibular incisor angle (FMIA) in orthodontic diagnosis, treatment planning and prognosis. *The Angle Orthod.*, 24:121-9.
- Wehrbein, H., Bauer, W., Diedrich, P. 1996. Mandibular incisors, alveolar bone and symphysis after orthodontic treatment. A retrospective study. *Am J Orthod Dentofacial Orthop.* 110(3):239-46.
- Wehrbein, H., Bauer, W., Diedrich, P. 1996. Mandibular incisors, alveolar bone and symphysis after orthodontic treatment. A retrospective study. *Am J Orthod Dentofacial Orthop.*, 110(3):239-46.
