



RESEARCH ARTICLE

PROTECTIVE EFFECT OF *POLYGONUM COGNATUM MEISSN* ETHANOLIC EXTRACT ON
EXPERIMENTAL HEMORRHOIDS IN RATS

^{1,*}Betul Apaydin Yildirim, ²Saban Kordali, ³Serkan Yildirim and ⁴Fatih Yildirim

¹Ataturk University Veterinary Faculty, Department of Biochemistry, 25240 Erzurum, Turkey,

²Ataturk University, Faculty of Agriculture, Department of Plant Protection, 25240 Erzurum, Turkey

³Ataturk University Veterinary Faculty, Department of Pathology, 25240 Erzurum, Turkey

⁴Ataturk University Veterinary Faculty, Department of Animal Science, 25240 Erzurum, Turkey

ARTICLE INFO

Article History:

Received 03rd November, 2016

Received in revised form

10th December, 2016

Accepted 28th January, 2017

Published online 28th February, 2017

Key words:

Extract,
Hemorrhoid,
Oxidative stress,
Polygonum cognatum,
Rat.

ABSTRACT

In this study was aimed to investigate effects on the levels of plasma and rektanal tissue some biochemical and histopathological parameters of *Polygonum cognatum Meissn* extract on hemorrhoid rats. A total of 32 Sprague Dawley female rats, weighing 200-250 g were used in the present study. Thirty two rats were randomly assigned into 4 experimental groups (8 rats per group). They were allowed to adapt to laboratory conditions for 7 days. The study was conducted for 18 days. Rats were divided into the following groups: Control Group, Croton oil Group, *Polygonum cognatum Meissn* extract (PCE) Group, Croton oil + *Polygonum cognatum Meissn* extract Group. After 3 days of croton oil application, rats were treated with *Polygonum cognatum Meissn* extract for 15 days. Blood and recto-anal tissue samples were collected for biochemical and histopathological studies. Plasma and recto-anal tissue glutathione, catalase, glutathione peroxidase and superoxide dismutase activity were significantly decreased in compared to Croton oil group. Despite this decrease, plasma malondialdehyde; recto-anal malondialdehyde and myeloperoxidase levels increased in this group. In contrast plasma catalase, glutathione peroxidase and superoxide dismutase activity and recto-anal tissue glutathione, catalase, glutathione peroxidase and superoxide dismutase activity were significantly increased, plasma malondialdehyde; recto-anal malondialdehyde and myeloperoxidase levels decreased in following treatment with PCE. *Polygonum cognatum Meissn* extract can play a protective role recto-anal tissue damage and oxidative stress that can be concerned with modulating of antioxidant molecule activities in rat of hemorrhoid which can be used safely for the treatment of hemorrhoids in the large population of patients who do not want to undergo surgery and do not want to use drugs or cream due to their many side effects. *Polygonum cognatum Meissn* extract can play a protective role recto-anal tissue damage and oxidative stress which may be related to modulating the activities of antioxidant molecules in rat model of hemorrhoid.

Copyright©2017, Betul Apaydin Yildirim et al. This is an open access article distributed under the Creative Commons Attribution License, which permits unrestricted use, distribution, and reproduction in any medium, provided the original work is properly cited.

Citation: Betul Apaydin Yildirim, Saban Kordali, Serkan Yildirim and Fatih Yildirim, 2017. "Protective effect of *Polygonum cognatum Meissn* ethanolic extract on experimental hemorrhoids in rats", *International Journal of Current Research*, 9, (02), 46213-46218.

INTRODUCTION

Hemorrhoid are the most common ano-rectal disease which is a term created with combination of haima and rhoos words in Greek. Hemorrhoidal tissues are a part of normal anatomic part of distal rectum and anal channel (Festen et al., 2009; Fuzun, 2007). Hemorrhoids are prolapse and distal displacement of the hemorrhoidal distension, cushions of the hemorrhoidal arterio-venous dilatation or anastomoses of the veins of the internal hemorrhoidal venous plexus proceeding from corruption of anchoring connective tissue (Ganz, 2013). Common symptoms include itching, swelling, bleeding, pain, prolapse and anal disease ; one can employ the term "hemorrhoidal disease" (Festen et al., 2009; Riss et al., 2011).

Nutritional therapy and plant treatments are effective and safe therapy for hemorrhoids (MacKay, 2001), although studies have been poorly for botanical treatments of hemorrhoids (Abascal and Yarnell, 2005). Several plant extracts have been shown to improve vascular tone, capillary flow, strengthen and microcirculation connective tissue of the perivascular amorphous substrate (MacKay, 2001). They can potentially use in treatment of hemorrhoids due to properties anti-inflammatory, antioxidant and anti-oedema (Gami, 2011). Several people are using plants in various forms, as orally or topically but only few plants are studied in scientifically (Abascal and Yarnell, 2005). *Polygonum cognatum Meissn* called "Madimak" is an endemic plant from family of Polygonaceae and is widely consumed in Turkey. *Polygonum cognatum* used as anti-inflammatory effect and a resistance to biologic oxidation (Inaltong, 2015). The mechanisms of *Polygonum cognatum* actions and potency are not enough

*Corresponding author: Betul Apaydin Yildirim,

Ataturk University Veterinary Faculty, Department of Biochemistry, 25240 Erzurum, Turkey.

explained yet and there is no studies regarding therapeutic use of *Polygonum cognatum* in literature. In this direction, the effects of medicinal and aromatic plants which beneficial effects have been known for a long time have begun to research, because the plant is used as extract due to homeostatic effect especially in uterus bleedings, and because the interest has been increased against herbal extracts in our country nowadays, its usability has been researched to prevent and recover hemorrhoid by using as extract. Oxidative stress is basically defined as unbalance between prooxidants and antioxidant in biological system on behalf of prooxidants (Berk *et al.*, 2008). Because oxidative stress may result from the rise of antioxidant defense and free radical production, it may be possible to research antioxidant consumption as oxidative stress bio-indicator and evaluate the decrease in antioxidant amounts or the increase in their metabolites (Blumberg, 2004). Oxidative stress occurred with hemorrhoid causes damage in various tissue and organs. Ethnobotanics studies in Turkey have been demonstrated that the use of plants shown antioxidant and antihemorrhoidal effect relieved hemorrhoid occurrence and its symptoms. Many medicinal plants have been used to treat and prevent hemorrhoid. In the present study, we used an experimental model of hemorrhoid to explore the possible protective effect of *Polygonum cognatum* Meissn ethanolic extract in rats.

MATERIALS AND METHODS

Drugs and Chemicals

Croton oil and all of chemicals were bought from the Sigma Chemical Co. (St. Louis, MO, USA).

Animals

The experimental procedures were administered according to the ethical conditions confirmed by the Ethic Committee of Experimental Animal Teaching and Researcher Center (No: 19.10.2016 36643897-000-ATA-150). Rats were obtained from the Medical and Experimental Application and Research Center (ATADEM), Erzurum, Turkey. Sprague–Dawley female rats, weighing between 200–250 g were housed under standard conditions at 25 ± 2 °C (constant temperature), a relative humidity of $60 \pm 5\%$, a 12 h light-dark rhythm and had free access to a standard diet of food pellets and tap water ad libitum during the study period.

Plant Material

Polygonum cognatum aerial part were collected in July 2016 from Palandöken mountain (Erzurum, TURKEY) and identified by one of the authors Saban KORDALI (Atatürk University, Faculty of Agriculture, Department of Plant Protection, Erzurum). A voucher specimen has been deposited in the Herbarium of Atatürk University, Erzurum (Turkey).

Preparation of the Test Samples

Polygonum cognatum were dried in the shade for 3–4 days. The dried samples were ground to a fine powder in a hammer mill. About 100 g milled plants were taken up into 1000 mL flask and extracted with 500 mL of ethanol for 48 hours at room temperature. The extract was filtered using Whatman filter paper (No.1), and evaporated to dryness in a vacuum at 40 °C with a rotary evaporator after 48 hours. Supernatants

were separated from the suspension by filter and ethanol was removed by using rotary evaporator (RV 05 Basic 1B IKA Group, Wilmington, NC, U.S.A.) under vacuum at 50–60 °C. The dried extracts were stored at +4 °C in the refrigerator for use in the study (Kordali *et al.*, 2009). The extract was dissolved in 5 % DMSO for further study.

Experimental Protocol

A total of 32 Sprague Dawley female rats, weighing 200–250 g were used in the present study. Thirty two rats were randomly assigned into 4 experimental groups (8 rats per group). They were allowed to adapt to laboratory conditions for 7 days. The study was conducted for 18 days. Rats were divided into the following groups:

- Control group (C). Received only vehicle (5 % DMSO) 0.5 mL p.o.
- Croton oil (CO) administered group.
- *Polygonum cognatum* ethanol extract (PCE) administered group. PCE 100 mg/kg/day/p.o 0.5 mL for 15 days.
- CO+ PCE administered group. PCE 100 mg/kg/day/p.o 0.5 mL administered group for 15 days

Hemorrhoids were induced to CO and CO+PCE by applying croton oil preparation (deionized water, pyridine, diethyl ether, and 6% croton oil in diethyl ether in the ratio of 1: 4: 5: 10) in rats as described previously (3, 27). Followed by an overnight fasting before application sterile cotton swabs (4 mm diameter) soaked in 100 µl of croton oil preparation were placed into the anus (rectoanal portion, 20 mm from anal opening) of CO, CO+PCE and kept for 3 days for 30 seconds every morning. A linear development of edema was observed up to 7 to 8 h after the croton oil application. At the end of these processes, rats were anaesthetized with pentobarbital sodium (60 mg/kg/i.p.). The blood was collected into heparinized tubes and then centrifuged at 4000 rpm to separate the plasma and stored at -20 °C for estimating the plasma levels of glutathione (GSH) (Tietze, 1969), malondialdehyde (MDA) (Yoshioka *et al.*, 1979), catalase (CAT) (Goth, 1991), glutathione peroxidase (GPx) (Matkovics *et al.*, 1988) and superoxidodismutase (SOD) (Sun *et al.*, 1988) levels measured with Biotek ELISA Reader (Bio Tek µQuant MQX200 Elisa reader/USA). Dissected rectoanal tissues were harvested and immediately kept in 10% neutral buffered formalin, embedded in paraffin and used for histopathological assay. For biochemical estimation, other tissues were snap frozen in liquid nitrogen and stored at -80 °C until analysis. The piece of recto-anal tissue isolated above was washed thoroughly with ice cold 0.1 M phosphate buffered saline (pH 7.4). It was blotted dry and homogenized in 1.15 % KCl to prepare a 10% w/v suspension in a Teflon-glass homogenizer using (Ultra Turrax Type T25-B, IKA Labortechnik, Germany). This suspension was centrifuged at 16.000 g for 1 h in a cooling centrifuge at 0°C. Homogenates was then employed for further assessment of GSH (Ball, 1966; Fernandez and Videla, 1981), malondialdehyde (MDA) contents as a lipid peroxidation marker were measured using the thiobarbituric acid reaction according to the method of Placer *et al.* (1966), myeloperoxidase (MPO) activity was measured to the method of Krawisz *et al.* (1984), Catalase (CAT) activity was measured as the difference in H₂O₂ extinction per unit time as described previously for assessed catalase enzyme activity (Goth, 1991), the protein concentration was also measured in the supernatant according to the method of Lowry *et al.* (1951), the GPx activity was

Table 1. Effect of PCE on plasma biochemical parameters on hemorrhoid in rats

Groups	GSH (mmol/L)	MDA (mmol/L)	CAT (kU/L)	GPx (U/mL)	SOD (EU/mL)
C	3,16±0,10 ^b	20,08±0,21 ^b	250,34±2,27 ^{ab}	0,22±0,01 ^{ab}	14,34±0,09 ^{ab}
CO	3,08±0,11 ^b	28,18±0,20 ^a	161,59±0,63 ^c	0,19±0,01 ^b	11,06±0,31 ^c
PCE	3,40±0,12 ^{ab}	19,24±0,32 ^b	253,42±1,07 ^a	0,23±0,01 ^a	14,65±0,19 ^a
CO+PCE	3,13±0,25 ^{ab}	19,82±0,26 ^b	246,91±1,18 ^b	0,21±0,01 ^{ab}	13,79±0,16 ^b
P	NS	***	***	*	***

C: Control group; CO: Croton oil administered group; PCE: *Polygonum cognatum* ethanol extract administered group and CO+PCE: Croton oil+ PCE administered group. Data are expressed as means±SEM (n=8). Values in a row with different superscripts differ significantly (NS: Nonsignificant, *P<0.05, ***P<0.001).

Table 2. The effects of PCE on recto-anal tissues biochemical parameters (ANOVA)

GROUPS	GSH (mmol/g)	MDA (nmol/g)	MPO (U/mg)	CAT (kU/g)	GPx (U/mg)	SOD (EU/mg)
C	0,52±0,01 ^{ab}	49,47±0,15 ^c	2,51±0,01 ^c	198,28±0,71 ^a	0,10±0,00 ^b	10,06±0,22 ^b
CO	0,40±0,01 ^c	66,37±0,21 ^a	9,65±0,12 ^a	125,09±0,79 ^c	0,05±0,00 ^d	7,57±0,12 ^d
PCE	0,55±0,01 ^a	48,62±0,23 ^c	2,44±0,01 ^c	201,58±1,71 ^a	0,12±0,00 ^a	11,05±0,19 ^a
CO+PCE	0,48±0,01 ^b	53,34±1,23 ^b	5,36±0,22 ^b	187,92±1,19 ^b	0,09±0,00 ^c	9,09±0,21 ^c
P	***	***	***	***	***	***

C: Control group; CO: Croton oil administered group; PCE: *Polygonum cognatum* ethanol extract administered group and CO+PCE: Croton oil+ PCE administered group. Data are expressed as means±SEM (n=8). Values in a row with different superscripts differ significantly (***P<0.001).

determined according to the method of Matkovic *et al.* (1988), the generation of superoxide radicals produced by xanthine and xanthine oxidase, following the reaction of nitro blue tetrazolium and the formation of formazan dye, was used to measure SOD activity (Sun *et al.*, 1988) with Biotek ELISA Reader (Bio Tek µQuant MQX200 Elisa reader/USA).

Histopathological Examination

Recto-anal tissues were fixed in 10% formal. Thereafter dehydration in a graded ethanol series and clearing with xylene, the sample material was embedded in paraffin and tissue sections 4-µm-thick were cut using microtome (LEICA RM2255), sections were stained with H&E for observation under the light microscope (Leica DM 1000, Germany).

Statistical Analysis of Data

Statistical analysis was done by one-way analysis of variance (ANOVA) using the SPSS software package, version 20.00. Data between groups were tested by ANOVA and post-hoc Tukey's test was used to compare the studied parameters between the groups. P values < 0.05 were considered as significant for all parameters. The results are expressed as mean ± standard error means (SEM) for 8 rats in each group.

RESULTS

As shown in Table 1, application of croton oil to rectoanal portion of rats induced significantly rise in plasma MDA levels (P<0.001), decrease CAT (P<0.001), GPx (P<0.05) and SOD (P<0.001) levels compared to control group. Implementation of croton oil and PCE significantly decreased in levels of MDA levels (P<0.001) as well as increased in plasma CAT (P<0.001), GPx (P<0.05) and SOD (P<0.001) levels compared to CO group but GSH levels were nonsignificant effect. Results of the biochemical tests of GSH, MDA, MPO, CAT, GPx and SOD are shown in Table 2. In the CO group rats, there was significant (P< 0.001) depletion of GSH, CAT, GPx and SOD along with increase in MDA and MPO as compared with the control group (P< 0.001). CO+PCE decreased MDA and MPO levels and significantly restored the antioxidant status as demonstrated by increase in GSH, CAT, GPx and SOD activity in comparison to the croton oil administered group (P< 0.001).

Histopathological Finding

Macroscopically finding (Fig 1) examined showed recto-anal tissues in rat. The recto-anal tissues had a normal appearance in the C and PCE group (Fig1- A-C). Intestinal serosa of recto-anal regions of CO group had hyperemia and regional vessels showed obviously. Intestinal mucosa was bleeding in place and blood stains were showed in feces (Fig 1-B). Mucosa of the recto-anal tissues had a normal appearance but recto anal tissues of CO+PCE group had slightly hyperemia (Fig 1-D).

Microscopically examined sections Fig 2 (A-D) showed the histopathological images of the recto-anal tissues of the C, CO, PCE and CO+PCE administered group in rat. The recto-anal tissue had a normal histological appearance in the C and PCE groups (Fig 2-A, C). Histopathological examination of the recto-anal tissues were found a slight edema in the tunica serosa, hyperemia and severe dilatation in the submucosal vessels in CO administered group. The tunica mucosa showed a hemorrhagic necrotic enteritis that progressed to lamina muscularis (Fig 2-B). Recto-anal tissues of rats in the group of CO + PCE were found to have light infiltration of mononuclear cells in the tunica mucosa, single necrotic cell in the lamina epithelialis and lightly hyperemia in the submucosal vessels (Fig 2-D). Control Group (C) recto-anal tissue showed normal histology (A), H&E, Bar: 20µm. Croton oil (CO) rat showing edema in the tunica serosa, hyperemia and dilatation in the submucosal vessels, infiltration of mononuclear cells, a severe necrotic enteritis in tunica mucosa, hyperemia and dilatation in the vessels, hemorrhage and a severe infiltration of mononuclear cells (B), H&E, Bar: 100µm. Recto-anal tissue of PCE group showed normal histology (C), H&E, Bar: 20µm. Recto-anal tissues of CO + PCE group were found to have lightly infiltration of mononuclear cells in the tunica mucosa and submucosa, few necrotic cell in the tunica mucosa (D), H&E, Bar: 20µm.

DISCUSSION

Many herbal remedies are used in the treatment of hemorrhoid in practically every culture. Turkey has a rich flora and numerous plants have been reported for the treatment of hemorrhoids in Turkish folkloric medicine. In addition to hemorrhoids are one of the major health problems that due to the use of herbal medication (Gulec *et al.*, 2009).

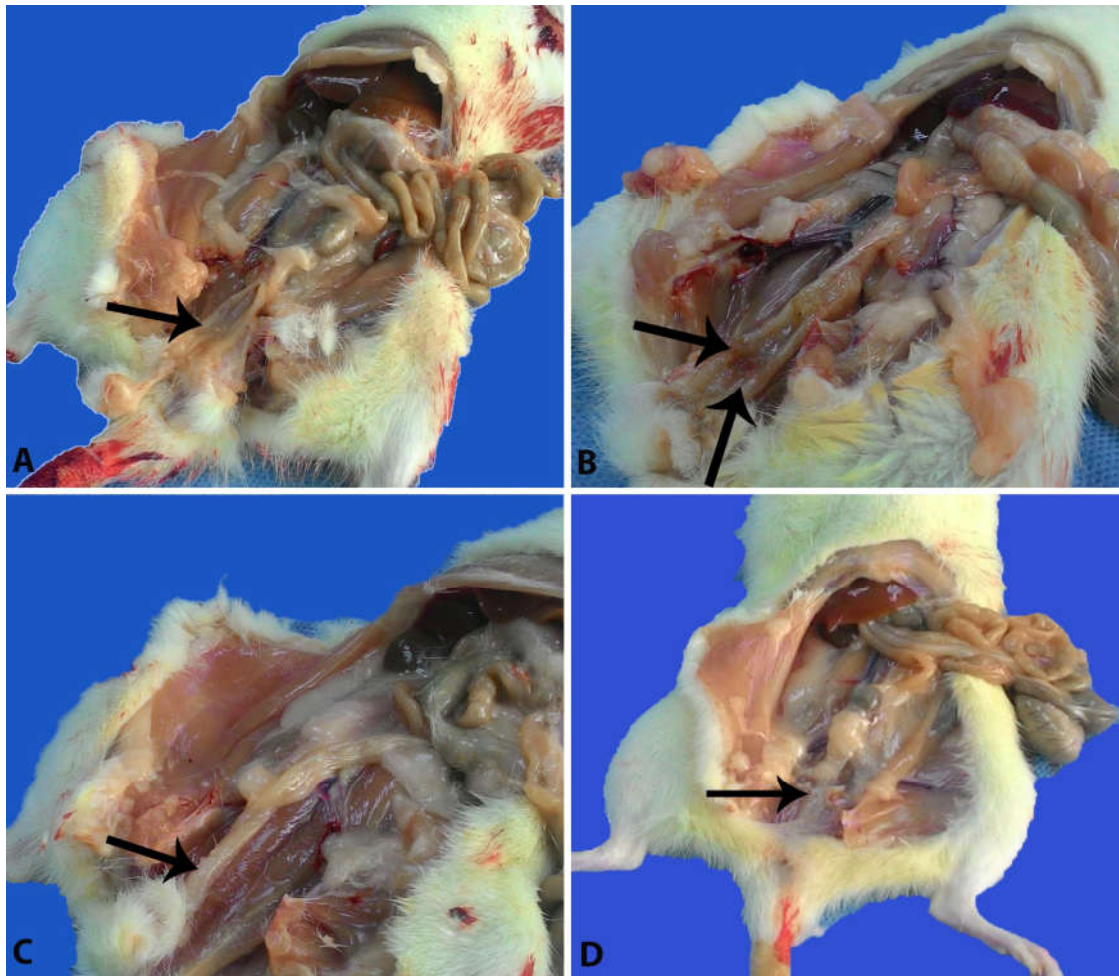


Fig. 1. Normal macroscopic of recto-anal tissues in control group (C) group (black arrow head) (A). Intestinal serosa had hyperemia, hemorrhagic enteritis in mucosa in the CO group (black arrow head), (B). Normal macroscopic of recto-anal tissues in PCE group (black arrow head) (C). Recto anal tissues serosa of CO+PCE group had slightly hyperemia (black arrow head) (D)

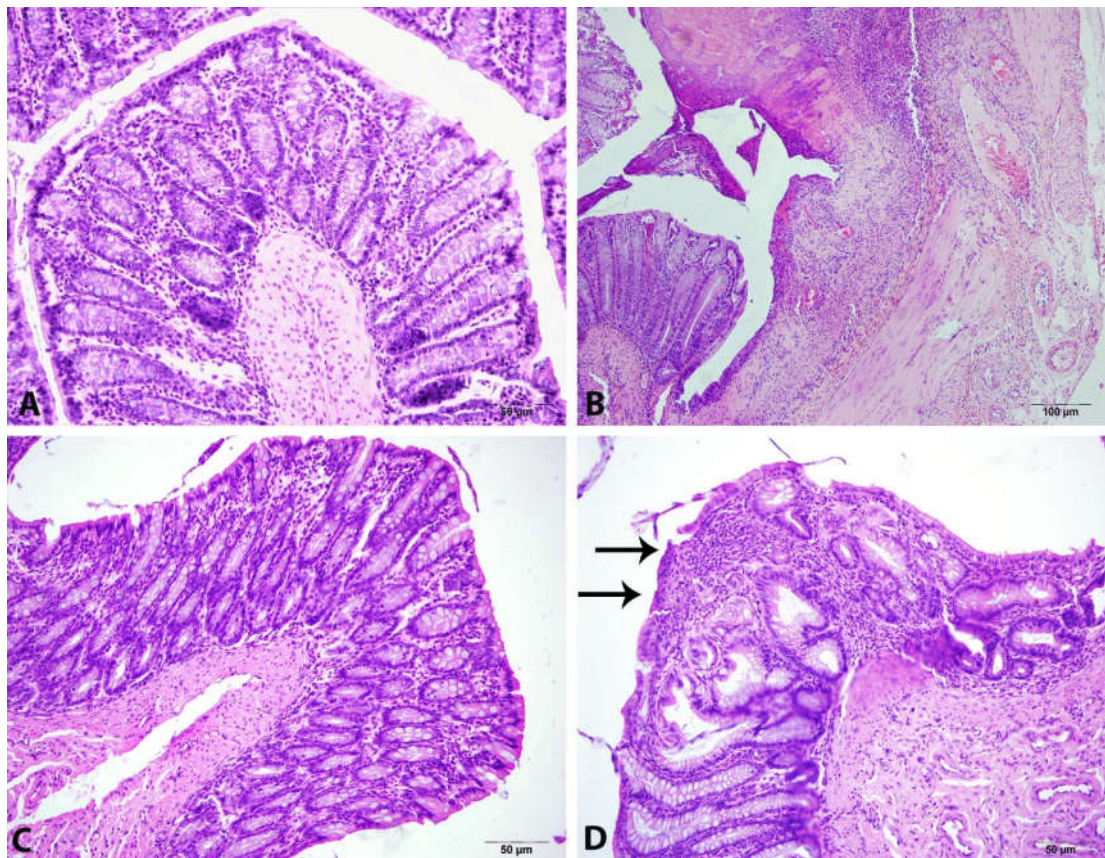


Fig. 2. Effect of PCE on histology of recto-anal tissue croton oil induced hemorrhoid in rat

Treatment of hemorrhoids in modern medicine is still proceed but there is no specific drug to treat hemorrhoids, a lot of people utilizing the natural sources for treating hemorrhoids. *Polygonum cognatum Meissn* belonging to Polygonaceae is widely growing and consuming in Turkey. *Polygonum cognatum Meissn* is included a lot of chemicals, including berbamine, berberine, berberubine alkaloids, tannins, saponines, sterols, triterpenes, carbohydrate, polyuronides and many other compounds which had antibacterial, antioxidant and antitumoral effects (Eksi and Artık, 1998; Cevik *et al.*, 2014). Croton oil application is known to cause inflammation due to the activation of phospholipase A2 that releases arachidonic acid from the cell membrane and the release of soluble factors involving inflammatory cytokines, kinins, lipid metabolites and nitric oxide. These factors regulate the activation of macrophages, fibroblasts, endothelial cells, mast cells, neutrophils, lymphocytes, eosinophils and monocytes leading to response to inflammation (Benito *et al.*, 1998; Gurel *et al.*, 2013). The present investigations showed significant increase in the tissue MDA and MPO activity and plasma levels of MDA in CO compared to control group in accordance with the previous studies (Gurel *et al.*, 2013; Azeemuddin *et al.*, 2014) and confirms the inflammatory changes explained in severity histopathological score. Pathological changes were supported by histological changes of the rectoanal tissues. Decreased in the levels of MDA by PCE treatment supports the antiinflammatory role of PCE in antihemorrhoidal effect. Tannins which is find compound of PCE have antiradical activities and antioxidant. Several studies have shown that tannins decreased MDA, MPO and increased GSH, GPx and SOD levels (Wang *et al.*, 2010; Wang *et al.*, 2011). Tannins are also considered to be components “promoting and development of health” in plant derived beverages and foods (Amarowicz, 2007). Tannins have the ability to chelate metal ions and thus delay oxidation (Karamac, 2009). Saponins were reported to carry antimicrobial, antiinflammatory, antitumoral, antiviral ve antioxidant properties (Sparg *et al.*, 2004), which are effective in GSH, GPx, CAT and SOD metabolism (Bigoniya and Rana, 2010; Li *et al.*, 2010).

We examined noticeable changes in the levels of free radical scavenging enzymes in the PCE treatment groups. Plasma CAT, GPx and SOD activity and recto-anal tissue GSH, CAT, GPx and SOD activity were significantly decreased in compaired to CO group. Despite this decrease, plasma MDA; recto-anal MDA and MPO levels increased in this group. In contrast plasma CAT, GPx and SOD activity and recto-anal tissue GSH, CAT, GPx and SOD activity were significantly increased, plasma MDA; recto-anal MDA and MPO levels decreased in following treatment with PCE. Biochemical and histological results showed that croton oil application induces severe inflammation that is improved with the use of *Polygonum cognatum Meissn* ethanol extract treatment also showed moderate reduction in biochemical and histological damage. This was the first study to use an extract of *Polygonum cognatum Meissn* for the treatment of hemorrhoids based on their antiinflammatory and antioxidant effects. *Polygonum cognatum Meissn* extract might be playing an protective role in hemorrhoids as supports the findings. In the literature have not been reported the antioxidant properties of PCE before.

Conclusion

Consequently, we recommend *Polygonum cognatum Meissn* ethanol extract can be used safely for the treatment of

hemorrhoids in the large population of patients who do not want to undergo surgery and do not want to use glucocorticoids due to their many side effects as biochemical and histopathological findings.

Conflicts of interest

We wish to confirm that there are no known conflicts of interest associated with this publication.

REFERENCES

- Abascal, K. and Yarnell, E. 2005. Botanical treatments for hemorrhoids. *Alternative & Complementary Therapies*, 11: 285-289.
- Amarowicz, R. 2007. Tannins: the new natural antioxidants? *Eur. J. Lipid Sci. Technol.*, 109: 549-51.
- Azeemuddin, M., Viswanatha ,G.L., Rafiq, M., Thippeswamy, A.H., Baig, M.R., Kavya, K.J., Patki, P.S. and Shyam, R. 2014. An improved experimental model of hemor-rhoids in rats: evaluation of antihemorrhoidal activity of an herbal formulation. *ISRN Pharmacology*, 530931: 1-7.
- Ball, C.R. 1966. Estimation and identification of thiols in rat spleen after cysteine or glutathione treatment, pelevance to protection against nitrojen mustards. *Biochem. Pharmac.* 15: 809-816.
- Benito, P.B., Abad, M.M.J., Silvan, S.A.M., San, G.A., Fernandez, M.L., Sanchez and C.S., Diaz L.A.M.: *Life Sciences* 1998, 63, 1147-156.
- Berk, M., Ng, F., Dean, O., Dodd, S. and Bush, A.I. 2008. Glutathione: a novel treatment target in psychiatry. *Trends in Pharmacological Science*, 29: 346-351.
- Bigoniya, P. and Rana, A.C. 2010. Protective effect of *Euphorbia neriifolia* saponin fraction on CCl4-induced acute hepatotoxicity. *African Journal of Biotechnology*, 9:7148-56.
- Blumberg, J. 2004. Use of biomarkers of oxidative stres in research studies. *J. Nutr.*, 134: 3188-3189.
- Cevik, O., Sener, A., Ozdemir Kumral, Z., Cetinel, S., Altıntas, A., Oba, R., Yegen, B.C. and Yarat, A. 2014. Protective and therapeutic effects of *Polygonum cognatum meissn* aqueous extract in experimental colitis. *Marmara Pharmaceutical Journal*, 18: 126-134.
- Eksi, A. and Artık, N. 1998. Bazı Yabani Mey- velerin (Kuşburnu, Yemişen, Alıç, Yaban Mersini, Kızamık) Kimyasal Bileşimi Üze- rine Araştırma. *Gıda Sanayi*, 9: 33-34.
- Fernandez, V., Videla, L.A. 1981. Effect of acute and chronic ethanol ingestion on the content of reduced glutathione of varios tissues of the rat. *Experientia*, 37: 392-394.
- Festen, S., Van Hoogstraten, M. J., Van Geloven, A. A. W. and Gerhards, M. F. 2009. Treatment of grade III and IV haemorrhoidal disease with PPH or THD. A randomized trial on postoperative complications and short-term results. *International Journal of Colorectal Disease*, 24: 1401
- Fuzun, M. 2007. Anorektal Benign Hastalıklar. *Klinik Gastroenteroloji ve Hepatoloji*, 991-2.
- Gami, B. 2011. Hemorrhoids—a common ailment among adults, causes & treatment: a review. *Int. J. Pharm. Pharm. Sci.*, 3: 5-13.
- Ganz, R.A. 2013. The evaluation and treatment of hemorrhoids: A guide for the gastroenterologist. *Clin. Gastroenterol. Hepatol.* 11: 593-603.
- Goth, L. 1991. A simple method for determenation of serum catalase activity and revision of serum catalase activity and

- revision of reference range. *Clin. Chim. Acta.*, 196: 143–152.
- Gulec, M., Ogur, R., Gul, H., Korkmaz, A. and Bakir, B. 2009. Investigation of vasoactive ion content of herbs used in hemorrhoid treatment in Turkey. *Pak. J. Pharm. Sci.*, 22: 187-192.
- Gurel, E., Ustunova, S., Ergin, B., Tan, N., Caner, M., Tortum, O. and Demirci Tansel, C.2013. Herbal haemorrhoidal cream for haemorrhoids. *Chin. J. Physiol.*, 56: 253–262.
- Inaltong, T. 2015. Türkiye'nin otları. <http://www.turkish-cuisine.org/print.php?id=188&link=http://www.turkish-cuisine.org/ingredients-7/ingredients-used-in-turkish-cuisine-66/wild-greens-and-herbs-188.html> (05.05.2015).
- Karamac, M. 2009. Chelation of Cu(II), Zn(II), and Fe(II) by tannin constituents of selected edible nuts. *Int. J. Mol. Sci.*; 10: 5485-97.
- Kordali, S., Cakir, A., Akcin, T.A., Mete, E., Akcin, A., Aydin, T. and Kilic, H. 2009. Antifungal and herbicidal properties of essential oils and n-hexane extracts of *Achillea gypsicola* Hub-Mor. and *Achillea biebersteinii* Afan. (Asteraceae). *Industrial Crops and Products*, 29: 562-570.
- Krawisz, J.E., Sharon, P. and Stenson, W.F. 1984. Quantitative assay for acute intestinal inflammation based on myeloperoxidase activity assessment of inflammation in rat and hamster models. *Gastroenterology*, 87: 1344–1350.
- Li, Y.G., Ji, D.F., Zhong, S., Shi, L.G., Hu, G.Y. and Chen, S. 2010. Saponins from *Panax japonicus* protect against alcohol-induced hepatic injury in mice by up-regulating the expression of GPX3, SOD1 and SOD3. *Alcohol Alcohol*, 45: 320-31.
- Lowry, O.H., Rosenbrough, N.J., Farr, A.L. and Randall, R.G. 1951. Protein Measurement with the Folin Phenol Reagent; *J. Biol. Chem.*, 193: 265-269.
- MacKay, D. 2001. Hemorrhoids and varicose veins: a review of treatment options. *Alternative medicine review*, 6: 126-126.
- Matkovics, B., Szabo, L. and Varga, I.S. 1988. Determination of enzyme activities in lipid peroxidation and glutathione pathways. *Laboratoriumi Diagnosztika*, 15: 248–249.
- Placer, Z.A., Cushman, L.L. and Johnson, B.C. 1966. Estimation of product of lipid peroxidation (malonyldialdehyde) in biochemical systems. *Anal. Biochem.*, 16: 359-364.
- Riss, S., Weiser, F.A., Riss, T., Schwameis, K., Mittlboock, M. and Stift, A. 2011. Haemorrhoids and quality of life. *Colorectal Dis*, 13: 48-52.
- Sparg, S.G., Light, M.E. and van Staden, J. 2004. Biological activities and distribution of plant saponins. *J Ethnopharmacol*, 94: 219-43.
- Sun, Y., Oberley, L.W., Li, Y. 1988. A simple method for clinical assay of superoxide dismutase. *Clin. Chem.*, 34: 497-500.
- Tietze, F. 1969. Enzymic method for quantavite determination of nanogram amounts of total and oxidized glutathione. *Anal. Biochem.*, 27: 502-522.
- Wang, Y.H., Ge, B., Yang, X.L., Zhai, J., Yang, L.N., Wang, X.X., Liu, X., Shi, J.C. and Wu, Y.J. 2011. Proanthocyanidins from grape seeds modulates the nuclear factor-kappa B signal transduction pathways in rats with TNBS-induced recurrent ulcerative colitis. *Int. Immunopharmacol.*, 11: 1620-7.
- Wang, Y.H., Yang, X.L., Wang, L., Cui, M.X., Cai, Y.Q., Li, X.L. and Wu, Y.J. 2010. Effects of proanthocyanidins from grape seed on treatment of recurrent ulcerative colitis in rats. *Can. J. Physiol. Pharmacol.*, 88: 888-98.
- Yoshioka, T., Kawada, K., Shimada, T., Mori, M. 1979. Lipid peroxidation in maternal and cord blood and protective mechanism against activated oxygen toxicity in the blood. *Am. J. Obstet. Gynecol.*, 135: 372-376.
- Zhang, Y., DeWitt, D.L., Murugesan, S. and Nair, M.G. 2004. Novel lipid- peroxidation- and cyclooxygenase-inhibitory tannins from *Picrorhiza kurroa* seeds. *Chem. Biodivers.*, 1: 426-41.
