



CASE STUDY

ESTHETIC AND FUNCTIONAL REHABILITATION OF PATIENT WITH OLIGODONTIA AND MIXED DENTITION

***Sharma Monesh, S., Bondekar Vaishali and Vartak Vikas**

Department of Prosthodontics and Crown & Bridge, Y.C.M.M. & R.D.F's Dental College and Hospital, Ahmednagar

ARTICLE INFO

Article History:

Received 17th July, 2016
Received in revised form
22nd August, 2016
Accepted 28th September, 2016
Published online 30th October, 2016

Key words:

Tooth agenesis, Nonsyndromic
Oligodontia, Mixed dentition,
Modified swing lock cast partial denture,
Prosthetic rehabilitation.

ABSTRACT

The term 'Hypodontia' refers to the developmental absence of one or more teeth, either in primary or permanent or mixed dentition, excluding the third molars. It is the most common craniofacial malformation. If six or more permanent teeth are missing, the term 'Oligodontia' is used. Oligodontia creates significant challenges to the clinicians in both diagnosis and management. The ability to address this condition during the early stages of the dentition maximizes the potential for a treatment with functional, esthetic, and stable results. This case report presents prosthodontic management of a case of nonsyndromic Oligodontia with mixed dentition of a 18-year-old male patient. Combination of fixed prosthesis and Removable partial denture with modified swing lock design was used for functional and esthetic rehabilitation of a patient.

Copyright © 2016, Sharma Monesh et al. This is an open access article distributed under the Creative Commons Attribution License, which permits unrestricted use, distribution, and reproduction in any medium, provided the original work is properly cited.

Citation: Sharma Monesh, S., Bondekar Vaishali and Vartak Vikas, 2016. "Esthetic and functional rehabilitation of patient with oligodontia and mixed dentition", *International Journal of Current Research*, 8, (10), 39929-39932.

INTRODUCTION

Tooth Agensis is the congenital absence of one or more of the normal complement of teeth (The glossary of prosthodontic terms, 2005) and is one of the most frequent alterations of the human dentition. Although, Tooth Agensis does not represent a serious public health problem, it may cause both speech and masticatory dysfunction as well as aesthetic and functional problems (Creton *et al.*, 2009). Tooth Agensis has been classified in Literature as Hypodontia (2-6 Teeth Missing), Oligodontia (>6 Teeth Missing) and Anodontia (all Teeth Missing). Tooth Agensis occurs in up to 1.5 % -3 % of the population. Tooth Agensis and its associated syndromes are more prevalent in females than males by a ratio of 3:2. Usually affected teeth are the ones which develop later viz. Incisors. These subjects usually present with shorter anterior and overall cranial base length, retrognathic jaws and counterclockwise-rotated occlusal plane (Endo *et al.*, 2006). They have reduced alveolar bone formation in the affected edentulous areas. These subjects they usually have reduced values of Oral Stereognostic and Oral Motor Abilities. Different treatment options available to these affected individuals include Osseointegrated Implants, Fixed and/or Removable Prosthesis with or without

orthodontic management to align the teeth and to close the abnormal tooth spaces. Genetic engineering can be a new target in tooth loss therapy. However, these subjects require a multi disciplinary team approach for their successful rehabilitation. This require a detailed treatment planning and regular follow ups to provide a stable and effective functional and psychological rehabilitation which will ultimately improve the subject's quality of life. This report explains the clinical prosthodontic management of non syndromic hypodontia with Conventional Fixed prosthesis and cast partial denture with modified swing lock attachment.

Case report

A 18year old male patient was referred from department of orthodontics after correction of spaced out dentition to department of prosthodontics for restoration of missing teeth. A review of the patient's past medical history revealed no associated syndrome. On clinical examination tapering face with reduction in lower facial height, marked nasolabial angle and procumbent lip contours (Fig.1). Intraoral examination reveals missing teeth as 12,14,15,22,24,25,31,32,33,34,35, 41,42,43,44,45. However along with remaining permanent teeth, all second deciduous molars were also present. Alveolar ridge with respect to missing teeth was knife edge with hypermobile soft tissue covering it. (Fig.2-4)

***Corresponding author: Sharma Monesh, S.**

Department of Prosthodontics and Crown & Bridge, Y.C.M.M. & R.D.F's Dental College and Hospital, Ahmednagar

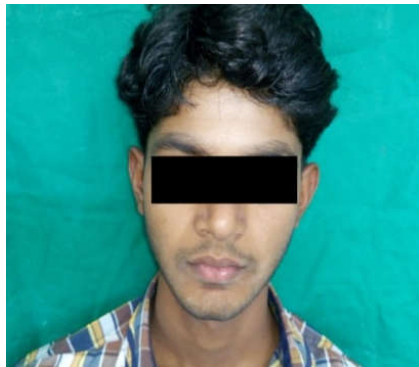

Fig.1. Preoperative facial

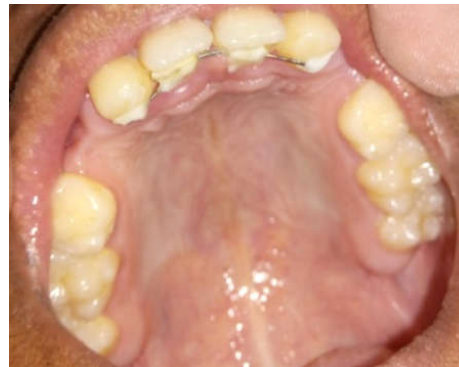

Fig.2. Intra oral view- maxillary arch

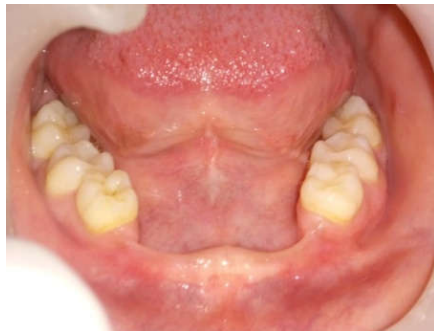

Fig.3. Intraoral view- mandibular arch

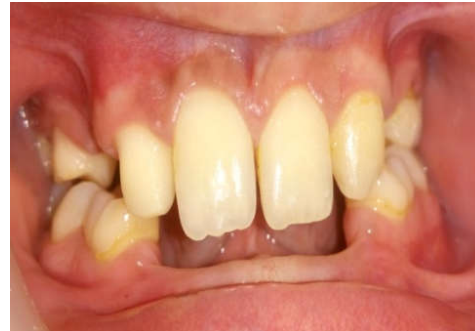

Fig.4. Intra oral view in occlusion

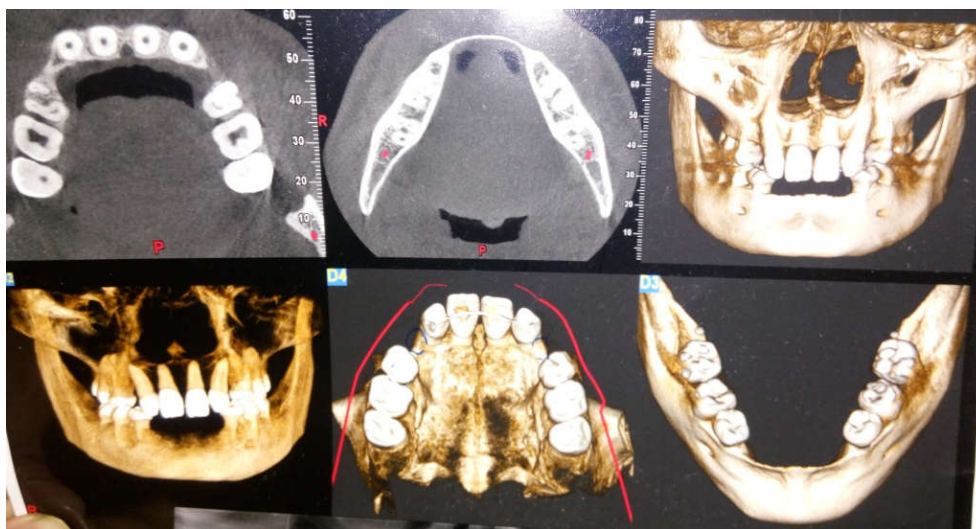


Fig.5. CBCT Views

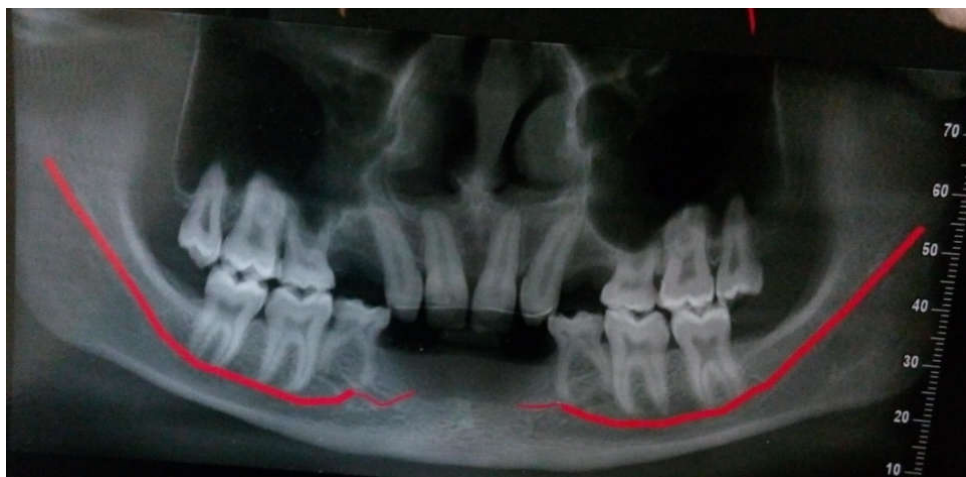

Fig. 6. OPG of patient

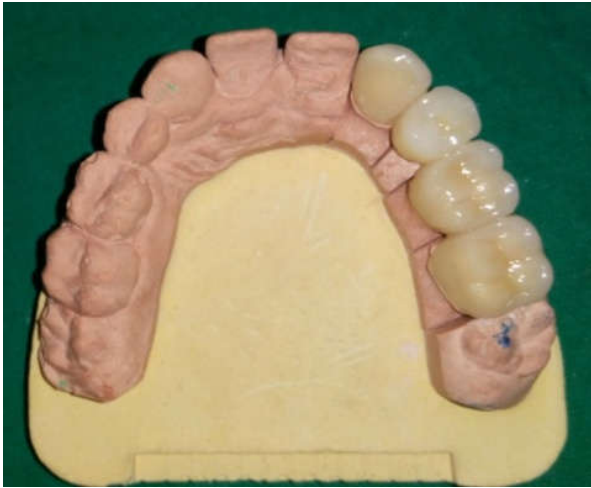

Fig. 7. Monolithic zirconium FPD

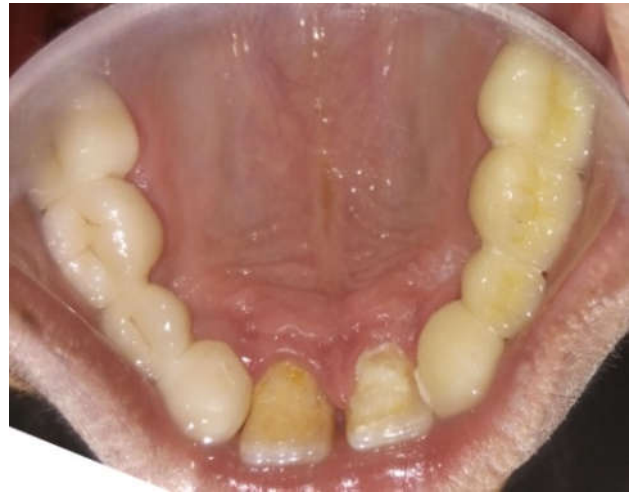

Fig.8. Cementation of upper FPDs

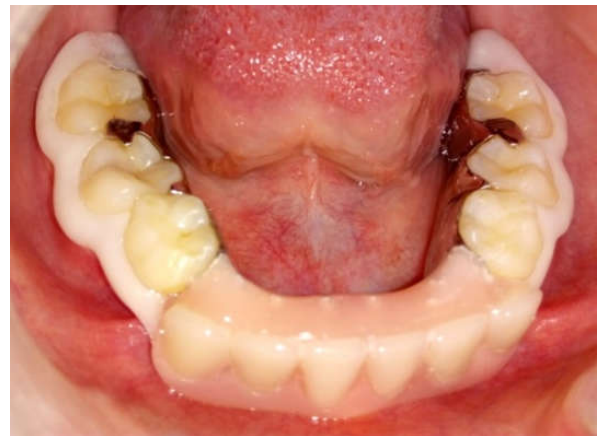
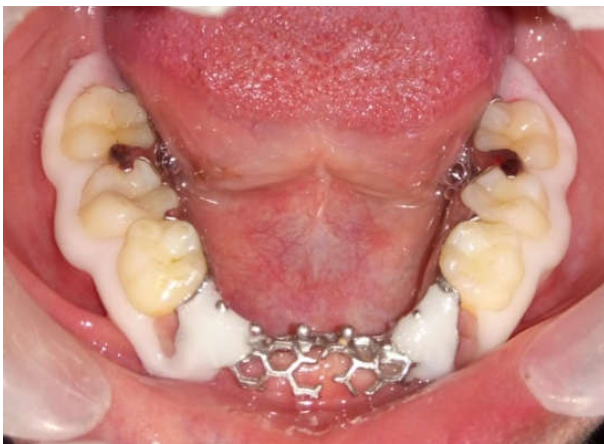
Fig.9. Try in of CPD framework with Wrap around acetyl resin design Fig.10. CPD With modified swing lock Attachment inserted

Orthopantomograph and cone beam computed tomography reveals agenesia of alveolar bone in region of missing teeth (Fig. 5,6). Different treatment options like Osseointegrated implant supported prosthesis and conventional fixed prosthesis using a variety of materials were considered. After a thorough evaluation and discussion with patient, a conventional fixed all-ceramic prosthesis in maxillary arch while cast partial denture with modified swing lock attachment in mandibular arch was planned. In maxillary arch tooth preparation was carried out with 13, 55, 16 and 23,65,26. Following gingival retraction, impression procedures and temporisation procedure; monolithic variant of zirconia ceramic fixed partial dentures were cemented (Fig.7,8). In mandibular arch, after surveying and mouth preparation procedures; it was decided to fabricate cast partial denture with modified swing lock attachment due to inadequate tissue support from edentulous region and absence of any appreciable desired undercuts. Buccal portion of remaining teeth viz 75,36,37,85,46,47 were encircled with aesthetic arm of acetyl resin polymer (Fig.9,10). Necessary occlusion correction done following insertion of cast partial denture. Follow up was done after 24 hrs, one week, 3 months, 6 months.

DISCUSSION

Due to non availability of adequate bone in edentulous zone and patient's unwillingness for intensive invasive bone augmentation procedures, conventional implant therapy was

not perceived. In maxillary arch, for esthetic as well as functional rehabilitation, zirconium alloys were preferred. Due to unpredictability long term success, deciduous molar as only abutment tooth is best avoided. Additional support from healthy abutment is advisable. During the prosthetic rehabilitation, remaining structure should properly used to distribute the occlusal forces to all teeth and stress bearing areas. Swing-lock prosthesis which was introduced in 1963 utilizes all the remaining teeth instead of few abutments for retention and stabilization (Simmons, 1963). Conventionally, it is used for the periodontally compromised abutment teeth to stabilize after periodontal therapy (Antos *et al.*, 1978). Javis *et al.* suggested that swing-lock is compatible where the conventional designs those are not suitable and that could not be used for added retention in the defect area (Javid and Dadmanesh, 1976). To retain the prosthesis, a retentive part is applied to an abutment tooth which can be fabricated of metal (chromium cobalt), acetyl resin and acrylic resin. In the esthetic region, acetyl resin can be an alternative to chromium cobalt (Cr-Co), which is the thermoplastic technopolymer formed by polymerizing formaldehyde. It provides not only superior esthetic but also superior flexibility making preferable to use in the undercut areas (Mohamed *et al.*, 2011). Acrylic resins are used normally as an acrylic veneer, by locking into labial undercuts of abutment teeth (Becker and Bolender, 1981). The advantage of swing-lock design is to increase the retention and stability by making with the more tooth surface area and the undercut. Besides wrap around swing lock design labial sulcus

depth and high frenal attachment are not concern compared to that of conventional one as it uses interproximal undercuts on labial and buccal aspect of remaining teeth. Although acetyl resin clasps are, resilient to engage the undercuts, for the retention of the prosthesis, greater thickness is required compared to the metal clasp due to lower flexural modulus (Wu *et al.*, 2003). The thicker design can cause the accumulation of the plaque and affect the gingival and periodontal health. Therefore, the patient should be encouraged for the hygiene.

Conclusion and Summary

From detailed history and thorough clinical examination we came to the final diagnosis that this case is of non syndromic oligodontia. Management of such cases are commonly done using combination of fixed and removable prosthesis. The simplicity of the modified SL-RPD allows it to be used more frequently in situations for which more conventional types of treatment may appear hopeless. Swing-lock with wrap around acetyl clasp can optimize the retention and stabilize along with splinting of the remaining teeth without polyacetyl compromising the esthetic and function. The technique was characterized by simplicity, resiliency, durability, ease of adjustment and maintenance, and finally economics.

REFERENCES

- Antos, E.E., R.P. Renner and D. Foerth, 1978. The swing lock partial denture: An alternative approach to conventional removable partial denture service. *J Prosthet. Dent.*, 40: 257-267.
- Becker, C.M. and C.K.L. Bolender, 1981. Designing swing lock removable partial dentures. *J. Prosthet Dent.*, 146: 126-132
- Creton M, Cune MS, de Putter C, Ruijter JM, Kuijpers-Jagtman AM. Dentofacial characteristics of patients with hypodontia. 2009. *Clin Oral Investig*, (E Pub ahead of Print).
- De Coster PJ, Marks LA, Martens LC, Huysseune A. 2009. Dental Agenesis: genetic and clinical perspectives. *J Oral Pathol Med.*, 38(1):1-17.
- Endo T, Ozoe R, Yoshino S, Shimooka S. 2006. Hypodontia patterns and variations in craniofacial morphology in Japanese orthodontic patients. *Angle Orthod.*, 76 (6):996-1003
- Javid, N.S. and J. Dadmanesh, 1976. Obturator design for hemimaxillectomy patients. *J. Prosthet. Dent.*; 36(1): 77-81
- Mohamed, T., O.A. Baraka and M.M., 2011. Badawy. Comparison between acetyl resin and Cobaltswinglock chromium removable partial denture clasps: Effect on abutment teeth supporting structures. *Int J.Prostodont. Rest. Dent.*, 1(3): 147-154.
- Simmons, J.J. 1963. Swing lock stabilization and retention. A preliminary clinical report. *Tex. Dent. J.*, 81: 10-12.
- The glossary of prosthodontic terms, *J Prosthet Dent*, 2005;94 (1):76.
- Wu, J.C., G.H. JrLatta, R.A. Wicks, R.L. Swords and. M. Scarbecz, 2003. *In vitro* deformation of acetyl resin and metal alloy removable partial denture direct retainers. *J.Prosthet. Dent.*, 90(6): 586-90.
