



ISSN: 0975-833X

RESEARCH ARTICLE

COMMON RADIOLOGICAL MISDIAGNOSIS IN DENTISTRY

^{1,*}Karthik, R. and ²Mohan, N.

¹Reader, Department of Oral Medicine and Radiology, Vinayaka Missions Sankarachariyar Dental College, Salem

²Professor and Head of Department, Department of Oral Medicine and Radiology, Vinayaka Missions Sankarachariyar Dental College, Salem

ARTICLE INFO

Article History:

Received 23rd June, 2016
Received in revised form
19th July, 2016
Accepted 15th August, 2016
Published online 20th September, 2016

ABSTRACT

In the Modern era of Digital imaging there are some common radiological misdiagnosis encountered by the students and dentists in their general practice. This article describes some of the common radiological misdiagnosis in dentistry.

Key words:

Cervical Burn out, Mach Band Effect,
Dental Papilla, Follicularspace,
Stafnecyst, Intermaxillarsuture,
Nutrientcanals, Stafnecyst,
Caninefossa, Nasolacrimal Canal.

Copyright©2016, Karthik and Mohan. This is an open access article distributed under the Creative Commons Attribution License, which permits unrestricted use, distribution, and reproduction in any medium, provided the original work is properly cited.

Citation: Karthik and Mohan. 2016. "Common radiological misdiagnosis in Dentistry", International Journal of Current Research, 8, (09), 38185-38192.

INTRODUCTION

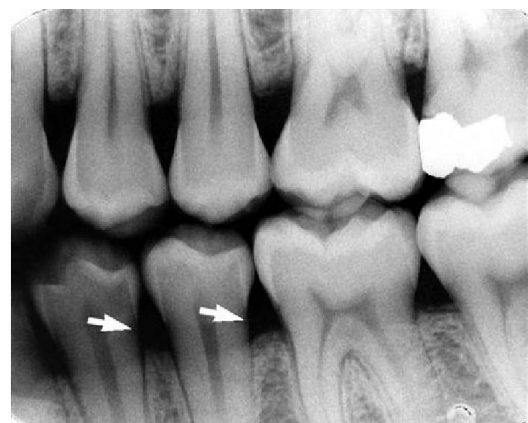Cervical burnout

Overpenetration of Xrays near the thinner cervical tooth areas produces radiolucent areas that have rounded, diffuse inner borders, but that show intact tooth edges referred to as Cervical Burnout that can be misdiagnosed as Proximal Root Caries. Mach bands (named after the scientist Ernst Mach) produced by lateral inhibition of neural receptors in the eye, are optical illusions that may appear in the dentin along the proximal DEJ (Dentino-Enamel Junction), or in dentinal peaks bounded by occlusal and proximal enamel. The Mach-band is usually misdiagnosed as Incipient caries. Mach Bands are independent of orientation. Not every observer has the same ability to perceive Mach bands, and perception is modified by projection, contour, and film and object density (Berry *et al.*, 1983).

Dental papilla bounded by its bony crypt

At the end of a developing tooth root, the pulp canal diverges, and the walls of the root rapidly taper to a knife edge. In the recess formed by the root walls and extending a short distance

beyond is a small, rounded, radiolucent area in the trabecular bone, surrounded by a thin layer of hyperostotic bone.



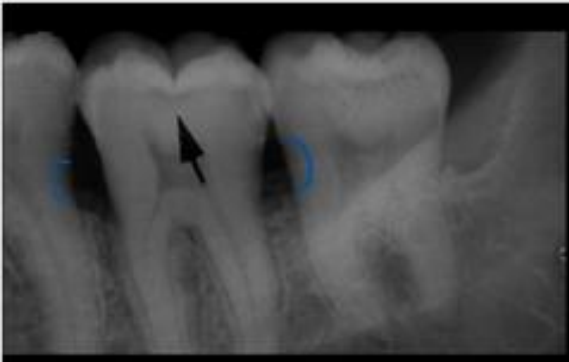Cervical Burn Out

This is the dental papilla bounded by its bony crypt. The papilla forms the dentin and the primordium of the pulp. When the tooth reaches maturity, the pulpal walls in the apical region begin to constrict and finally come into close apposition. Awareness of this sequence and its radiographic pattern is often useful in evaluating the stage of maturation of the

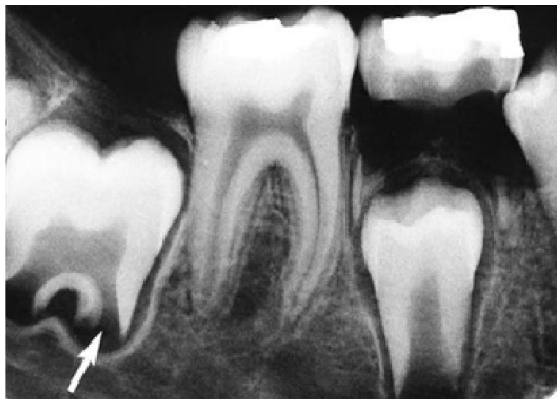*Corresponding author: Karthik,

Department of Oral Medicine and Radiology, Vinayaka Missions Sankarachariyar Dental College, Salem.

developing tooth; it also helps avoid misidentifying the apical radiolucency as a periapical lesion (Berkovitz *et al.*, 2009).



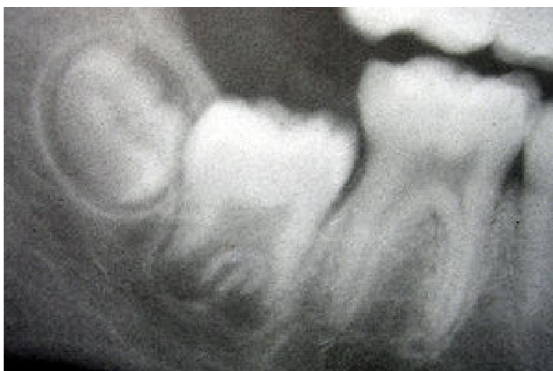Mach Band Effect



Follicular space

Follicular Space

In the Intraoral Periapical radiograph , the Follicular space generally appears as a radiolucent halo surrounding the crown of the developing tooth. The width of the radiolucent space surrounding the crown of the developing tooth is usually 3mm. More than this normal follicular space suggestive of a pathology such as a circumferential Dentigerous cyst (Berkovitz *et al.*, 2009).

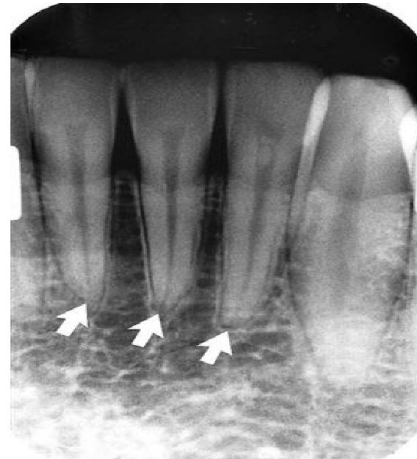

Follicular Space

Apical Foramen

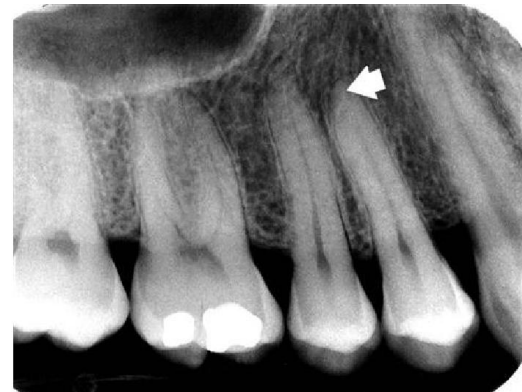In normal, fully formed teeth, the root canal may be apparent, extending from the pulp chamber to the apex of the root. An

apical foramen is usually recognizable at the apex of the teeth. In other normal teeth, the canal may appear constricted in the region of the apex and not discernible in the last 1 mm or so of its length.



Apical Foramen

In this case, the canal may occasionally exit on the side of the tooth, just short of the radiographic apex. Lateral canals may occur as branches of an otherwise normal root canal. They may extend to the apex and end in a normal, discernible foramen or may exit the side of the root. In either case, two or more terminal foramina might cause endodontic treatment to fail if they are not identified.

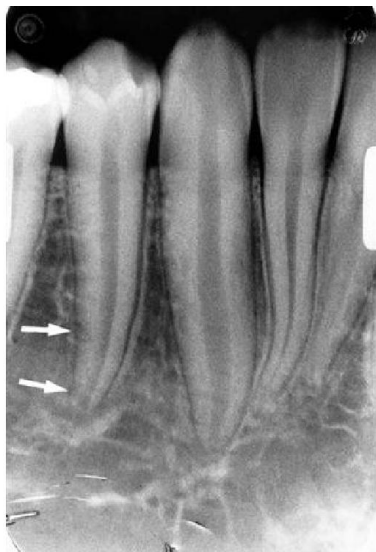

Apical foramen

Lamina Dura

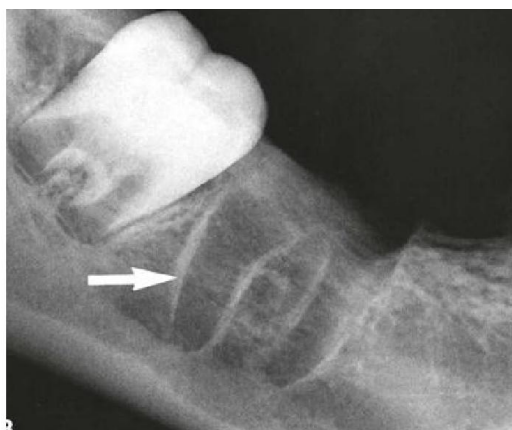The appearance of the lamina dura is a valuable diagnostic feature. The presence of an intact lamina dura around the apex of a tooth strongly suggests a vital pulp. However, because of the variable appearance of the lamina dura, the absence of its image around an apex on a radiograph may be normal. Rarely, the lamina dura may be absent from a molar root extending into the maxillary sinus in the absence of disease. Therefore, the clinician is advised to consider other signs and symptoms as well as the integrity of the lamina dura when establishing a diagnosis and treatment. The appearance of the lamina dura on radiographs may vary. When the x-ray beam is directed through a relatively long expanse of the structure, the lamina dura appears radiopaque and well defined. When the beam is directed more obliquely, the lamina dura appears more diffuse

and may not be discernible. In fact, even if the supporting bone in a healthy arch is intact, identification of a lamina dura completely surrounding every root on each film is frequently difficult, although it usually is evident to some extent about the roots on each film.



Disruption of Lamina Dura

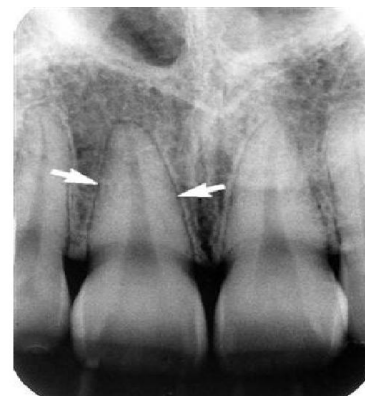Small variations and disruptions in the continuity of the lamina dura may result from superimpositions of cancellous bone and small nutrient canals passing from the marrow spaces to the periodontal ligament (PDL). The thickness and density of the lamina dura on the radiograph vary with the amount of occlusal stress to which the tooth is subjected. The lamina dura is wider and more dense around the roots of teeth in heavy occlusion and thinner and less dense around teeth not subjected to occlusal function. Presence of an intact lamina dura lining the extracted alveolar socket, suggestive of recently extraction socket.



Lamina dura around a Recently extraction socket

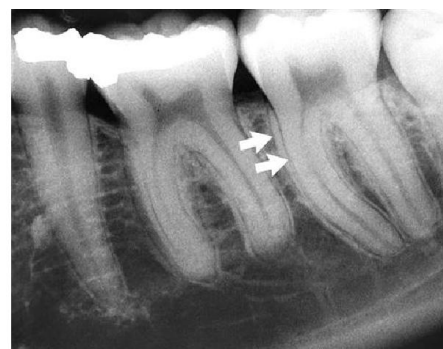Periodontal Ligamentspace (PDL space)

Because the Periodontal ligament (PDL) is composed primarily of collagen, it appears as a radiolucent space between the tooth root and the lamina dura. This space begins at the alveolar crest, extends around the portions of the tooth roots within the alveolus, and returns to the alveolar crest on the opposite side of the tooth.



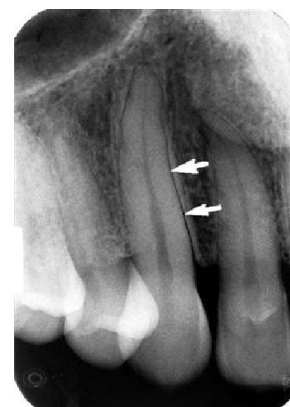PDL Space

When the x-ray beam is directed so that two convexities of a root surface appear on a film, a double PDL space is seen. A common example of this double PDL space is seen on the buccal and lingual eminences on the mesial surface of mandibular first and second molar roots.



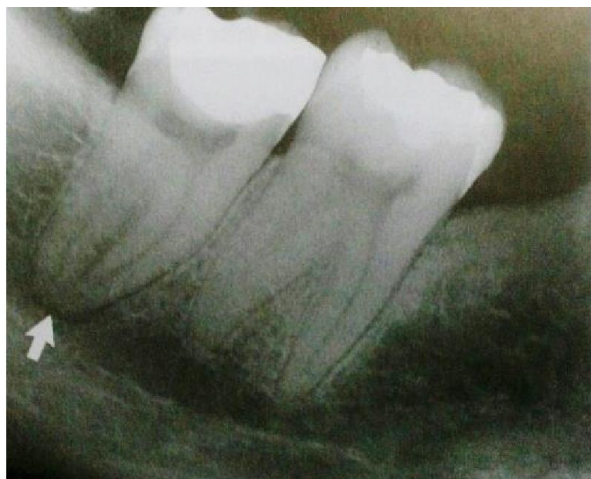Double PDL Space

The PDL varies in width from patient to patient, from tooth to tooth in the individual, and even from location to location around one tooth . It is usually thinner in the middle of the root and slightly wider near the alveolar crest and root apex, suggesting that the fulcrum of physiologic movement is in the region where the PDL is thinnest. The thickness of the ligament relates to the degree of function because the PDL is thinnest around the roots of embedded teeth and teeth that have lost their antagonists. The reverse is not true, however, because an appreciably wider space is not regularly observed in persons with especially heavy occlusion or bruxism.



Double PDL Space

Sometimes superimposition of the inferior alveolar canal over the apex of mandibular molar root causes the radiographic image of the Periodontal ligament space of that Particular tooth to appear wider suggesting a pathology of Apical Periodontitis. In such cases the presence of an intact lamina dura must be looked for which indicates there is no periapical disease (Terzic *et al.*, 2013 and Claeys *et al.*, 2005).

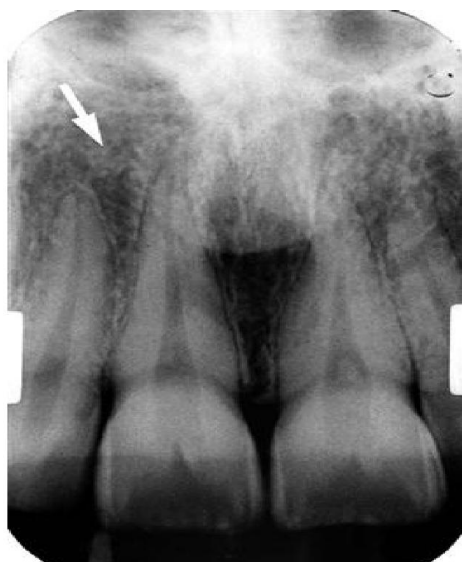

Superimposition of Inferior alveolar canal over root apex mimicking a apical periodontitis

Trabecular bone marrow pattern

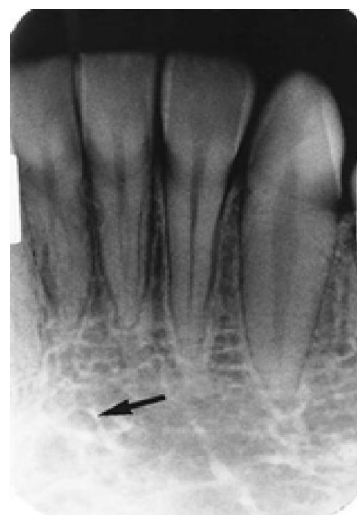To evaluate the trabecular pattern in a specific area, the practitioner should examine the trabecular distribution, size, and density and compare them throughout both jaws and especially with the corresponding region on the opposite side.

This comparison frequently demonstrates that a particularly suspect region is characteristic for the individual.



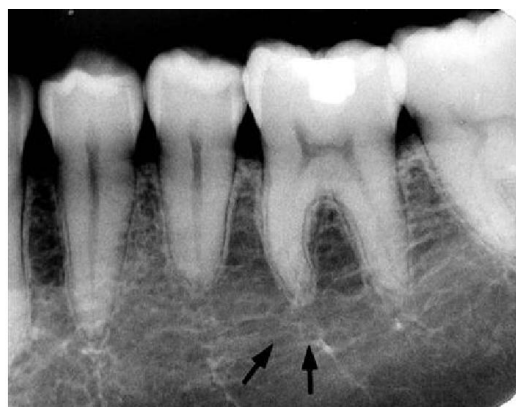Normal Trabecular Bone Pattern in Anterior Maxilla

The trabecular pattern in the anterior mandible is characterized by coarser trabecular plates (arrow) and larger marrow spaces than in the anterior maxilla.



Normal trabecular bone pattern in anterior mandible

The trabecular pattern in the posterior mandible is quite variable, generally showing large marrow spaces and sparse trabeculation, especially inferiorly

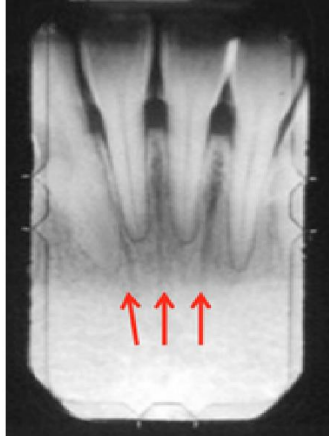


Normal trabecular bone pattern in posterior mandible

If trabeculae are apparently absent, suggesting the presence of disease, it is often revealing to examine previous radiographs of the region in question. This helps determine whether the current appearance represents a change from a prior condition. An abnormality is more likely when the comparison indicates a change in the trabecular pattern. If prior films are unavailable, it is frequently useful to repeat the radiographic examination at a reduced exposure because this often demonstrates the presence of an expected but sparse trabecular pattern that was overexposed and burned out in the initial projection (Mraiwa, 2003). Finally, if prior films are unavailable and reduced exposure does not allay the examiner’s apprehension, it may be appropriate to expose another radiograph at a later time to monitor for ominous changes. Considerable variation may exist in trabecular patterns among patients, so examining all regions of the jaws is important in evaluating a trabecular pattern for any individual. This examination enables the dentist to determine the general nature of the particular pattern and whether any areas deviate appreciably from that norm. The buccal and lingual cortical plates of the mandible and maxilla do not cast a discernible image on periapical radiographs (Mraiwa *et al.*, 2003).

Nutrient Canals

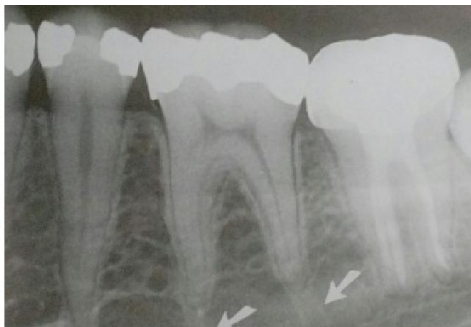
Nutrient canals carry a neurovascular bundle and appears as radiolucent lines of fairly uniform width. They are most commonly seen on mandibular periapical radiographs running vertically from the inferior dental canal directly to the apex of a tooth into the interdental space between the mandibular incisors. They are visible in 5-40 % of all patients and more frequent in Black, male, older Patients and Hypertensive patients, Diabetes Mellitus or advanced Periodontal disease. They also indicate a thin ridge useful in Implant assessment.



Nutrient Canals

Because they are anatomic spaces with walls of cortical bone, their images occasionally have Hyperostotic borders. Nutrient canals may also appear as radiopaque cortical borders that descend from the apex of the roots of Mandibular first molar.⁴

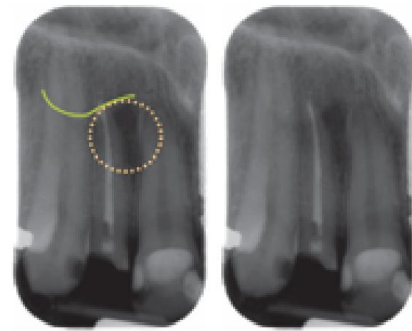
Nutrient canals in a Mandibular first molar



Sometimes a Nutrient canals is oriented Perpendicular to the cortex and appears as a small round radiolucency simulating a Pathologic radiolucency.⁴

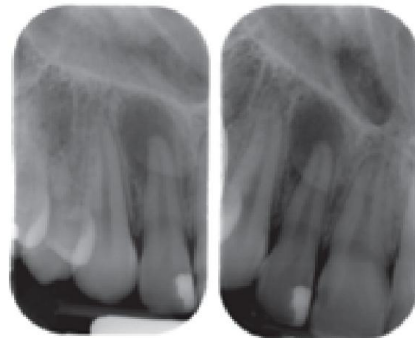
Incisive Fossa (Canine Fossa) (Lateral Fossa)

The incisive fossa is an area of thin bone located near the maxillary lateral incisors—is one of the most common anatomical appearances on radiographs that may mimic as a Periapicallesion. The incisive fossa presents as a decreased radiopacity of bone surrounding the lateral incisor roots. Frequently, the soft tissue of the nose is superimposed over or apical to the apex of the lateral incisor root, making the fossa appear radiolucent than more surrounding bone.⁴



Lateral fossa

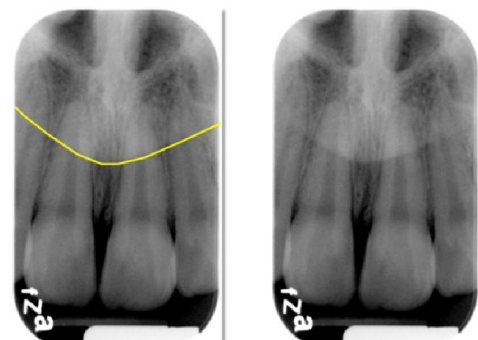
Ensuring this radiolucent area is normal anatomy necessitates careful evaluation of the periodontal ligament space and lamina dura around the lateral incisor root. If both are intact around the entire tooth, the diffuse radiolucent area is the incisive fossa. If there is a break in the lamina dura and/or periodontal ligament space that is continuous with a well-defined radiolucent area, a disease process associated with the tooth is likely. Further tests are recommended like Pulp vitality tests like Heat test using Heated Guttapercha sticks or any other Pulp vitality tests using Electronic Pulp tester.⁴A SLOB technique (Clarks /Tube-shift Technique) helps to clearly delineate any Periapical Pathology if Present.



Soft tissue shadow of the ala of the nose

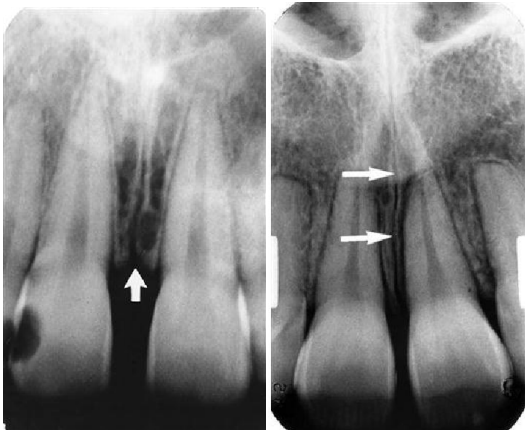
The soft tissue of the nose appears as a radiopaque area superimposed over the maxillary anterior teeth. The tip of the nose is seen over the maxillary central incisors. The ala of the nose is seen over the Maxillary lateral incisors. This can be misdiagnosed as root fracture of Maxillary anterior teeth (Kasle, 1994)

Soft tissue shadow of the ala of the nose



Intermaxillary Suture

The intermaxillary suture (also called the median suture) appears on intraoral periapical radiographs as a thin radiolucent line in the midline between the two portions of the premaxilla. It extends from the alveolar crest between the central incisors superiorly through the anterior nasal spine and continues posteriorly between the maxillary palatine processes to the posterior aspect of the hard palate. It is not unusual for this narrow radiolucent suture to terminate at the alveolar crest in a small rounded or V-shaped enlargement. The suture is limited by two parallel radiopaque borders of thin cortical bone on each side of the maxilla. The radiolucent region is usually of uniform width. The adjacent cortical margins may be either smooth or slightly irregular. The appearance of the intermaxillary suture depends on both anatomic variability and the angulation of the x-ray beam through the suture.⁴

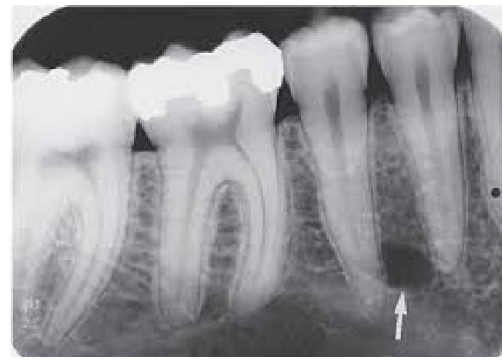

Intermaxillary suture

The intermaxillary suture may terminate in a V-shaped widening (arrow) at the alveolar crest. This is a normal variation and should not be confused with alveolar bone loss associated with periodontal disease.

Mental Foramen

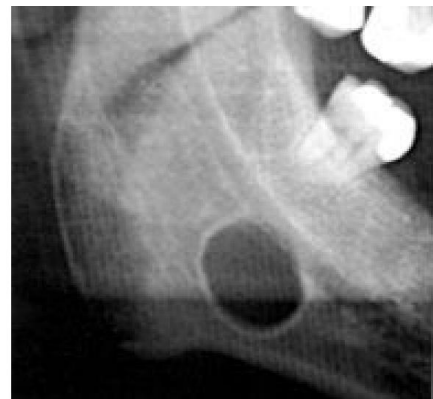The mental foramen is an opening of the mandibular canal on the facial aspect of the mandible. It appears as a round-to-ovoid, radiolucent entity. In some patients, the mental foramen will be superimposed over the root of the second premolar and may mimic pathosis. Evaluation of the lamina dura and periodontal ligament space is crucial for correct interpretation. Also a tubeshift technique (Clarks technique) (SLOB Technique) (SLOB Same side = Lingual, Opposite side =Buccal) helps to identify whether it is a mental foramen or any other Pathology. In SLOB technique a first radiograph is taken with normal angulation after which a second radiograph is taken by either moving the Position indicating device (Cone) of the IOPA tube either mesially or distally. The radiographic image of the second is compared with the radiographic image of the first. If the position of the radiolucent area moves towards the same side or away from the radiographic image of the first, then it is considered as a pathology whereas a normal anatomical landmark will remain in the same position whether the PID is moved mesially or distally.⁴



Mental Foramen

Developmental lingual submandibular salivary gland depression (Stafne cyst)

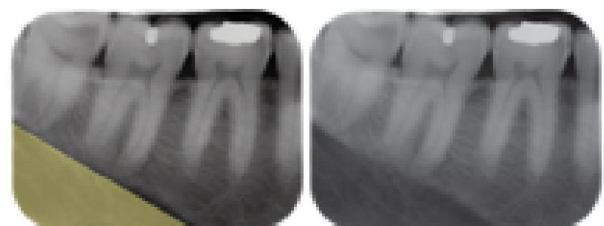
The submandibular salivary gland depression(stafne cyst) (Static Bone cavity) is a normal anatomical landmark where the mandible narrows facial-lingually inferior to the mandibular molars to accommodate the submandibular salivary gland. Radiographically it appears as a well-localized, radiolucent area apical to the mandibular molars below the level of superior border of inferior alveolar canal and inferior to the lower border of the mandible mimicking a cyst. It is a Pseudocyst since it has no epithelial lining.⁴



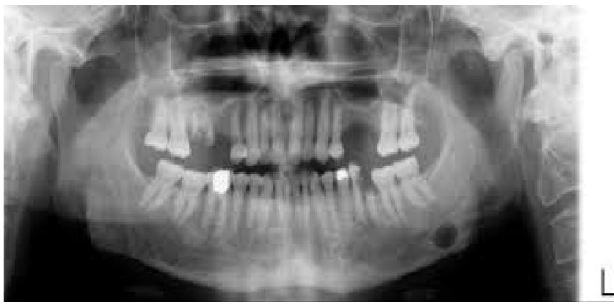
Stafne Cyst

The well-localized radiolucent area of the submandibular salivary gland depression (yellow triangle) is seen occasionally in the following Intraoral periapical radiograph. The thick radiopaque superior border is the mylohyoid ridge.⁴

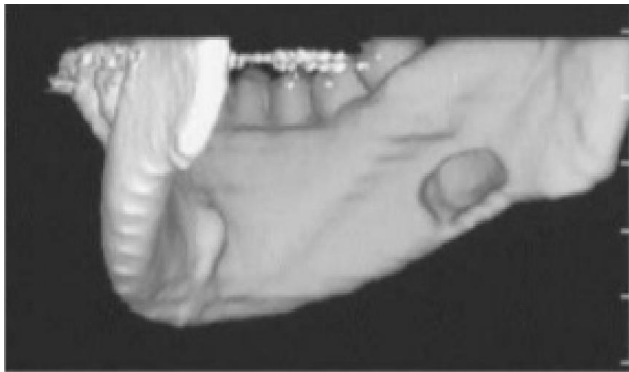
IOPA revealing a stafne cyst



On a pantomograph, the area may appear more radiolucent due to adjacent radiopaque areas created by the imaging.



OPG revealing a stafne cyst

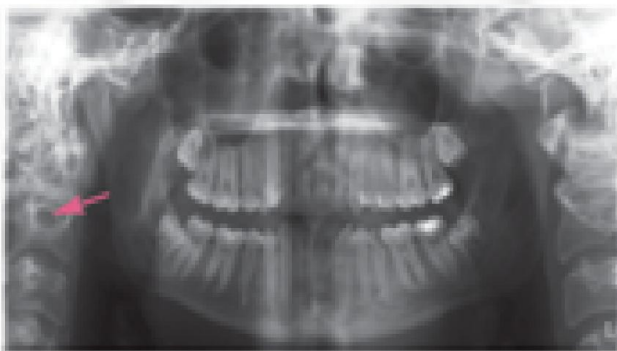


Stafne cyst in a 3D reconstruction image of CT scan

Canals of the vertebral artery

In all panoramic images, clinicians should be aware of the canals of the vertebral artery. They bilaterally and vertically ascend through the transverse foramina of the vertebral bodies before turning to enter the foramen magnum. This canals of the vertebral artery can be mistaken for multiple myeloma with its round, well defined, almost punched out appearing radiolucency in the cervical spine, usually seen at the C2 to C3 level (Terzic *et al.*, 2013).

Canals of the Vertebral Artery

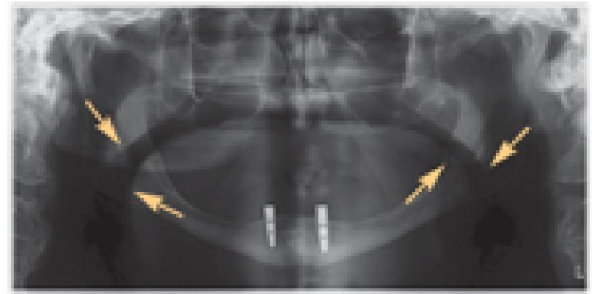
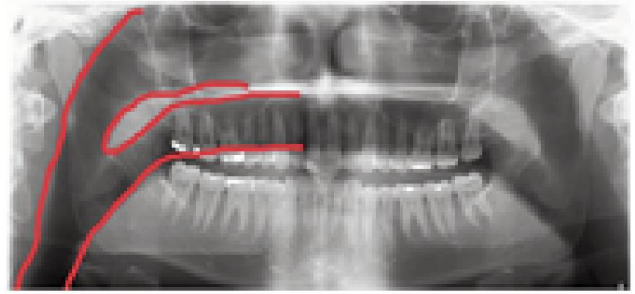


Airways (Kasle, 1994)

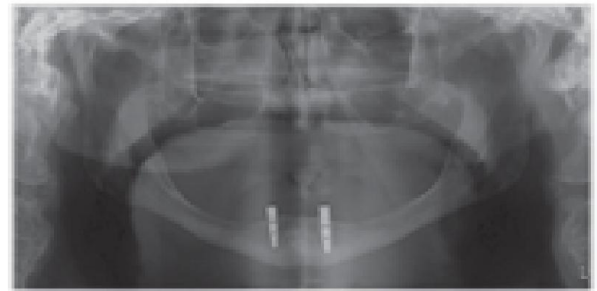
The airway is generally seen on pantomographs that are superimposed over the ramus of the mandible.

Sometimes, the airway appears radiolucent, causing the angle of the mandible to look "burned out." Burn out should not be confused with pathosis or mandibular fracture.

OPG showing AIRWAYS



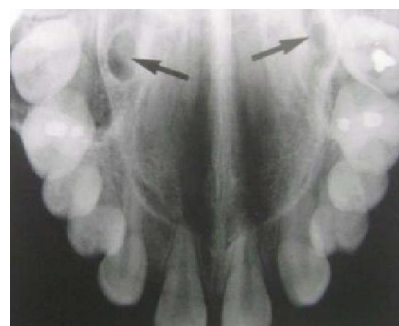
To correct this, another pantomograph should be made using a lower peak kilovoltage (kVp) and milliamperage (mA) setting—purposefully underexposing the patient to produce a lighter image.



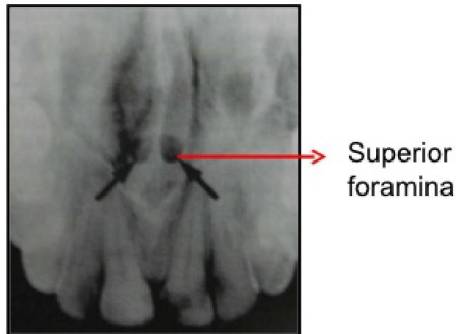
Nasolacrimal Canal⁴

The Nasolacrimal canal can be seen occasionally in relation to maxillary canine region in IntraoralPeriapical radiographs due to the steeper vertical angulation of Positioning Indicating device (PID). The Nasolacrimal canal is usually seen in Maxillary occlusal radiograph in the molar region is usually mistaken for Greater Palatine foramen.

Maxillary occlusal radiograph showing a nasolacrimal canal

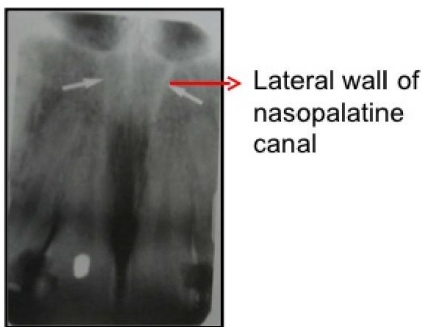

Radiographically the nasopalatine canal can also be recognized as two radiolucent areas above the apices of Maxillary central incisors near the floor of the nasal cavity on either side of the nasal septum which can be misdiagnosed as a Pathology.



Superior foramina

The Lateral wall of the Nasopalatine canal appears as a vertical radiopaque line in relation to the apices of roots of Maxillary central incisors.



Lateral wall of nasopalatine canal

Lateral wall of nasopalatine canal

REFERENCES

- Berkovitz, K.B., Holland, G. R, Moxham, B. L 2009. *Oralanatomy, Histology and Embryology*, ed4, London, 2009, Mosby.
- Berry H.M Jr, Cervical burnout and Mach band: two shadows of doubt in radiologic interpretation of carious lesions, *Journal of American Dental Association*, 1983 May;106(5):622-5.
- Claeys, V., Waskens, G. 2005. Bifid mandibular canal : Literature review and case report, *Dentomaxillofacial Radiology* 34:55-58.
- Kasle, M.J. 1994. *An atlas of dental radiographic anatomy*, ed4, Philadelphia. Saunders.
- Mraiwa, N., Jacobs, R., VanSteenberghe, D. *et al.* 2003. Clinical implications and Surgical implications of anatomic challenges in anterior mandible, *Clin Implant Dent Relat Res* 5:219-225.
- Stuart., C. White, Michael. *J. Pharoah, Oral Radiology, Principles and Interpretation*, Elsevier Publications, First South Asia Edition, ISBN:978-81-312-3883-7.
- Terzic, A., Becker, M., Imholz, B. *et al*, Unilateral widening of Inferior alveolar nerve canal :a rare anatomical variant mimicking disease, *Oral Radiol* (2013) 29: 160. doi:10.1007/s11282-012-0118-9.
