



## CASE STUDY

### PRESENTATION OF CHOLEDOCHAL CYST WITH PORTAL HYPERTENSION

**\*Dr. Usha Vaswani, Dr. Sudhir Bhamre, Dr. Mandar Vaidya and Dr. Anita Gangurde**

Dr.Vasantrao Pawar Medical College & Hospital and Research Centre, Nasik

#### ARTICLE INFO

##### Article History:

Received 15<sup>th</sup> April, 2016  
Received in revised form  
27<sup>th</sup> May, 2016  
Accepted 27<sup>th</sup> June, 2016  
Published online 16<sup>th</sup> July, 2016

##### Key words:

Choledochal cyst,  
Cholecystectomy,  
roux-en-Y hepaticojejunostomy.

#### ABSTRACT

Choledochal cyst is a rare disease of the biliary tract. Historically, choledochal cyst disease was considered as a disease of childhood but is increasingly being recognised in adults. The optimal and definitive treatment used today is the complete excision of the extrahepatic duct, cholecystectomy and roux-en-Y hepaticojejunostomy due to high morbidity and high risk for carcinoma associated with internal drainage, a commonly used treatment in the past. We report a case of 14 year old male patient with markedly dilated tortuous CBD with marked splenomegaly and portal hypertension. The treatment of Choledochal cyst complicated by portal hypertension has evolved from internal drainage of cyst to single stage excision of cyst with bilioenteric anastomosis. Portal decompression is reserved for cases with extensive collaterals

Copyright©2016, Dr. Usha Vaswani et al. This is an open access article distributed under the Creative Commons Attribution License, which permits unrestricted use, distribution, and reproduction in any medium, provided the original work is properly cited.

Citation: Dr. Usha Vaswani, Dr. Sudhir Bhamre, Dr. Mandar Vaidya and Dr. Anita Gangurde, 2016. "Presentation of Choledochal cyst with portal hypertension", *International Journal of Current Research*, 8, (07), 34331-34333.

## INTRODUCTION

Choledochal cyst is predominantly a disease of childhood. Choledochal cyst are uncommon congenital anomalies of bile duct with incidence of 1 in 100000-150000 live births in western population but incidence is higher in Asian population with a incidence of 1 in 1000 (Lipsett *et al.*, 1994). It has a female to male preponderance 4:1 (Wiseman *et al.*, 2005). 25 % of patients are initially seen as adults (Liu *et al.*, 2002). The etiopathogenesis of this disease is still unclear; however the most common proposed theory for choledochal cyst is pancreaticobiliary maljunction. The incidence of biliary tract cancer increases with age in these patients. These cysts are commonly associated with Hepatobiliary complications with pulmonary hypertension reported as one of its rare complications. The optimal and definitive treatment used today is the complete excision of the extrahepatic duct, cholecystectomy and roux-en-Y hepaticojejunostomy

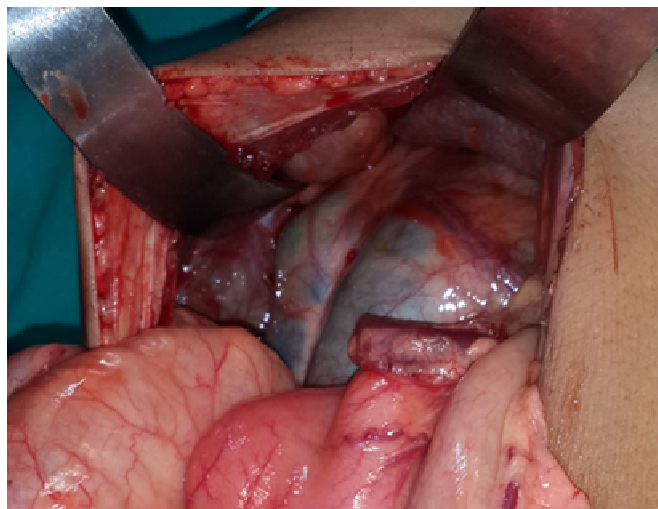
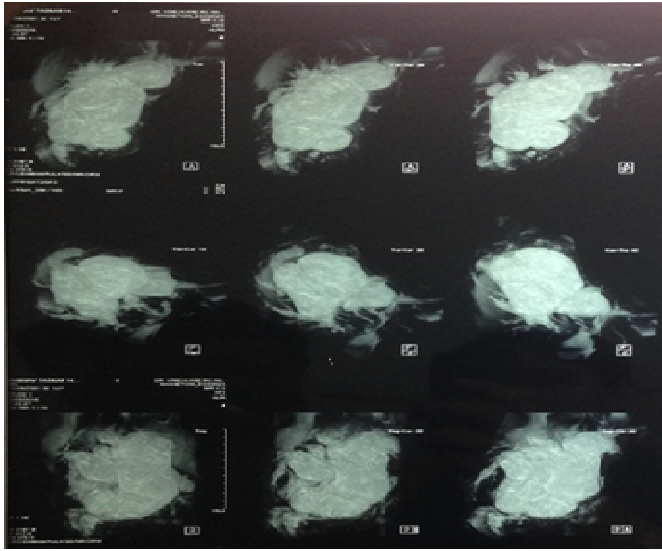
### Case report

A 14 year old male patient admitted to surgery department of Dr.Vasantrao Pawar Medical College Nasik presented with pain in abdomen over the right hypochondrium, jaundice and distension of abdomen since 10-12 days. He also gives history

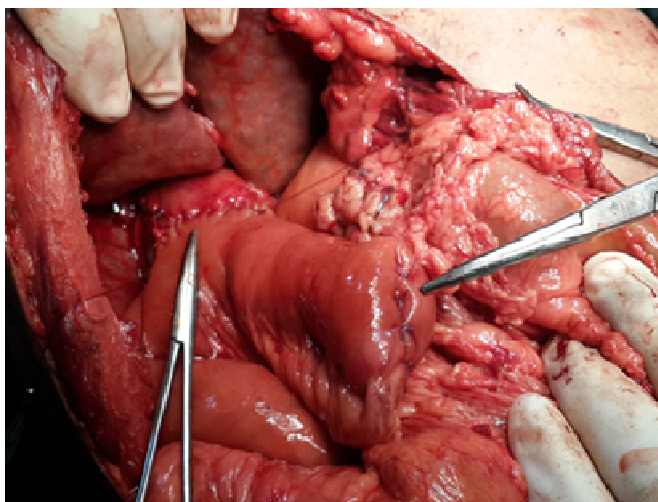
of pruritis and passing clay coloured stools since last 10-12 days. No history of hematemesis, melena, pancreatitis. Past history of recurrent jaundice and pain in abdomen on and off. On examination lump palpable per abdomen over left hypochondrium 3cm below costal margin. On biochemical investigations haemoglobin was 9.3g/dl; total serum bilirubin 9mg/dl; direct serum bilirubin 3.2mg/dl; serum SGOT 122U/L; serum SGPT 136 U/L. Viral markers for hepatitis B and hepatitis C were negative. Abdominal sonography showed a marked dilatation of intrahepatic biliary radicals, a cystic tortuous tubular structure measuring approximately 3-4 cm in diameter seen in right subhepatic region, few small 3-4mm sized calculi seen within, possibility of choledochal cyst ?Enlarged portal vein, mildascitesand severe splenomegaly. CT scan Abdomen and pelvis showed tubular tortuous cystic structure seen along subhepatic region along the course of CBD, marked dilated biliary radicals, GB distended, normal pancreas, enlarged spleen, dilated and tortuous portal vein (13mm), ascites. On further investigating the patient, magnetic resonance cholangiopancreatography (MRCP) showed a markedly dilated tortuous CBD(maximum diameter of 4.6cm) with moderate dilatation of IHBR—possibility of choledochal cyst, few small calculi seen in dilated distal CBD, gall bladder appears normal, no dilatation of pancreatic duct, marked splenomegaly, ascites. Upper Gastrointestinal endoscopy revealed grade one oesophageal varices.

\*Corresponding author: Dr. Usha Vaswani,

Dr.Vasantrao Pawar Medical College & Hospital and Research Centre, Nasik.



[Magnetic resonance cholangiopancreatographic findings and Intra-operative findings]



A Pre-operative diagnosis of choledochal cyst with splenomegaly with portal hypertension was made and Roux-en-Y hepaticojejunostomy with liver biopsy was done. Intra-operative findings - Large tense choledochal cyst with extensive collaterals with dilatation of hepatic ducts was noted

and complete excision of extrahepatic duct with cholecystectomy with roux-en-Y Hepaticojejunostomy and ligation of portal collaterals was done. Post-operative period was uneventful and histopathological examination was suggestive of choledochal cyst with liver cirrhosis. On follow up after 2 months patient developed ascites and deranged LFT's, total serum bilirubin 12 mg/dl.

## DISCUSSION

Choledochal cysts are rare abnormalities of the biliary tree and so may be overlooked in differential diagnosis. Early detection and treatment of choledochal cyst is an important factor in overall occurrence of cholangiocarcinoma. It can lead to significant morbidity and mortality if not treated promptly. Portal hypertension is a rare condition that complicates the management of choledochal cysts (JanakieSingham *et al.*, 2010). Its clinical manifestations are hepatosplenomegaly, jaundice, hematemesis, melena or ascites. Causes of portal hypertension include extra hepatic biliary obstruction leading to secondary biliary cirrhosis, recurrent inflammation leading to portal vein thrombosis, direct compression of the portal vein, congenital hepatic fibrosis in Caroli's disease and other unrelated etiologies of cirrhosis. Direct compression of the portal vein is reported as the main mechanism in children. Successful decompression of the choledochal cyst leads to satisfactory relief of the portal hypertension (Martin and Rowe, 1979). Portal decompression is required before biliary reconstruction in presence of portal vein thrombosis and collaterals along hepatoduodenal ligament. If there is evidence of pericystic varices, portosystemic shunting can be performed for decompression before surgery (JanakieSingham *et al.*, 2010). Diffuse disease with recurrent or life threatening cholangitis, liver failure, cirrhosis and portal hypertension or malignant disease requires orthotopic liver transplantation (Saluja *et al.*, 2011). In patients with child class C status a shunt may deteriorate liver function and hence liver transplant is considered in such patients (JanakieSingham *et al.*, 2010). Historically management of choledochal cyst consisted of various drainage operations but high complication rates and threat of malignancy have changed the treatment protocol. The current treatment of choice is excision of cyst with roux-en-Y hepaticojejunostomy and cholecystectomy to reduce the risk of bile duct and gall bladder cancer. Our follow up in this patient consists of yearly LFT's and evaluation of new symptoms, but not yearly imaging.

## Conclusion

Treatment of choledochal cyst complicated by portal hypertension has evolved over the years from internal drainage to single stage excision. At present, Cystectomy with Roux-en-Y hepaticojejunostomy is procedure of choice in such patients. Portal decompression is reserved for cases with extensive collaterals.

## REFERENCES

- JanakieSingham, Eric M. Yoshida, Charles H. Scudamore. 2010. Choledochal cysts. *Can j Surg*, Vol.53, no1, February.

- Lipsett PA, Pit HA, Colombani PM, *et al.* 1994. Choledochal cyst disease. A changing pattern of presentation. *Ann Surg.*, 220:644-652.
- Liu CL, Fan ST, Lo CM, Lam CM, Poon RT, Wang J. 2002. Choledochal cysts in adults. *Arch Surg.*, 137:465-468.
- Martin W. and Rowe GA. 1979. Portal hypertension secondary to choledochal cysts. *Ann Surg.*, 190(5):638-9.
- O'Neill JA Jr. 1992. Choledochal cyst. *CurrProblSurg.*, 29:361-410.
- Saluja SS, Mishra PK, Sharma BC, Narang P. 2011. Management of choledochal cyst with portal hypertension. *Singapore Med J.*, 52(12):e239-43.
- Suita S, Shono K, Kinugasa Y, Kubota M, Matsuo S. 1999. Influence of age on the presentation and outcome of choledochal cyst. *J Pediatr Surg.*, 34:1765-8.
- Todani T, Watanabe Y, Narusue M, Tabuchi K, Okajima K. 1977. Congenital bile duct cysts; classification, operative procedures, and review of thirty seven cases including cancer arising from choledochal cyst. *Am J Surg.*, 134; 263-269.
- Wiseman K, Buczkowski AK, Chung SW, Francoeur J, Scudamore CH. 2005. Epidemiology, Presentation, diagnosis and outcomes of choledochal cysts in adults in an urban environment. *Am J Surg.*, 189:527-531.

\*\*\*\*\*