



RESEARCH ARTICLE

DIAGNOSTIC COMPARISON OF TWO STAINING TECHNIQUES IN SPUTUM SAMPLES OF PULMONARY TUBERCULOSIS CASES

*Dr. Deepa Pandey, Dr. C. P. Baveja, Dr. Vinay Kamal and Dr. H. S. Hira

¹Department of Microbiology, Central Hospital, DLW, Varanasi, Uttar Pradesh -221004, India

²Department of Microbiology, Maulana Azad Medical College and Lok Nayak Jai Prakash Hospital, Bahadur Shah Zafar Marg, New Delhi-110002

³Department of Pathology, Maulana Azad Medical College and Lok Nayak Jai Prakash Hospital, Bahadur Shah Zafar Marg, New Delhi-110002

⁴Department of Pulmonary Medicine, Maulana Azad Medical College and Lok Nayak Jai Prakash Hospital, Bahadur Shah Zafar Marg, New Delhi-110002

ARTICLE INFO

Article History:

Received 24th March, 2016

Received in revised form

17th April, 2016

Accepted 28th May, 2016

Published online 15th June, 2016

Key words:

Sputum,
NaLC-NaOH decontamination,
ZN, AO staining.

ABSTRACT

Background: Smear microscopy remains the cornerstone for the diagnosis, treatment initiation; follow up of Pulmonary Tuberculosis (PTB) in high burden countries like India.

Aim of the study: The objective of this study was to compare the diagnostic efficacy of Ziehl Neelsen (ZN) and Fluorescent Auramine O (AO) staining for the detection of *Mycobacterium tuberculosis* before and after sputum decontamination.

Material and Methods: Fifty cases (n=50) of clinically diagnosed pulmonary tuberculosis were included in the study. Sputum smears were stained by ZN and AO stain both before and after decontamination by NaLC-NaOH method.

Result: Smear positivity rate was 76% by ZN staining before decontamination and it increased to 96% after decontamination. However, AO staining sensitivity was 100% both before and after decontamination.

Conclusion: AO staining is highly sensitive than ZN staining in detecting even paucibacillary cases even in direct sputum smears. Sputum decontamination improves the diagnostic efficacy of sputum smears.

Copyright©2016, Dr. Deepa Pandey et al. This is an open access article distributed under the Creative Commons Attribution License, which permits unrestricted use, distribution, and reproduction in any medium, provided the original work is properly cited.

Citation: Dr. Deepa Pandey, Dr. C.P. Baveja, Dr. Vinay Kamal and Dr. HS Hira, 2016. "Diagnostic comparison of two staining techniques in sputum samples of pulmonary tuberculosis cases", *International Journal of Current Research*, 8, (06), 32644-32648.

INTRODUCTION

Despite recent advances, the smear microscopy remains the cornerstone for the diagnosis of PTB (Pulmonary Tuberculosis) in high burden countries like India (Tiwari, 2015). WHO also recommends sputum microscopy examination in the diagnosis of PTB (WHO, 2009). One sputum positive patient can infect 10–15 persons in a year if left untreated (TB India, 2008). Early detection and initiation of treatment is necessary to prevent its spread. Longer culture period demands good and preliminary laboratory technique which at present is "Staining". Staining which is highly sensitive, quantitative, low cost, user friendly can be conducted in large scale, even in field conditions is the need of hour for this bacilli.

Thus, direct microscopic examination of acid fast bacilli (AFB) is the microbiological method used for diagnosis and preliminary confirmation of tuberculosis (TB) and also defines the more infectious cases in positive smears in grading (quantitation scale) (Masood, 2008).

Under RNTCP, sputum smear examinations play an important role in treatment initiation, follow up and treatment completion. Nowadays, fluorescent microscopy has also been introduced at the microscopy centres for diagnosis thus increasing the detection rates. Presence of mycolic acids in the mycobacterial cell wall necessitates the need for special stains and techniques. Ziehl Neelsen (ZN) and Auramine O (AO) staining were done on the sputum smears in this study and their diagnostic efficacy for the detection of *Mycobacterium tuberculosis* before and after sputum decontamination was compared.

*Corresponding author: Dr. Deepa Pandey,
Department of Microbiology, Central Hospital, DLW, Varanasi, Uttar Pradesh -221004, India.

MATERIALS AND METHODS

This study was carried out in the Department of Microbiology; Department of Pulmonary Medicine from 2009-2010. Ethical committee approval was taken prior to commencing the study. Fifty cases (n=50) of clinically diagnosed pulmonary tuberculosis attending chest clinic were included in the study. Morning sputum samples were collected preferably early morning in wide mouthed, sterile, labelled plastic container. New, clean and unscratched slides were used for making smears. Using a sterile bacteriological loop two sputum smears were prepared before and after decontamination. Before decontamination, smears were preferably made from the cheesy, necrotic, blood tinged (if present) part of the sputum. The loop was sterilized in Bunsen burner after making every smear. The material was spread over approximately 1 x 2 cm area of clean grease free glass slide, air dried and heat fixed by passing through the flame three or four times. Adequate fixing was tested by feeling the slide on the back of the palm. With both the staining procedures, known positive and negative smears were also stained on the same slide for the quality control. Both staining procedures were done according to the standard protocol. In ZN staining, at least 300 fields under oil-immersion objective were observed before declaring the slide as negative. The bacilli appeared red, slender and beaded rods (Figure 1). Smears stained with Auramine 'O' fluorescent stain showed bacilli as slender bright yellow fluorescent rods, standing out clearly against a dark background (Figure 2).

Ziehl-neelsen staining Method (Kent, 1985)

Preparation of carbol fuchsin (0.3 gm of basic fuchsin was dissolved in 10 ml of 95% ethyl alcohol (solution A). 5gm of phenol crystals were dissolved in 100 ml of water by gentle heating (solution B). Solution A was mixed with 90 ml of solution B), Preparation of acid alcohol (3 ml concentrated hydrochloric acid (HCl) was added to 97ml of 95% ethyl alcohol and mixed gently), Methylene blue was used as counterstain (0.3 gm of methylene blue was dissolved in 100 ml distilled water). The carbol fuchsin was poured on the slide covering the smear. Undersurface of the slide was heated intermittently for 5 to 10 minutes with the help of spirit lamp, until steam arose. Care was taken to prevent drying and boiling out of stain by adding more carbol fuchsin over the smear. The slide was then washed with water and decolorized using acid alcohol. Slide was again washed with tap water. Smear was counterstained with methylene blue for 1-2 min and washed with tap water. It was then air dried and observed under oil immersion lens (1000X). Acid fast bacilli (AFB) were seen as red, beaded and slightly curved rod against a bluish background. The smears were then graded depending on the bacilli observed under 1000X magnification (None- no AFB seen, 1-2/300 fields +, 1-9/100 fields - 1+, 1-9/10 fields - 2+, 1-9/ field - 3+, > 9/ field - 4+).

Fluorescent staining method

Preparation of Auramine O (0.1 gm of auramine O was dissolved in 10 ml of 95% ethanol (Solution A). 3gm of phenol crystals were dissolved in 87 ml of distilled water (Solution B). Both solutions A and B were mixed together),

Preparation of acid alcohol (Carefully 0.5 ml of concentrated hydrochloric acid (HCl) was added to 100 ml of distilled water), Preparation of counter stain (0.5 gm of potassium permanganate (KMnO₄) was dissolved in 100 ml of distilled water). Auramine O was poured over the heat fixed smear and kept for 15 minutes and then washed with distilled water. Smear was decolorized with acid alcohol and allowed to destain for 2 minutes. And then washed. It was then counterstained with potassium permanganate for 2 minutes and was washed again and then air dried and examined under fluorescence microscope immediately. AO smears were observed by fluorescent microscope (blue filter, BG-12; 540-590 nm wave length) using 40x objective lens. In case of doubt in morphology under fluorescent microscope, the same smear was over-stained by ZN technique for confirmation. The smears were graded as per WHO manual 3+ =more than 100 AFB field after examination of 20 fields; 2+ =11-100 AFB per field after examination of 50 fields; 1+ =1-10 AFB per field after examination of 100 fields; doubtful = 1-3AFB per 100 fields; Negative = No AFB per 100 fields.

Digestion-Decontamination Method (N-Acetyl L-Cysteine-Sodium Hydroxide (NALC-NaOH))

The mucolytic agent, N-acetyl L-cysteine, used for rapid digestion of sputum, enables the decontaminating agent, sodium hydroxide, to be used at a lower final concentration (in sputum) of 1%. Since acetylcysteine loses activity rapidly in solution, the digestant was made fresh daily. Sodium citrate was included in the digestant mixture to bind the heavy metal ions that might be present in the specimen and could inactivate acetylcysteine. Both the sodium hydroxide and sodium citrate were mixed in amounts as shown in the table. To this N-acetyl L-cysteine in amounts (as shown in the Table 1) was added to make the required volume of digestant.

Table 1. Preparation of NaLC-NaOH

Volume of digestant needed (ml)	Mix indicated amounts (ml) of 4% NaOH	Mix indicated amounts (ml) of 2.9% Na Citrate 2H ₂ O	Add NALC (grams)
50	25	25	0.25
100	50	50	0.50
200	100	100	1.00
500	250	250	2.50
1000	500	500	5.00

Preparation of 0.067 M Phosphate buffer, pH 6.8.-Stock Solution A (9.47 gm of anhydrous Na₂HPO₄ was dissolved in 1 liter of distilled water), Stock Solution B- 9.07 gm of KH₂PO₄ was dissolved in 1 liter of distilled water. 50 ml of stock solution A was mixed with 50 ml of stock solution B and pH of the solution was checked with pH meter and is adjusted to 6.8. Solution A was added if pH of solution need to be increased to 6.8 and Solution B was added if pH needs to be reduced to reach up to 6.8. It was then sterilized by autoclaving and stored for use.

Procedure-10 ml or less of sputum sample was taken in 50 ml plastic centrifuge tube. Equal volume of NALC-NaOH solution was added to this plastic centrifuge tube and cap of the plastic tube was then tightened. The plastic tube was then

rotated to mix the contents for about 5 to 20 seconds per tube so that NALC-NaOH solution contacts all inside surfaces of the tube and then left to stand for 15 minutes at room temperature for decontamination. After 15 minutes, sterile phosphate buffer, pH 6.8, was added up to 50 ml mark. The cap was closed tightly. This minimized the continuing action of NaOH and also reduced the specific gravity of the specimen before centrifugation. The tube was then centrifuged at 3000 g for 15 minutes and the supernatant was discarded into the splash proof discarding can containing the disinfectant and tube was recapped. The sediment was then resuspended in phosphate buffer. It was then used for inoculating Lowenstein Jensen (LJ) medium and for preparing two smears, one for ZN staining and other for fluorescent staining.

RESULTS

In the present study, 44 % were males and 56% were females (n=50) ranging from 12 years to 70 years and the mean age was 26.74 years. Patients from all the age groups were included in the study. Age group (10-24 years) contained the maximum number of cases (30%). In the present study, the most common complaint was cough of more than three weeks duration seen in 49 (98%) cases, followed by fever in 45 (90%) cases, weight loss in 44 (88%) cases, anorexia in 42 (84%) cases, hemoptysis in 19 (38%) cases, breathlessness in 13 (26%) cases and chest pain in 4 (8%) cases. In our study, family history of tuberculosis was found in 4% cases, while there was no family history of tuberculosis in 96 % cases. An induration measuring more than 10 millimeter was taken as positive for tuberculin reactivity. Mantoux showed negative tuberculin reactivity in 38% of cases and positive tuberculin reactivity in 62% of cases. X-ray chest was suggestive of pulmonary tuberculosis in 45 cases. However no significant abnormality was seen in 5 cases. However these 5 cases had positive sputum smear on examination. In the present study, the smear positivity rate was 76% by ZN staining before decontamination and it increased to 96% after decontamination (Table 2 and 3). Out of 24% samples (n= 12) which were negative by ZN staining before decontamination, 20% samples (n= 10) became positive by ZN staining after decontamination.

Table 2: Comparison of ZN staining and AO staining before sputum decontamination.

Staining method		Ziehl Neelsen staining		Total
		(Before decontamination)		
		Positive	Negative	
Auramine O staining	Positive	38 (76%)	12 (24%)	50 (100%)
	Negative	0	0	0
Total		38 (76%)	12 (24%)	50 (100%)

However, 4% of the sputum samples (n= 2) remained negative by ZN staining even after decontamination. Two samples which were negative after decontamination by ZN staining were positive before decontamination. All the fifty samples were positive by fluorescent AO staining both before and after decontamination. Overall, all the fifty samples were positive by ZN staining either before decontamination or after decontamination. All the samples were positive by BaACTEC radiometric culture.

Table 3: Comparison of ZN staining and AO staining after sputum decontamination.

		Ziehl Neelsen staining		Total
		(After decontamination)		
		Positive	Negative	
Auramine O staining	Positive	48 (96%)	02 (4%)	50 (100%)
	Negative	0	0	0
Total		48 (96%)	02 (4%)	50 (100%)

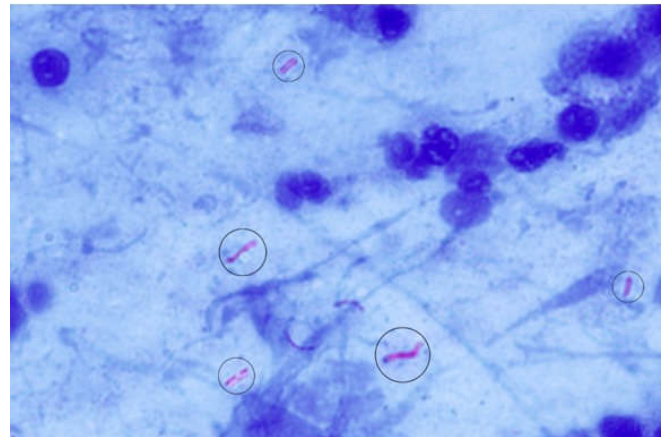


Fig. 1. Ziehl Neelsen Staining showing Acid Fast Bacilli (1000X)

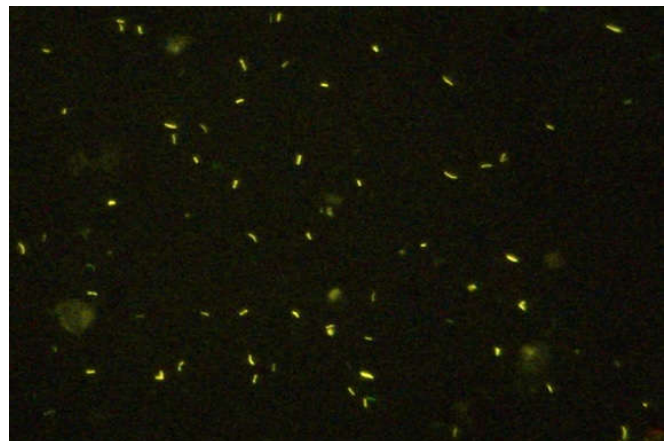


Fig. 2. Fluorescent staining of Acid Fast Bacilli by Auramine 'O'

Using culture as the reference method, the sensitivity of direct staining was 76 % for ZN and 100 % for AO. Direct fluorescent microscopy detected 24 % paucibacillary sputum samples that were missed on ZN staining. After concentration, the sensitivity increased by 20 % for ZN.

DISCUSSION

At present, TB is a notifiable disease. (Guidance for TB Notification in India, 2012) Being communicable and with the emergence of resistant strains, this disease demands much attention. This further necessitates the need for highly sensitive and specific test for early detection, initiation of treatment, regular follow up till treatment completion. Presence of mycolic acids in the mycobacterial cell wall necessitates the need for special stains and techniques. ZN staining is well known staining technique for this acid fast bacilli. Advantage of Auramine O technique is ease of screening slides at a lower

magnification covering larger area per unit of time thus reducing the observers fatigue with better results even in paucibacilliary cases. In this study, Fluorescent staining was found to be 100% sensitive than ZN staining even in direct sputum smears. This could be explained by the lesser sample size and specific population targeted for the study i.e. patients attending RNTCP clinic with typical signs and symptoms. Importantly, twelve paucibacilliary sputum samples which were missed on direct ZN staining were however detected by direct Auramine O staining technique. Missing even a single positive is injustice to the patient and our society. Fluorescent staining targeted at symptomatic individuals with paucibacilliary load is quite yielding. Results of fluorescent staining detected all the cases which were missed by ZN staining.

The better case detection rates of AO over ZN were comparable to those found by several studies. Jain *et al.* reported that Auramine Rhodamine (AR) fluorescent staining is more sensitive than the conventional ZN staining for demonstration of AFB in various clinical. Samples with definite advantage of AR over ZN in paucibacilliary cases (Jain, 2002). Masood *et al.* also reported higher sensitivity and rapidity of the fluorochrome technique as compared to ZN staining. (Masood *et al.*, 2008) Similar results were reported by Singh *et al.* who found fluorescence microscopy (72.8%), to be more sensitive than conventional (55.6%) microscopy (Singh, 1998) Similarly, Laifangbam *et al.* concluded AO to be superior to ZN and able to detect more pauci-bacilliary cases than ZN with fewer (2.78%) false negative by AO staining which was in sharp contrast to that of ZN (40.27%) (Laifangbam, 2009). In another study by Hooja S *et al.*, the sensitivity of direct staining with AO (71.85%) was found to be better than ZN (55.55%). After concentration, the sensitivity increased by 6.67% for ZN and 11.11% for AO. AO staining detected 9.3% paucibacilliary sputum samples that were missed on ZN staining (Hooja, 2012).

Interestingly, Shrihari Narayan *et al.* concluded that AO staining (11.43%) was nearly as sensitive as ZN (12.32%) and fared better than AR (8.50%) (Shrihari, 2012). In another comparative study by Balakrishna *et al.*, AO technique was found to have better sensitivity than ZN and Gabbet's methods in the detection of AFB. (Balakrishna *et al.*, 2013) Prasanthi *et al.* observed that the higher sensitivity of Fluorescent stain (45%) than that of ZN stain (29%) in detecting the paucibacilliary cases associated with HIV co-infection. (Prasanthi and Kumari, 2005) Similar results were found by Ziaem *et al.*, Cattamanachia *et al.*, Steingart *et al.*, (Ziaem, 2008; Cattamanachia *et al.*, 2009; Steingart, 2006).

Conclusion

Fluorescent staining is highly sensitive than ZN staining in detecting even paucibacilliary cases even in direct sputum smears. Sputum decontamination improves the diagnostic efficacy of sputum smears. To conclude, need for better detection rates of mycobacteria, may demand fluorescent microscopy to replace the standard Ziehl Neelsen microscopy in near future so that 100% detection rates can be aimed at and achieved for pulmonary tuberculosis cases.

REFERENCES

- Balakrishna, J., Shahapur, P.R., Chakradhar, P., Saheb, H. 2013. Comparative Study of Different Staining Techniques-Ziehlneelsen Stain, Gabbet's Stain, Fluorochrome Stain for Detecting of Mycobacterium Tuberculosis in the Sputum. *J Pharm Sci and Res.*, 5(4):89-92.
- Cattamanachia, Lucian, Davis, J Huang. 2009. Sensitivity and specificity of Fluorescent Microscopy for the diagnosis of pulmonary tuberculosis in a high HIV prevalent setting. *Int J Tuberc Lung Dis Sep.*, 13(9):1130-6.
- Guidance for TB Notification in India -2012, Central TB Division, Directorate General of Health Services, Ministry of Health and Family Welfare, Govt of India.
- Hooja, S., Pal, N., Malhotra, B., Goyal, S., Kumar, V., Vyas, L. 2011. Comparison of Ziehl Neelsen and Auramine O staining methods on direct and concentrated smears in clinical specimens. *Indian J Tuberc.*, 58(2):72-6.
- Jain, A., Bhargava, A., Agarwal, S.K. 2002. A comparative study of two commonly used staining techniques for acid fast bacilli in clinical specimens. *Ind J Tuberc.*, 49:161.
- Kent, P.T., Kubica, G.P. 1985. Public Health Mycobacteriology. A Guide for the level III laboratory, CDC Atlanta, Georgia: US Department of Health and Human Services.
- Laifangbam, S., Singh, H.L., Singh, N.B., Devi, K.M., Singh, N.T. 2009. A comparative study of fluorescent microscopy with Ziehl-Neelsen staining and culture for the diagnosis of pulmonary tuberculosis. *Kathmandu Univ Med J.*, Jul-Sep;7(27):226 -30.
- Manual for sputum smear fluorescence microscopy. Revised National Tuberculosis Control Programme. Central TB Division. Ministry of Health and Family Welfare, New Delhi.
- Masood, Z., Mohammad, N., Majid, K., Ghodsieh, A. 2008. Comparison of the value of two different sputum staining for diagnosis of acid fast bacilli, *Iranian Journal of Clinical Infectious Diseases*, 3(2):99-102.
- Prasanthi, K, Kumari, A. Efficacy of fluorochrome stain in the diagnosis of pulmonary tuberculosis co-infected with HIV. *Indian Journal of Medical Microbiology*, 2005;23(3): 179-185.
- Shrihari N, Kumudini TS. A Comparison of three different staining methods for the detection of acid fast bacilli (Mycobacterium tuberculosis) in sputum samples. *JPBMS*, 2012;14(06):1-2.
- Singh, N.P., Parija, S.C. 1998. The value of fluorescence microscopy of auramine stained sputum smears for the diagnosis of pulmonary tuberculosis. *Southeast Asian J Trop Med Public Health*, 29(4):860-3.
- Steingart, K.R., Henry, M., Ng, V., Hopewell, P.C., Ramsay, A, Cunningham, J, Urbanczik, R. *et al.* 2006. Fluorescence versus conventional sputum smear microscopy for tuberculosis: a systematic review. *Lancet Infect Dis.*, 6(9):570-81.
- TB burden of disease in India. In: TB India 2008 RNTCP status report. Central TB Division, Directorate General of Health Services, Ministry of Health and Family Welfare, Nirman Bhawan, New Delhi, 2008.

- Tiwari, V.K., Gupta, N., Bansal, S. Research paper - Comparative Study of the diagnostic yield of Fluorescent and Ziehl Neelsen Staining Techniques with the reference to the diagnosis of Pulmonary Tuberculosis. *International Journal of Scientific Research*, 2015;4(1):251-3.
- WHO. Treatment of Tuberculosis-Guidelines 4th edition. 2009.
- Ziaem, Namaei M, Khazae M, Azarkar G. A comparison of the value of two different sputum stainings i.e. Zeihl Neelsen and fluorescent for the diagnosis of Acid Fast bacilli. *Archives of Clinical Infectious Diseases*, 2008;3:2.
