



## RESEARCH ARTICLE

### HYDATID CYST OF ORAL CAVITY-A RARE CASE REPORT

<sup>1</sup>Dr. Asha, M. L., <sup>2,\*</sup>Dr. Jasti Sri Lakshmi, <sup>3</sup>Dr. Lekshmy J., <sup>4</sup>Dr. Mahesh Kumar, H. M. and  
<sup>5</sup>Dr. Laboni Ghorai

<sup>1</sup>Professor and Head of the Department, Department of Oral Medicine and Radiology,  
Dr. Syamala Reddy Dental College, Bangalore

<sup>2,5</sup>Post Graduate Student, Department of Oral Medicine and Radiology,  
Dr. Syamala Reddy Dental College, Bangalore

<sup>3,4</sup>Senior Lecturer, Department of Oral Medicine and Radiology,  
Dr. Syamala Reddy Dental College, Bangalore

#### ARTICLE INFO

##### Article History:

Received 16<sup>th</sup> February, 2016  
Received in revised form  
24<sup>th</sup> March, 2016  
Accepted 19<sup>th</sup> April, 2016  
Published online 10<sup>th</sup> May, 2016

##### Key words:

Hydatid Cyst,  
Echinococcosis,  
Maxillofacial Hydatid Cyst.

Copyright © 2016, Dr. Asha et al. This is an open access article distributed under the Creative Commons Attribution License, which permits unrestricted use, distribution, and reproduction in any medium, provided the original work is properly cited.

Citation: Dr. Asha, M. L., Dr. Jasti Sri Lakshmi, Dr. Lekshmy J., Dr. Mahesh Kumar, H. M. and Dr. LaboniGhorai, 2016. "Hydatid cyst of oral cavity-a rare case report", *International Journal of Current Research*, 8, (05), 30652-30654.

## INTRODUCTION

Hydatid cyst or Echinococcosis is a zoonotic parasitic disease caused by tapeworm is common worldwide with dog as its definitive host (Georgopoulos *et al.*, 2007). The disease is endemic in many Mediterranean countries, the Middle East and Far East, South America, South and East Africa (Dagtekin *et al.*, 2009). The majority of hydatid cysts appear in the liver (65%) and lungs (25%). They appear less frequently in other organs; about only 2% affect the maxillofacial region (Amr *et al.*, 1994). These usually appear as cystic lesions located in the mandible, maxillary sinus, orbit, infratemporal fossa, pterygopalatine fossa, parapharyngeal space, tongue, parotid gland, and submandibular salivary gland (Gangopadhyay *et al.*, 1996; Hotz and Gottstein, 1999; Amr *et al.*, 1994; Nandakumar and Shankaramba, 1989; Akyildiz *et al.*, 1991; Sennaroglu *et al.*, 1994; Goldsher *et al.*, 1983; Zaidi *et al.*, 1999;

Altman *et al.*, 1966; Perl *et al.*, 1972; Önerci *et al.*, 1991). Hydatid cysts in the maxillofacial region are rare, and only a few cases have been reported in the literature till date (Katilmis *et al.*, 2007).

## Case report

A 45 year old male patient came to our department with a chief complaint of swelling in the gum in left lower back tooth region since 1 year with periodic fluctuations in the size of the swelling. It was insidious in onset, slowly progressive and not associated with fever or history of trauma. Swelling eventually ruptures giving watery discharge and disappears and reappears after a period of time. Patient is known diabetic for 5years and is under medication. His past dental history was non-contributory. General examination revealed no abnormality. Extra oral and lymph node examination revealed no abnormality. No deleterious habits. Intra oral examination revealed full set of dentition with generalised calculus and extrinsic stains on the teeth.

\*Corresponding author: Dr. Jasti Sri Lakshmi,  
Professor and Head of the Department, Department of Oral Medicine  
and Radiology, Dr. Syamala Reddy Dental College, Bangalore.

Soft tissue examination showed generalised reddish pink gingiva, generalised bleeding on probing. Inspection of lesion showed a solitary, well defined swelling in the lower left buccal vestibule, roughly round measuring around 0.5x0.5cm in size, extending from the distal aspect of 34 to mesial aspect of 35. Surface of the swelling appeared stretched, shiny. Colour was bluish translucent. Surface was intact. No signs of any discharge, bleeding. No visible pulsations. (Figure 1) Palpation of the swelling confirmed all inspectory findings. It was uniformly soft in consistency, non-tender, fluctuant, compressible, non-reducible, non-pulsatile and non-blanching on pressure.

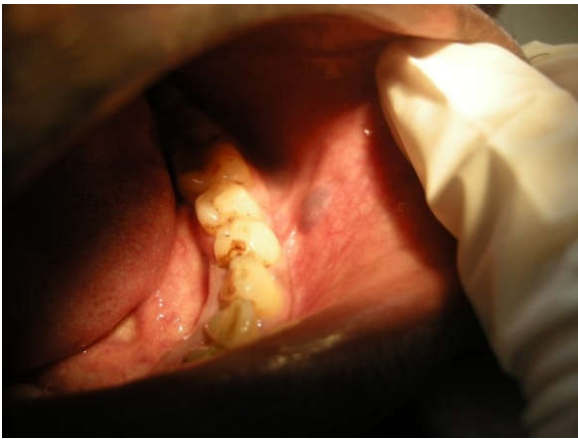

Figure 1. Clinical Presentation of the cyst



Figure 2. Biopsy Specimen

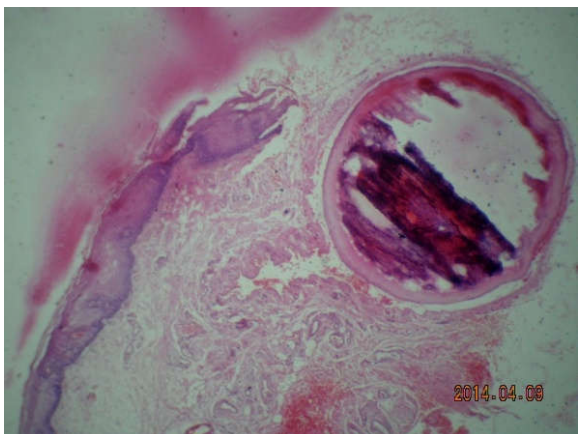


Figure 3. Histopathology revealing a parasitic cyst

On the basis of clinical examination we arrived at a provisional diagnosis of mucocele of buccal vestibule and differential diagnosis of haematoma, haemangioma, varix were considered. Patient was subjected to excisional biopsy, H&E section showed reactive epithelium with connective tissue fibrosis that showed neurovascular bundles. A circular mass of enclosed eosinophilic material resembling a parasitic cyst noted in deeper layers of connective tissue with a layer of well circumscribed extravasated RBC's indicative of haematoma. No dysplasia in the epithelium. (Figure 2,3) Hence, on the basis of history, clinical examination and H/P report we arrived at a final diagnosis of Hydatid cyst with superficial haematoma of lower left buccal vestibule. The patient was referred to a general physician to rule out for any multiorgan involvement and the results were negative. The patient was recalled once in three months for a year, there was no report of recurrence.

## DISCUSSION

Intestinal parasitic infections affecting the maxillofacial region is very rare (Hansen and Allard, 1984 and accounts for only about 2% of hydatid infections (Bader and Rose, 1979). *Echinococcus granulosus* is a parasite of dogs, wolves, foxes and jackals. Human are accidentally affected by contamination of food by the eggs found in feces excreted by the animals. After the development of the embryo, various organs are infested by its migration through intestinal mucosa (Seema Khanna *et al.*, 2013). Hydatid cysts presenting in the head and neck region are extremely rare, and an isolated infestation with no history of cystic rupture elsewhere in the circulation, as seen in our case, is particularly unusual. In 1938, Placitelli was the first to report a hydatid cyst in the submandibular gland (Placitelli, 1938). Singh, (1972) and Önerci *et al.* (1991) reported a submandibular hydatid cyst in the English literature. Perl *et al.* (1972) reported the first hydatid cyst in the tongue in South African population (Perl *et al.*, 1972). Altmann *et al.* (1966) and Önerci *et al.* (1991) stressed the exceptional occurrence of hydatid cysts in the salivary glands, especially in the submandibular gland. Buccal mucosa hydatid cysts are known to be an even greater rarity. In 1965, Da Costa reported a buccal hydatid cyst in a 7-year-old girl (Da Costa *et al.*, 1965). Patients with echinococcus infestation must be advised to undergo thorough systemic investigations (Nandakumar and Shankaramba, 1989) as multiorgan involvement is known to be present in 20-30% of the cases. (Gangopadhyay *et al.*, 1996) Hydatid cysts in maxillofacial region, in the absence of systemic involvement, may be because of systemic dissemination through lymphatic route.

Usually hydatid cysts are asymptomatic and the presence of symptoms depend on location, size and pressure caused by enlarging cyst (Michail *et al.*, 2007; Akal and Kera, 2002). The diagnosis of Hydatid infection mainly depends on the clinical history of the patient, diagnostic radiological findings and serologic tests. ELISA, Casoni skin tests, latex agglutination, immune electrophoresis and direct hemagglutination are serological methods are the various tests used for the diagnosis of hydatid disease. An increase in titer indicates recurrence of disease and a decrease in titer indicates resolution (Aletras *et al.*, 2000; Guney *et al.*, 2002). Diagnosis can be confirmed with histopathological examination after surgical removal of the cyst. Therapy with nontoxic scolicedal agents or

combination chemotherapy with mebendazole is of therapeutic value in the treatment of patients with recurrence or a high risk of contamination (Akal and Kera, 2002). Albendazole is suggested to be given post operatively for 1 month according to WHO guideline.

### Conclusion

Hydatid cyst should be kept as differential diagnosis of cervical masses especially in countries where Echinococcus infestation is endemic. Fine needle aspiration cytology is a good tool for diagnosis but risk of anaphylaxis is a major concern. Spilling of the cystic contents should be avoided during surgical removal of the cyst. Histopathological examination of surgical specimen and patient follow up seems critical in all cases in order to offer accurate diagnosis and definitive treatment and prevent recurrence. The long-term prognosis is difficult to predict; therefore, prolonged follow-up visits are needed to determine the outcome (Önerci *et al.*, 1991).

### REFERENCES

- Akal, M. and Kera, M. 2002. Primary hydatid cyst of the posterior cervical triangle. *J Laryngol Otol.*, 116:153-155.
- Akyildiz, A.N., Ozbilen, M.S. and Goksu, N. 1991. Hydatid cyst of the pterygopalatine fossa. *J Oral Maxillofac Surg.*, 49:87-8.
- Aletras, H. and Symbas, N. 2000. Hydatid disease of the lung. In *General Thoracic Surgery*. 5th edition. Edited by Shields TW, Lo Cicero J, Ponn RB. Philadelphia: Lippincott Williams and Wilkins;:1113-1122.
- Altman, M.M. and Gutman, D. 1966. Echinococcus of the parotid gland. *J Laryngol Otol.*, 80:409-11.
- Amr, S.S., Amr, Z.S., Jitawi, S. and Annab, H. 1994. Hydatosis in Jordan: an epidemiological study of 306 cases. *Ann Trop Med Parasitol.*, 88:623-7.
- Bader, G., Rose, K.G. and Fohlmeister, I. 1979. Echinococcus cystic infections of the head and neck. *HNO*;27:237-41.
- Da Costa, J.Q. 1965. Quistos parasitarios da Boca. *Revista Portuguesa Estomatologia Cirurgia Maxilofacial*;6:99-106.
- Dagtekin, A., Koseoglu, A., Kara, E., Karabag, H., Avci, E., Torun, F. and Bagdatoglu, C. 2009. Unusual location of hydatid cysts in pediatric patients. *Pediatr Neurosurg*, 45(5): 379-83.
- Engin, G., Acunaş, B., Rozanes, I. and Acunaş, G. 2000. Hydatid disease with unusual localization. *Eur Radiology*; 10: 1904-1912.
- Gangopadhyay, K., Abuzeid, M.O. and Kfoury, H. 1996. Hydatid cyst of the pterygopalatine-infratemporal fossa. *J Laryngol Otol.*, 110: 978-80.
- Georgopoulos, S., Korres, S., Riga, M., Kouvidou, C.H., Balatsouran, D. and Ferekidis, E. 2007. Hydatid cyst in the duct of the submandibular gland. *Int J Oral Maxillofac Surg*; 36:177-179.
- Goldsher, M., Eliachar, I., Joachims, Z. and Golz, A. 1983. Primary hydatid cyst of the maxillary sinus. *J Laryngol Otol.*, 97:869-70.
- Guney, O., Ozturk, K., Kocaogullar, Y., Eser, O. and Acar, O. 2002. Submandibular and intracranial hydatid cyst in an adolescent. *Laryngoscope*, 112:1857-1860.
- Hansen, L.S. and Allard, R.H.B. 1984. Encysted parasitic larvae in the mouth. *J Am Dent Assoc*;108:632-6.
- Hotz, M.A. and Gottstein, B. 1999. Cystic echinococcosis of the parapharyngeal space: case report with a 20-year follow-up. *J Oral Maxillofac Surg.*, 57:80-3.
- Katilmis, H., Ozturkcan, S., Ozdemir, I., Adadan Guvenc, I. and Ozturan, S. 2007. Primary hydatid cyst of the neck. *Am J Otolaryngol*, 28:205-207.
- Michail, O.P., Georgiou, C., Michail, P.O., Felekouras, E., Karavokyros, I., Marinos, G., Giannopoulos, A. and Griniatsos, J. 2007. Disappearance of recurrent intra abdominal extrahepatic hydatid cyst following oral albendazole administration. *West Indian Med J.*, 56(4):16-21.
- Nandakumar, H. and Shankaramba, K.B. 1989. Hydatid cyst of the mandible: a case report. *J Oral Maxillofac Surg.*, 47:759-61.
- Önerci, M., Turan, E. and Ruacan, S. 1991. Submandibular hydatid cyst: a case report. *J Craniomaxillofac Surg.*, 19:359-61.
- Perl, P., Perl, T. and Goldberg, B. 1972. Abbreviated case report: hydatid cyst in the tongue. *Oral Surg Oral Med Oral Pathol*;33:579-81.
- Placitelli, G. 1938. Sullecisti di echinococco primitive delle ghiandole salivari. *Rivista Generale Italiana Chirurgia*;4:109.
- Seema khanna, Shashi prakashmishra, Dayanand gupta, Satendrakumar, A K Khanna, S K gupta. Unusual presentation of hydatid cyst: a case report. *IJRANSS*, 2013; 1(1), 25-28.
- Sennaroglu, L., Önerci, M., Turan, E. and Sungur, A. 1994. Infratemporal hydatid cyst—unusual location of echinococcosis. *J Laryngol Otol.*, 108:601-3.
- Singh, S. 1972. Submandibular hydatid cyst. *J Laryngol Otol.*, 86: 647-50.
- Zaidi, M. 1999. An unusual case of orbital hydatid cyst: a surgical emergency. *Ann Plast Surg.*, 42:327-29.

\*\*\*\*\*