



RESEARCH ARTICLE

EVALUATION OF BONE CHANGES AND RANGE OF MOTION OF THE TEMPOROMANDIBULAR JOINT USING CONE BEAM COMPUTED TOMOGRAPHY- A PROSPECTIVE CROSS SECTIONAL STUDY

\*Dr. Naveen Kumar, B., Dr. SaraswathiGopal and Dr. B. G. HarshaVardhan

Department of Oral Medicine and Radiology, Meenakshiammal Dental College and Hospital, Chennai

ARTICLE INFO

Article History:

Received 01<sup>st</sup> January, 2016  
Received in revised form  
11<sup>th</sup> February, 2016  
Accepted 20<sup>th</sup> March, 2016  
Published online 26<sup>th</sup> April, 2016

Key words:

Temporomandibular  
Prospective  
Tomography.

ABSTRACT

**Background:** The Temporomandibular joint (TMJ) is one of the most complex joints in the human body and is the area in which the mandible articulate with the cranium. Conventionally, the most commonly used radiographic methods for the evaluation of osseous changes of the TMJ include transcranial projection, transpharyngeal projection, tomography and panoramic radiography. With the introduction of Computed Tomography (CT), the osseous components of the TMJ can be viewed three dimensionally. Unfortunately, most CT units are large and expensive, and are not readily available to dentists. Cone Beam CT (CBCT) is a newly developed technique and because of its comparatively lower radiation dose and higher spatial resolution, it has been widely accepted and used for different diagnostic tasks in oral and maxillofacial region. Recent Studies have revealed that the CBCT is a reliable alternative to multislice CT for the assessment of the TMJ space and osseous changes.

**AIM:** The aim of this study is to evaluate osseous changes and the range of motion of TMJ in Temporomandibular disorder using CBCT.

**Materials and Methods:** A prospective cross sectional study has been conducted at Department of Oral Medicine and Radiology, private Dental Institution, Chennai. The study population will consist of 50 subjects (100TMJs) from 18-60 years of age. Using 3D reconstruction CBCT (ProMax 3D Machine), images obtained in both maximum intercuspitation and maximum mouth opening position.

**Results:** The Adjusted Logistic Regression model, age and gender showed no statistically significant association with the presence of bone changes. The Pearson  $X^2$  test showed that there was a statistically significant association with the presence of bone change in relation to condylar mobility of the Right TMJ (Right side  $p = 0.009$ ; Left side  $p = 0.811$ ). The results of the McNemar test showed that the proportions of TMJ bone changes showed no significant differences between the sides ( $p = 1.000$ ). The range of motion proved to be increased demonstrating hypermobility in 35 patients in the right TMJs and 37 patients in the left TMJs. Hypomobility was seen in 4 Right TMJs and 2 Left TMJs.

**Conclusion:** There is a high prevalence of degenerative bone alteration in TMJs, which is more frequent in women and mostly located in the condyle. The prevalence of degenerative bone changes occur at the young age group. There is significant correlation between condylar mobility and the presence of degenerative bony changes in TMJs.

Copyright © 2016, Dr. Naveen Kumar et al. This is an open access article distributed under the Creative Commons Attribution License, which permits unrestricted use, distribution, and reproduction in any medium, provided the original work is properly cited.

Citation: Dr. Naveen Kumar, B., Dr. SaraswathiGopal and Dr. B. G. HarshaVardhan, 2016. "Evaluation of bone changes and range of motion of the Temporomandibular joint using cone beam computed tomography- a prospective cross sectional study", *International Journal of Current Research*, 8, (04), 29737-29743.

INTRODUCTION

The Temporomandibular joint (TMJ) is a compound articulation formed from the articular surfaces of the temporal bone and the mandibular condyle. The TMJ functions uniquely in that the condyle both rotates within the fossa and translates anteriorly along the articular eminence. The joint is thus referred to as "gynlimodiarthrodial": a combination of the terms ginglymoid (rotation) and arthrodial (translation) (Kathleen Herb et al., 2006) Temporomandibular Disorders (TMD) are disorders affecting the TMJ masticatory muscles

\*Corresponding author: Dr. Naveen Kumar, B.

Department of Oral Medicine and Radiology, Meenakshiammal Dental College and Hospital, Chennai

and/or associated structures. TMD is a collective term that includes a number of clinical complaints involving the muscles of mastication, the temporomandibular joint (TMJ), or associated orofacial structures. (Okeson, ?) Currently, between 10% to 30% of the world's population seeks specialized care for temporomandibular disorders (TMD) [Nickerson and Veaco, 1989; Pullinger and Monteiro, 1988; Puricelli, 2000], which poses one of the most challenging treatment problems in the field of dentistry. TMD is a common disorder with approximately 33% of the population showing at least one TMD symptom and 3.6% to 7% of the population are afflicted with TMD severe enough to cause them to seek treatment. (Wright, 2005) Temporomandibular joint (TMJ) imaging is very challenging because the bony components are small and super impositions from the base of the skull often result in a

lack of clear delineation of the joint. Clinical examinations are often not sufficient to reach a definite diagnosis regarding different conditions affecting the TMJ. In order to detect TMJ disorders, complimentary imaging studies are necessary. Thus, a combination of clinical examinations and imaging workup are required to detect TMJ disorders. (SharifiShooshtari *et al.*, 2014) TMDs are frequently associated with degenerative bone changes involving the bone structures of the temporomandibular joint (TMJ) such as flattening, erosion, osteophytes subchondral bone sclerosis and pseudocysts. (Mengel *et al.*, 2005) Knowledge about these bone changes is fundamental for correctly diagnosing the dysfunctions associated with the disease and for adequate treatment planning. Conventional radiography has limited application for the assessment of the TMJ due to the superimposition of the adjacent structures, overlapping of the neighbouring anatomical landmarks, providing a 2D view of the area and its innate distortion CT does not have any of the limitations of conventional radiography and provides a high contrast view of the maxillofacial region with no superimposition. This technique is used for the assessment of TMJ bone lesions with satisfactory results. However, it also has some limitations for use particularly in the TMJ area such as high cost, inaccessibility and more importantly high exposure dose. In the recent years, Cone Beam Computed Tomography (CBCT) has been suggested for radiographic assessment of the maxillofacial area (Varghese *et al.*, 2010). CBCT provides images with high resolution and quality at a much shorter scanning time, lower cost and more importantly lower exposure dose compared to CT. CBCT provides a three dimensional image of the maxillofacial mineralized tissue with minimal distortion and has been shown to be efficient in the diagnosis of several bone changes that affect the TMJ. (Ludlow *et al.*, 2006) Therefore, the aim of this study was to assess the prevalence of degenerative bone changes in TMJs using CBCT and correlate these with age, gender, type of alteration, side and mobility. Therefore, CBCT proves to be an invaluable diagnostic tool for the evaluation of the osseous structures of the TMJ.

### Aim and Objectives

The aim of this study is to evaluate osseous changes and the range of motion of TMJ in Temporomandibular joint disorder using CBCT and to correlate the osseous changes with age, gender, type of alteration, side and range of motion.

## MATERIALS AND METHODS

A Cross-sectional study was conducted at the Department of Oral Medicine and Radiology, private college in Chennai. The Study population consisted of 50 Subjects from the age groups of 18 to 60 years. Patients who respond affirmatively to the given pre-printed questionnaire with at least one positive answer are included in the study. Individuals were clinically evaluated and only if diagnosed to a case of Temporomandibular joint disorder, they were subjected to CBCT TMJ Analysis. The study design was approved by the Ethics Research Committee. Completely Edentulous, Patients Undergoing Orthodontic Treatment, TMJ Ankylosis and patient with atypical Facial pain were excluded from the study.

Clinical TMJ evaluation and related muscle examination was then followed and on correlation if a Provisional diagnosis of Temporomandibular Joint Disorder was arrived upon, the patient was subjected to further investigation. All the individuals were made to wear Lead Apron and Thyroid collar before subjecting them to X-ray exposure. All subjects were examined and oriented to have their heads positioned with the Frankfort horizontal plane parallel to the floor with maximum Inter-cuspatation and the parameters were adjusted for maxillary exposure with raised lower limit to locate TMJ within the Field Of View (FOV). TMJ were scanned with the Planmeca Promax Cone –Beam 3D imaging system. With the Similar parameters, one more exposure was done using open mouth position with a fibre bite block was placed between the posteriors. Images acquired were examined with the scanner's proprietary ROMEXIS software. The images were acquired in coronal, axial and sagittal sections and were analysed and Interpreted. The head of the condyle in the sagittal section was examined for bone changes if any and documented. The Range of motion was assessed based on the relation of the condyle with the articular eminence.

### Image interpretation

The TMJ images were assessed using a computer with a 21-inch monitor and the ROMEXIS Workstation. Age, gender, degree of condylar mobility and osseous changes were recorded on an evaluation sheet for each patient. In order to avoid misinterpretation, bone changes had to be found in at least two consecutive slices. The TMJ tool was used to on the long axis view of the condyle to generate lateral and frontal cross sectional reconstructions respectively. The thickness of the image slices was 1 mm and the distance between slices was 1 mm for both lateral and frontal reconstructions. Right and Left TMJs were evaluated separately, resulting in a total of 100 TMJs.

### Statistical analysis

The collected data was analysed with SPSS 16.0 version. To describe about the data descriptive statistics frequency analysis, percentage analysis were used for categorical variables and for continuous variables the mean and S.D were used. To find the significance in categorical data Chi-Square test was used. In the above statistical tool the probability value .05 is considered as significant level.

## RESULTS

50 individuals of age range 18- 60 years comprising of 29 Females and 21 male were recruited for the study. One subject was excluded during the course of the study as the MRI of patient proved ankylosis; which was one of the exclusion criteria proposed. 98 TMJs of the 49 included patients were considered for further data interpretation. The frequency and cumulative percentage on comparing between both sexes showed that 29 Females and 21 Males were positively diagnosed for TMD with a valid percent of 58 for Females and 42 for Males.

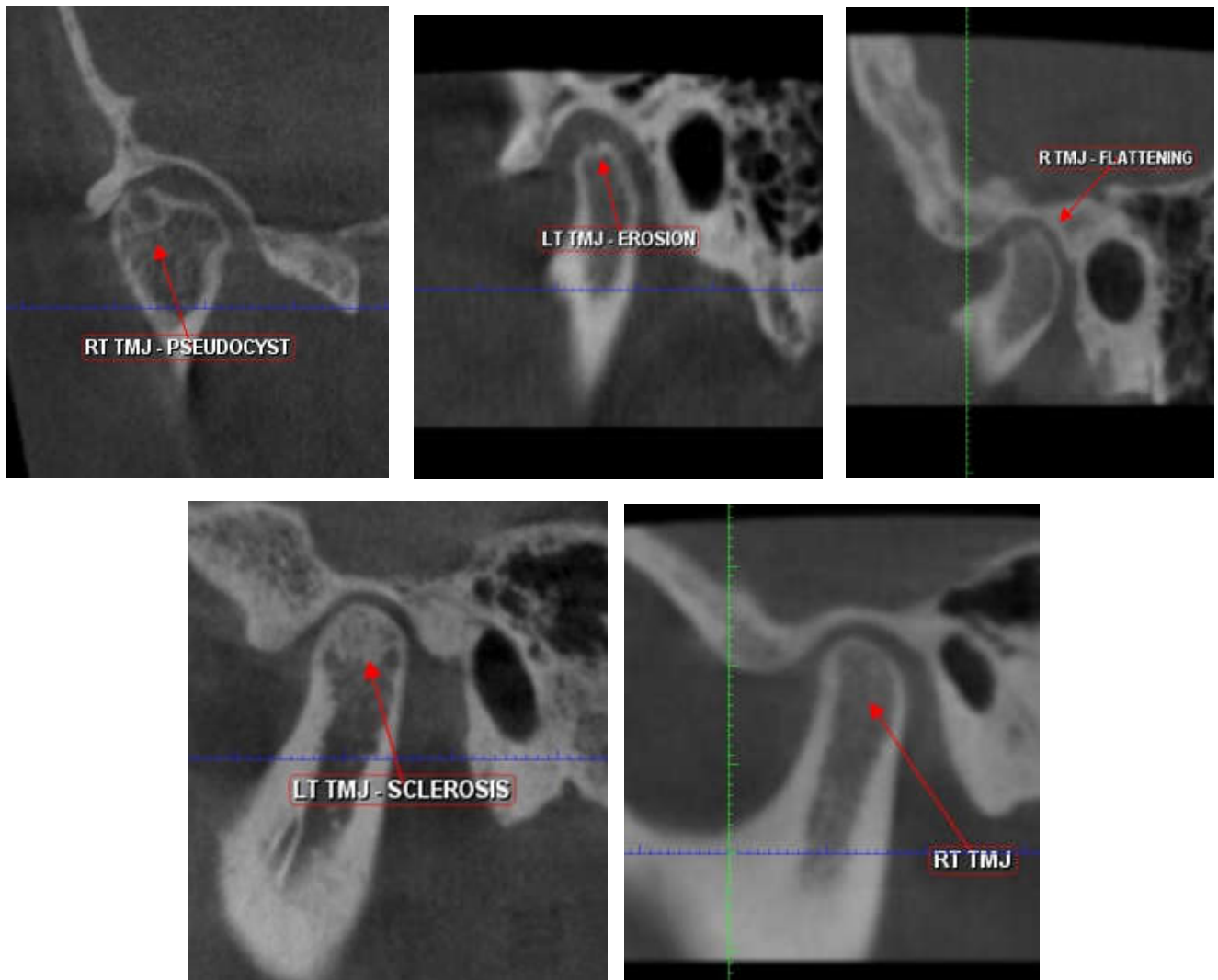


Figure 1. Osseous Changes observer in the TMJ condyle region

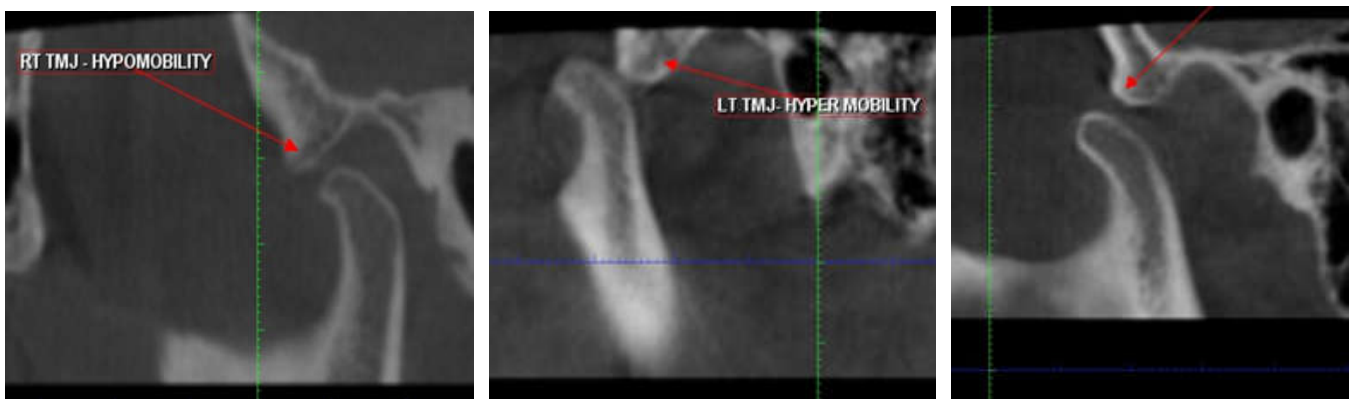


Figure 2. Range of Motion

The Adjusted Logistic Regression model, age and gender showed no statistically significant association with the presence of bone changes. (Table I). The Pearson  $X^2$  test showed that there was a statistically significant association with the presence of bone change in relation to condylar mobility of the Right TMJ (Right side  $p = 0.009$  ; Left side  $p = 0.811$ ) (Table II). The results of the McNemar test showed that

the proportions of TMJ bone changes showed no significant differences between the sides ( $p = 1.000$ ) (Table III). The range of motion proved to be increased demonstrating hypermobility in 35 patients in the right TMJs and 37 patients in the left TMJs. Hypomobility was seen in 4 Right TMJs and 2 Left TMJs.

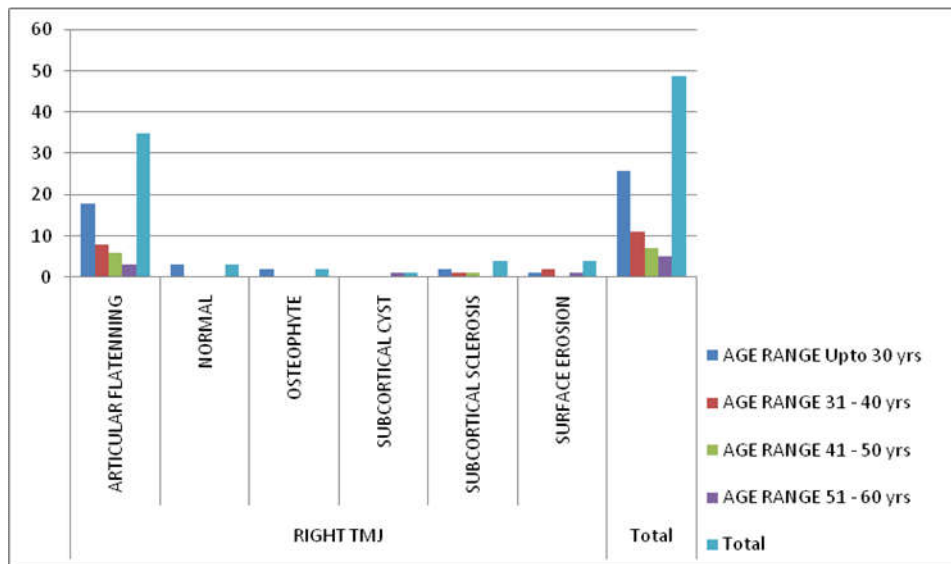


Chart I. AGERANGE \* RIGHT TMJ Crosstabulation

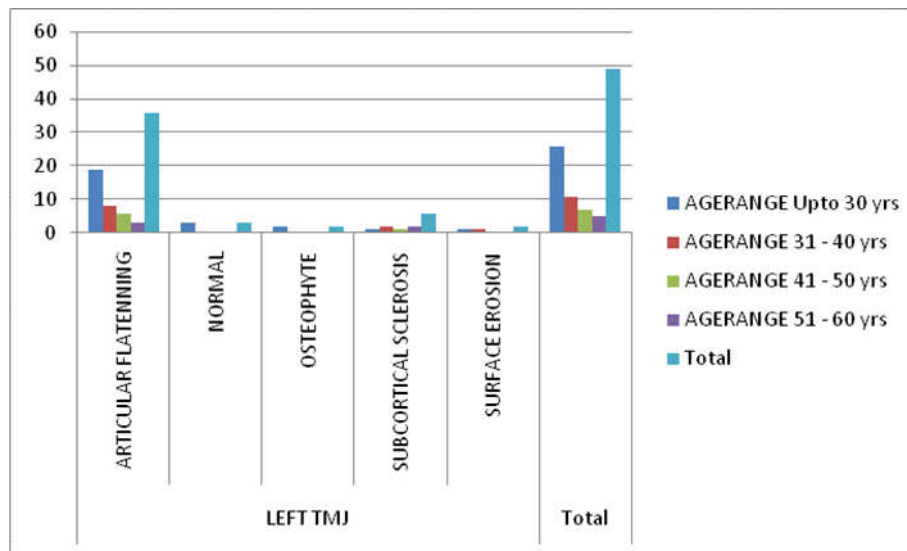


Chart II. AGERANGE \* LEFT TMJ Crosstabulation

Table I. Adjusted Logistic Regression Model (Age & Gender association with bone changes)

	B	S.E.	Wald	df	Sig.	Exp(B)
Step 1 <sup>a</sup>						
AGE	-.141	.099	2.051	1	.152	.868
SEX	-.147	1.084	.018	1	.892	.863
Constant (Bone Changes)	1.437	2.474	.337	1	.561	4.208

a. Variable(s) entered on step 1: AGE, SEX.

Table II. Pearson X<sup>2</sup> test

The Pearson X<sup>2</sup> test – Right TMJ

Chi-Square Tests

	Value	df	Asymp. Sig. (2-sided)
Pearson Chi-Square	23.438 <sup>a</sup>	10	.009
Likelihood Ratio	16.620	10	.083
N of Valid Cases	49		

The Pearson X<sup>2</sup> test – Left TMJ

Chi-Square Tests

	Value	df	Asymp. Sig. (2-sided)
Pearson Chi-Square	4.484 <sup>a</sup>	8	.811
Likelihood Ratio	4.521	8	.807
N of Valid Cases	49		

Table III. McNemar Test –Comparison Between Right and Left TMJ Bone Changes

RIGHTTMJBC		LEFTTMJBC	
		0	1
0	1	2	1
		1	45

Test Statistics<sup>a</sup>

	RIGHTTMJBC & LEFTTMJBC
N	49
Exact Sig. (2-tailed)	1.000 <sup>b</sup>

## DISCUSSION

Several investigatory methods have been employed to evaluate degenerative changes of the TMJ. CBCT has become a reliable tool in TMJ imaging owing towards reduced cost and dose of radiation. Koyama *et al.* (Puricelli *et al.*, 2013) and Tsiklakis *et al.* (Cuccia and Caradonna, 2009) recommend CBCT instead of CT and considered CBCT more superior to CT for visualising bone changes in TMJ by analysing lateral slices in isolation or in combination with coronal slices. Our study complies with recommendations of these authors with all CBCT images taken for the study showing exceptional diagnostic information. The sample selected for this study were in accordance with a questionnaire which was based on TMD diagnostic criteria proposed by Schiffman *et al.* (Asim K Bag *et al.*, 2014) in 2014. The prevalence of bone changes in our study showed a slight female predilection with 29 Females and 21 Males being recruited in our study. This complies with the findings of Botelho *et al.* (TomislavBadel *et al.*, 2011) in 2008. Especially women in their reproductive years showed more prevalence based on studies by Madani *et al.* (Alomar *et al.*, ?), Gancalves *et al.* (Textbook of Human Anatomy), Pereira *et al.* (Yale, 1969) and Janal *et al.* (Susan Standring, Edition 41). Our study showed a similar finding with the majority of the female study population ranging between 18-40 years of age. But still our study failed to show a strong statistical significance with sex and bone changes which could be attributed to the smaller sample size of the study.

Degenerative changes of the TMJ were evaluated in a study by Alexiou *et al.* (Ana-Maria Grumezescu *et al.*, 2005) where in 71 CBCT images were evaluated to correlate with the age and severity of the TMJ osteoarthritic changes. The study concluded proposing that the progression and severity of osseous changes in the condylar head increase with age. This finding of our study was in agreement with study by CruzoeRebello *et al.* and Iceberg *et al.* (Temporomandibular Disorders, 2011) who proved that age does not influence bone changes. When assessing the distribution of bone changes based on the side it was found that both the sides were nearly equally affected showing no statistical significance on comparison with McNemar Test. This finding was contradicted in a study by MLdosAnjospontual *et al.* which proved statistically significant that left TMJ was more affected than the right. The high prevalence of flattening in our study was also noticed in studies by Guler *et al.* (Sommer *et al.*, 2003) and Alexiou *et al.* (Ana-Maria Grumezescu *et al.*, 2005). Flattening of condyle is considered as a adaptive alteration (i.e the first

change of a progressive disease) according to CruzoeRebello *et al.* and Palacios-ipen Moreno *et al.* (Sava and Scutariu, 2012). Flattening is also consider as a degenerative alteration resulting from the over load of the TMJ and the related to the involvement of masseter and temporal muscles (Susan Standring, Edition 41). Sclerosis usually develops secondarily in more progressive forms of the diseases Gynther *et al.* (Alex 7), our study demonstrated sclerosis in 10 joints making it the second prominent bony change in our study population. According to Dale A Miles this cortical alteration is one of the hallmark of osteoarthritis thus making it a potential indicator of TMJ joint disorder. Surface Erosions are another common feature in osteoarthritis, the advent of CBCT imaging allows better visualisation of these defects. According to a study by Kyung- SooMah (Richard L. Drake *et al.*, 2015, 2010, 2005) in 2012 out of the 440 joints imaged nearly 129 joints demonstrated surface erosion thus proposed as a prominent radiological finding. This was further supported by Cevidades *et al.* in Whose study 40% erosions were demonstrated in a symptomatic TMJ osteoarthritis group. Our study showed only 4 of the 98 joints depicting erosion, because we have included a broader study group including all the Temporomandibular joint disorder. Osteophytes occur at an advanced stage of degenerative change when the body adapts itself to repair the joint. The osteophyte appears to stabilise and widen the surface in an attempt to improve the over load resulting from occlusal forces, representing area of neo formed cartilage. Out of the 98 joints imaged, 4 joints demonstrated osteophytic changes which constitute about 0.04 of the study population. Subcortical cyst formation is an early indicator of osteoarthritic change and only with the advent of CBCT could they be appreciated. Serrazzo (Aiken *et al.*, 2012; Tomas *et al.*, 2006) in 2013 repoted a case were Pseudocyst / Subchondral cyst / Ely's cyst led to a conclusive diagnosis of TMJ osteoarthritis. However Our study demonstrated only a single joint with a subcortical cyst formation and it turned out to be that the patient was asymptomatic on that side of the joint. De Coster *et al.* found a positive relationship between hypermobility and TMD. Hypermobility is a dysfunction and is usually associated with broader degenerative bone process (Rao and Bacelar, 2002). In our study when assessing the influence of condylar mobility in the presence of local degenerative changes, a statistically significant correlation was arrived on the right side and this was consistent with findings of Palacios-ipen Moreno *et al.*, Vasconcelos *et al.* (Drace and Enzmann, 1990) and Aquotti-Ilha *et al.* (Tallents *et al.*, 1996), however the results of our study was contradicted by findings of MLdosAnjospontual *et al.* (Rammelsberg *et al.*, 1997). Hypomobility of the TMJ is

usually caused by a restricted joint capsule or by an anteriorly displaced disc according to Friedman *et al.* in 1997 (Orsini *et al.*, 1998). Our study demonstrated 6 joints with hypomobility, hence a decreased range of motion. Further studies are recommended to understand the biological effects of motion on joints and their necessary management. Hypomobility can be threatening because limited mobility results in acceleration of a variety of pathological process such as cartilage breakdown and formation of adhesion according to a systematic review by Israel and Syrop (ProvenzanoMde *et al.*, 2012) in 1997 and our study is in full agreement with this fact.

## Conclusion

In recent years, a new imaging technique, cone beam computed tomography (CBCT), is becoming increasingly popular in dentistry. CBCT scanners are based on volumetric tomography, which consists of a two-dimensional detector and a three-dimensional x-ray beam. While conventional CT scanners use slices of x-ray exposure, CBCT uses cone shapes for image acquisition, thereby reducing the radiation dose and cost for the patient. In addition, CBCT technology allows the image to be captured in one rotation of the x-ray source, which reduces the scanning time. Hence the study aims at identifying and evaluating the bone changes and range of motion in the temporomandibular joint, thus making a reliable and accurate diagnosis of the temporomandibular disorders which helps in timely intervention and in some cases for rendering a precise treatment plan for the at most benefit of the patient.

## REFERENCES

- Aiken A, Bouloux G, Hudgins P. MR imaging of the Temporomandibular joint. *MagnReson Imaging Clin N Am.*, 2012; 20: 397-412 [PMID: 22877948 DOI: 10.1016/j.mric.2012.05.002]
- Alomar X., Medrano, J. Cabratosa, J.A. Clavero, M. Lorente, *et al.* Anatomy of the Temporomandibular Joint; *Semin Ultrasound CT MRI* 28:170-183.
- Ana-Maria Grumezescu; Iancu, Drago Totolici; Lucian Ieremia; Fundamental considerations on the morphophysiology and morphopathology of the temporomandibular joint (TMJ); *OHDMBSC - Vol. IV - No. 4 - December, 2005; 38-44*
- Asim K Bag, Aparna Singhal, Simms Hardin, Benson D Tran, Josue A Medina, Joel K Curé, Imaging of the temporomandibular joint: An update; *World J Radiol.*, 2014 August 28; 6(8): 567-582
- Cuccia A, Caradonna C. The Relationship Between the Stomatognathic System and Body Posture. *Clinics (Sao Paulo, Brazil)*. 2009;64(1):61-66. doi:10.1590/S1807-593220090
- Drace JE, Enzmann DR. Defining the normal Temporomandibular joint: closed-, partially open-, and open-mouth MR imaging of asymptomatic subjects. *Radiology*, 1990; 177: 67-71 [PMID: 2399340]
- Guidelines for Diagnosis and Management of Disorders Involving the Temporomandibular Joint and Related Musculoskeletal Structures; Kathleen Herb, Sung Cho, and Marlind Alan Stiles, Temporomandibular Joint Pain and Dysfunction; *Current Pain and Headache Reports*, 2006, 10:408-414
- Koolstra JH. Dynamics of the human masticatory system. *Crit Rev Oral Biol Med.*, 2002; 13: 366-376 [PMID: 12191962 DOI: 10.1177/154411130201300406]
- Ludlow JB, Davies-Ludlow LE, Brooks SL, Howerton WB. Dosimetry of 3 CBCT devices for oral and maxillofacial radiology: CB Mercuray, NewTom 3G and i-CAT. *Dentomaxillofac Radiol.*, 2006; 35: 219-226
- Mengel R, Kruse B, Flores-de-Jacoby L. Digital volume tomography in the diagnosis of periodontal defects: an in vitro study on native pig and human mandibles. *J Periodontol.*, 2005; 76: 665-673
- Nickerson JW, Veaco NS: Condylotomy in surgery of the temporomandibular joint. *Oral Maxillofac Surg Clin North Am.*, 1989, 1:303-312. 2.
- Okeson JP. Differential Diagnosis of Temporomandibular Disorders and Other Orofacial Pain Disorders
- Orsini MG, Kuboki T, Terada S, Matsuka Y, Yamashita A, Clark GT. Diagnostic value of 4 criteria to interpret Temporomandibular joint normal disk position on magnetic resonance images. *Oral Surg Oral Med Oral Pathol Oral Radiol Endod.*, 1998; 86: 489-497 [PMID: 9798238 DOI: 10.1016/S1079-2104(98)90380-8]
- ProvenzanoMde M, Chilvarquer I, Fenyo-Pereira M. How should the articular disk position be analyzed? *J Oral Maxillofac Surg.*, 2012; 70: 1534-1539 [PMID: 22079066 DOI: 10.1016/j.joms.2011.08.004]
- Pullinger AG, Monteiro AA: History factors associated with symptoms of temporomandibular disorders. *J Oral Rehabil.*, 1988, 15:117-124.
- Puricelli E, Corsetti A, Tavares JG, Luchi GHM. Clinical-surgical treatment of temporomandibular joint disorder in a psoriatic arthritis patient. *Head & Face Medicine*, 2013;9:11. doi:10.1186/1746-160X-9-11.
- Puricelli E: Tratamentocirúrgico da ATM: casos selecionados - Surgical treatment of TMJ: previous cases. In *Atualizaçãona clínica odontológica: cursos antagônicos*. São Paulo: Artes Medicas; 2000:479-520
- Rammelsberg P, Pospiech PR, Jäger L, Pho Duc JM, Böhm AO, Gernet W. Variability of disk position in asymptomatic volunteers and patients with internal derangements of the TMJ. *Oral Surg Oral Med Oral Pathol Oral Radiol Endod.*, 1997; 83: 393-399 [PMID: 9084204 DOI: 10.1016/S1079-2104(97)90248-1]
- Rao VM, Bacelar MT. MR imaging of the Temporomandibular joint. *MagnReson Imaging Clin N Am.*, 2002; 10: 615-630 [PMID: 12685497 DOI: 10.1016/S1064-9689(02)00011-9]
- Richard L. Drake, A. Wayne Vogl, and Adam W.M. Mitchell; Gray's Anatomy for Students, Third Edition; 2015, 2010, 2005 by Churchill Livingstone, an imprint of Elsevier Inc
- Sava A, Scutariu M. Functional anatomy of the Temporomandibular joint (I). *Rev Med Chir Soc Med Nat Iasi.*, 2012; 116: 1213-1217 [PMID: 23700914]
- Sharifi Shooshtari *et al.* In-Vitro Comparison of the Diagnostic Accuracy of CBCT and Helical CT for Detection of Mandibular Condyle Erosions Journal of Islamic Dental Association of IRAN (JIDAI) Spring 2014; 26, (1)
- Sommer OJ, Aigner F, Rudisch A, Gruber H, Fritsch H, Millesi W, Stiskal M. Cross-sectional and functional imaging of the temporomandibular joint: radiology,

- pathology, and basic biomechanics of the jaw. *Radiographics* 2003; 23: e14 [PMID: 12920179 DOI: 10.1148/rg.e14];
- Susan Standring ; Gray's Anatomy: The Anatomical Basis of Clinical Practice- Edition 41; Elsevier Publications
- Tallents RH, Katzberg RW, Murphy W, Proskin H. Magnetic resonance imaging findings in asymptomatic volunteers and symptomatic patients with temporomandibular disorders. *J Prosthet Dent*, 1996; 75: 529-533 [PMID: 8709019 DOI: 10.1016/S0022-3913(96)90458-8]
- Temporomandibular Disorders: A problem-based approach, 1st Edition © Robin J.M. Gray and M. Ziad Al-Ani. Published 2011 by Blackwell Publishing Ltd
- Textbook of Human Anatomy : Head & Neck and Brain – B.D. Chaurasia.
- Tomas X, Pomes J, Berenguer J, Quinto L, Nicolau C, Mercader JM, Castro V. MR imaging of Temporomandibular joint dysfunction: a pictorial review. *Radiographics.*, 2006; 26: 765-781 [PMID: 16702453 DOI: 10.1148/rg.263055091]
- Tomislav Badel, Ivana Savić-Pavićin, Dijana Zadravec, Miljenko Marotti, Ivan Krolo, Đurđica Grbeša,; Temporomandibular joint development and functional disorders related to clinical otologic symptomatology; *Acta Clin Croat*, 2011; 50:51-60
- Varghese S. *et al.* Evaluation of the accuracy of linear measurements on spiral computed tomography-derived three-dimensional images and its comparison with digital cephalometric radiography, *Dentomaxillofacial Radiology*, (2010) 39, 216–223
- Wright EF. Manual of Temporomandibular Disorders. Ames, IA: Wiley-Blackwell, 2005.
- Yale SH: Radiographic evaluation of the temporomandibular joint. *J Am Dent Assoc.*, 79(1):102-107, 1969

\*\*\*\*\*