



RESEARCH ARTICLE

A RARE CASE OF UTERINE DIDELPHYS WITH PREGNANCY IN LEFT HORN DIAGNOSED IN SECOND PREGNANCY

***Dr. Mounika Reddy Chitikela, Dr. Aruna, S. N. and Dr. Mudanur, S. R.**

Department of Obstetrics and Gynecology, BLDEA'S Shri B.M. Patil Medical College and University, Vijayapur, Karnataka, India

ARTICLE INFO

Article History:

Received 28th January, 2016
Received in revised form
19th February, 2016
Accepted 13th March, 2016
Published online 26th April, 2016

Key words:

Uterus didelphys,
Cesarean section.

ABSTRACT

Fusion of the two Mullerian ducts and establishment of vaginal canal are completed between 10th and 17th week of intra-uterine development. There is presence of double uterine bodies with two separate cervixes and often a double or septate vagina. Women with congenital malformations of uterus usually have higher incidence of complications during pregnancy and delivery. Pregnancy in such a uterus causes various complications like spontaneous abortions, preterm labour, abnormal presentation and increased incidence of caesarean delivery. In case of single pregnancy in uterus Didelphys, literature shows the right uterus having pregnancy predominantly. We report a rare case of uterine Didelphys with pregnancy in left horn diagnosed in her second pregnancy.

Copyright © 2016, Dr. Mounika Reddy Chitikela et al. This is an open access article distributed under the Creative Commons Attribution License, which permits unrestricted use, distribution, and reproduction in any medium, provided the original work is properly cited.

Citation: Dr. Mounika Reddy Chitikela, Dr. Aruna, S. N. and Dr. Mudanur, S. R. 2016. "A rare case of uterine didelphys with pregnancy in left horn diagnosed in second pregnancy", *International Journal of Current Research*, 8, (04), 29735-29736.

INTRODUCTION

Mullerian duct anomalies are congenital anomalies of the female genital tract resulting from non development or non fusion of the Mullerian ducts. Duplication of the uterus results from lack of fusion of paramesonephric ducts in a local area or throughout their normal line of fusion. It constitutes approximately 5% of the Mullerian duct anomalies. According to American Fertility society classification of utero-vaginal anomalies, uterus Didelphys belongs to class III B.1.a. Pregnancy in uterus Didelphys is an uncommon; the incidence varies from 1 in 1500 to 1 in 14200 pregnancies worldwide. It is known to vary from 0.1% to 10%. It comprises about 5-7% of all Mullerian anomalies. Pregnancies in a Didelphys uterus have a better prognosis with regard to the fetal wastage rate rather than a pregnancy in a Bicornuate Septate or Arcuate uterus.

MATERIALS AND METHODS

A 23 yr old 2nd gravid with full term pregnancy with cephalic presentation with previous uneventful full-term vaginal

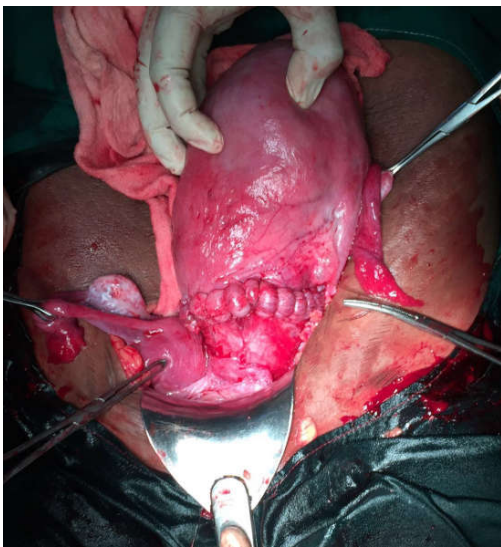
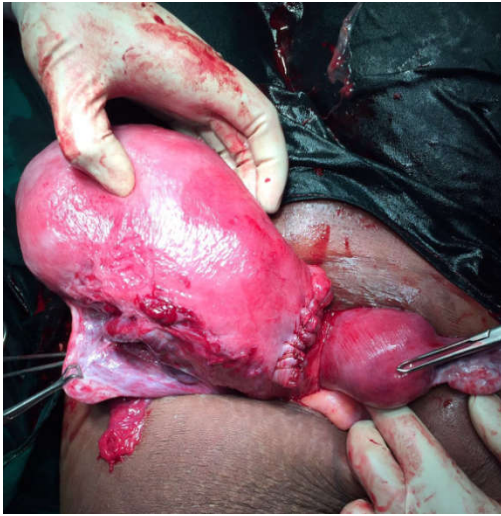delivery presented to labour room with complains of labour pains. She had regular antenatal check ups in a private clinic and this was her first visit to our institute. On General Examination, Patient is not anemic, pulse rate 78/min, BP 110/80mm of Hg in left arm supine position. CVS & RS-normal. Per Abdomen Examination: Uterus term size, cephalic presentation, fetal heart rate - 146bpm, uterus contractions are 2 in 10 min & each contraction lasting for 20-25sec. On Per Vaginal Examination: cervix was 5-6cms dilated, deviated to one side, 30-40% effaced, vertex was at -2 station, head can be pushed only up to -1 station, interspinous adequate, outlet adequate. Case was posted for caesarean section in view of cephalo-pelvic disproportion under spinal anesthesia. Abdomen opened by Pfannenstiel incision. Lower segment caesarean section was done.

RESULTS

Baby presented as left occipito-anterior and liquor was thick Meconium. An alive female baby of weight 4.03kg with APGAR 7-10 was delivered. After delivery of the placenta, when uterus was exteriorized, another non-gravid uterus was found on right side. It was diagnosed to be a case of uterus Didelphys. Fetus was delivered from the left uterus. Each

*Corresponding author: Dr. Mounika Reddy Chitikela
Department of Obstetrics and Gynecology, BLDEA'S Shri B.M. Patil
Medical College and University, Vijayapur, Karnataka, India

uterus had one fallopian tube & ovary. Both ovaries & tubes appeared to be healthy. Both uteri had separate cervixes opening into one vagina.



Her postoperative recovery was uneventful. Dressing was done on 2nd post operative day and skin stitches removed on 7th postoperative day. Patient was discharged on 8th post operative day.

DISCUSSION

Mullerian anomaly rate is reported between 0.1 – 1% in general population with significant higher rates associated with infertility and pregnancy wastage. These Mullerian duct anomalies are clinically more important because they are associated with impaired infertility, menstrual disturbances and obstetrical complications like obstructed labour. In case of single pregnancy in uterus Didelphys, literature shows the right single pregnancy in uterus Didelphys, predominantly. In Uterus Didelphys, non-pregnant uterine horn is also subjected to some hormone influences as the pregnant horn. It remains as a pelvic organ posterior and hampers the delivery of the baby. This type of anomaly is routinely diagnosed on pelvic examination, USG or HSG, with two separate uteri and widely divergent apices, two separate cervixes and upper vaginal longitudinal septum. Interestingly, in our present case report, this woman had single pregnancy in the left uterus and gave birth to a baby by cesarean section. However, this woman had previous full term uneventful vaginal delivery and the diagnosis was missed in both the pregnancies antenatally. Conclusively, we also state that patient with uterus Didelphys belong to high-risk group and deserve a particular prenatal care. Therefore, it is of great importance for the clinician to detect these abnormalities of reproductive tract in early stage by USG.

REFERENCES

- Eds. Speroff L and Fritz MA. The Uterus. In Clinical gynecologic endocrinology and infertility. 7thedn; 2005.p.132.
- Greek Lk. Harris RE. Uterine anomalies; frequency of anomalies and associated obstetrical complications. ObstetGynecol 1976;47:427-29.
- V.Aruna, S.Aliyaetal. Pregnancy in uterus didelphys delivered by caesarean section: case report and review of literature march IJSR 2015; 4(3)
- Willms gynecology 2nd edition Barbara L.Hoffman, John O Schorge Anatomic disorders 2003;481-503.
