



ISSN: 0975-833X

CASE STUDY

COMPOSITE FLAPS USED FOR RECONSTRUCTION OF RARE MASSIVE AMELOBLASTIC CARCINOMA

*¹Dr. Siddhartha Chatterjee, ²Dr. Srikanth Bitra, ²Dr. Zuhaib, ²Dr. Pradeep Sharma and
²Dr. Sanjiv Nair

¹Oral & Maxillofacial Surgeon, Fellow Smile Train, Mission of Mercy Hospital, Kolkata

²Oral & Maxillofacial Surgeon, Bangalore Institute of Dental Sciences, Bangalore

ARTICLE INFO

Article History:

Received 02nd September, 2015

Received in revised form

25th October, 2015

Accepted 17th November, 2015

Published online 30th December, 2015

Key words:

Ameloblastoma, Ameloblastic carcinoma,
Epidermoid carcinoma.

Copyright © 2015 Siddhartha Chatterjee et al. This is an open access article distributed under the Creative Commons Attribution License, which permits unrestricted use, distribution, and reproduction in any medium, provided the original work is properly cited.

Citation: Siddhartha Chatterjee, Srikanth Bitra, Zuhaib, Pradeep Sharma and Sanjiv Nair, 2015. "Composite flaps used for reconstruction of rare massive Ameloblastic carcinoma", *International Journal of Current Research*, 7, (12), 24433-24439.

ABSTRACT

Ameloblastic carcinoma is a malignant lesion with characteristic histological features and behaviour. In this case report we presented a case of massive Ameloblastic Carcinoma occurring in the mandible of a 34year old Nigerian female. Its typical clinical features, aggressive behaviour and differential diagnosis is discussed in detail. We treated the patient with radical resection and reconstruction with composite/double flaps using free fibula & anterolateral thigh flap as a single stage procedure. Reconstruction using double flap is rare but need of hour of treating huge defects, makes our treatment plan unique.

INTRODUCTION

Odontogenic malignancies are rare lesions arising from dental embryogenic residues. Odontogenic carcinomas have been designated by a variety of terms, including malignant ameloblastoma, ameloblastic carcinoma (AC), metastatic ameloblastoma, or primary intra-alveolar epidermoid carcinoma. The clinical course and histopathology of these tumours are similar to each other, so the differential diagnosis is crucial. Malignant ameloblastoma represent tumours that metastasize while both primary and metastatic lesions retain their benign histological appearance. The term ameloblastic carcinoma was introduced by Elzay (Review and update of odontogenic carcinomas). In the last update of the WHO classification, published in 2005 (Benlyazid *et al.*, 2007), ameloblastic carcinoma is defined as a rare odontogenic malignancy that combines the histological features of ameloblastoma with cytological atypia, even in the absence of metastases. Being uncommon, little information is available in the literature regarding its clinical characteristics, treatment modalities and outcome.

Case report

We present a case with massive Ameloblastic Carcinoma occurring in the mandible of a 34year old Nigerian female. A 34-year-old female patient reported with the complaint of rapidly growing painless swelling on the right side of the lower jaw since 6 months. Clinically, a painless ovoid swelling was seen on the right body of the mandible approximately 4 x 9 x 3 cm in size which extended anteriorly from the commissure of the lip on right side and posteriorly to the angle of the mandible. Inferiorly the extent was 0.5 cm below the lower border of the mandible. (Fig. 1, 2) Paraesthesia was associated with the swelling. Regional lymph nodes were palpable. Intra-oral examination revealed a painless smooth swelling extending from 43 to 47 region obliterating the buccal sulcus and extended lingually with expansion of the lingual cortex. On intra-oral palpation the swelling was soft in consistency with absence of any secondary changes like ulceration/ fistula formation/ infection/ discharge. It was non-tender, fluctuant with positive crepitus lingually. Thinning and perforation of the lingual cortex was felt with mobility of 44, 45 and 46. Aspirate obtained was a sero-sanguinous fluid which was sent for biochemical investigations subsequently revealing protein content 8 mg/dl and sugar content 108 mg/dl. A provisional diagnosis of an ameloblastoma of the right body of the mandible with high virulence was established. Differential

*Corresponding author: Dr. Siddhartha Chatterjee,
Oral & Maxillofacial Surgeon, Fellow Smile Train, Mission of Mercy
Hospital, Kolkata.

diagnosis included variants of ameloblastoma, central giant cell lesion and haemorrhagic bone cyst.

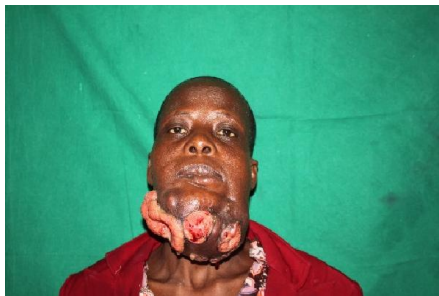

Fig. 1.

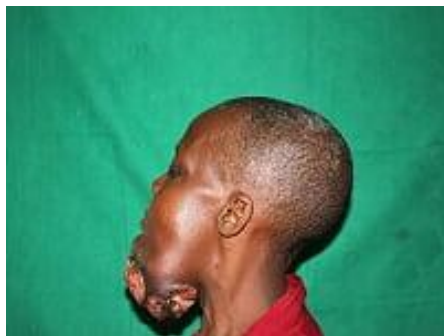

Fig. 1.

Radiographic findings

A right lateral oblique radiograph of the mandible showed a single well defined unilocular radiolucent lesion of approximately 2.5 x 9 x 2.5 cm in size in the right body with scalloped and irregular margins extending from the 43 to 47 region with thinning and erosion of the inferior border. The roots of 44, 45, and mesial root 46 were resorbed. Occlusal radiograph revealed gross lingual expansion and cortical perforation. A non-enhanced axial and coronal computed tomography showed a homogenous expansile lesion affecting the right body of the mandible with thinning and expansion of the buccal cortex with lingual cortex totally destroyed and tumour extending into the soft tissue. A PA and lateral chest radiograph ruled out presence of any metastatic deposits.

Surgery

Radical resection and reconstruction with composite/ double flaps using free fibula & anterolateral thigh flap was performed as a single stage procedure. (Fig. 3, 4, 5, 6, 7)

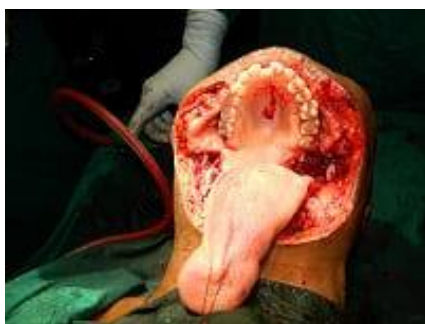

Fig. 3.

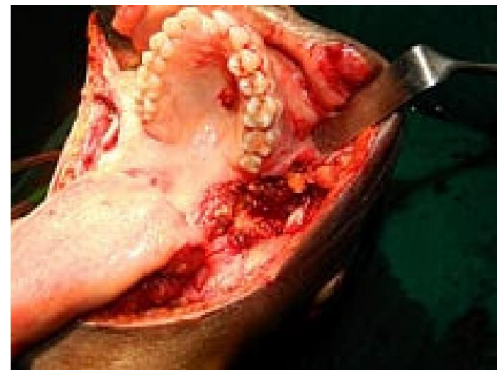


Fig. 4.

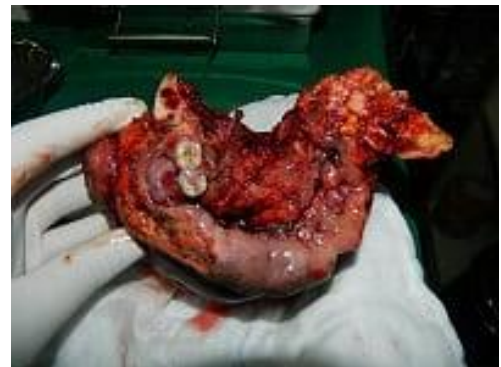

Fig. 5.

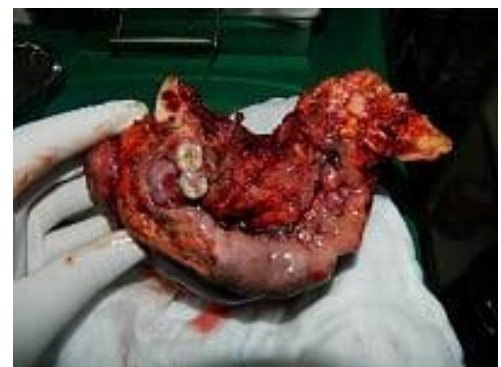

Fig. 6.

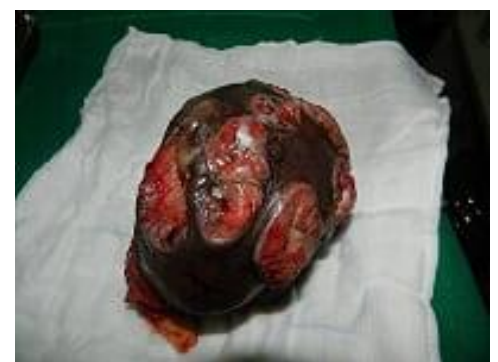

Fig. 7.

Preoperative assessment

The clinical assessment of the potential fibula free flap candidate involves a thorough assessment of the patient. The

suitability of the fibula is based on the perfusion status of the lower extremity and the foot. The clinician should look for signs of previous surgery or trauma and assess the skin temperature, hair growth, and thickening of the nail beds for any evidence of peripheral vascular disease. The evaluation of the lower extremity vasculature has evolved from the use of angiography to less invasive methods such as Color Doppler examination, CT angiography, and magnetic resonance angiography. Although some clinicians advocate only clinical examination of the lower extremity before harvesting the flap, magnetic resonance angiography our preferred method of assessment. This examination is important not only to confirm adequate perfusion of the lower extremity but also to confirm the presence of the peroneal artery and rule out the presence of peroneal arterial magna, in which the peroneal artery is the main blood supply to the foot. This variation has been reported to range from 0.2% to 7%. An evaluation of the anticipated mandibular defect should be undertaken. This study is commonly done with the aid of a panoramic radiograph and CT of the mandible. In oncologic cases a detailed discussion with the ablative surgeon is of utmost importance so that the constructive surgeon can have an appreciation of the anticipated defect size and tissues to be replaced.

We used a critical size defect in the range of 4 to 5 cm as a minimum cutoff for use of the fibula free tissue flap. Equally important is the evaluation of the recipient vessels in the head and neck. The recipient vessels most commonly used when reconstructing the mandible are the facial artery and vein. Alternatively, the superior thyroid artery, the external jugular vein, and the internal jugular vein may be used as the recipient vessels. The decision as to which vessel to use depends on the most ideal geometry and the best match of the vessel diameter. The determination of available recipient vessels is of critical importance in patients who have had previous neck surgeries, especially in patients who have undergone neck dissection. In these cases the operative dictations must be obtained to ascertain the extent of resection and the vessels resected or ligated.

Raising a bone only flap

After the patient is transferred to the operating table, the hip and knee are flexed and internally rotated so that the fibula is approximately at a 140° angle to the table. A 1-L saline bag wrapped in a towel is placed under the feet and taped to the bed, and a small bump is placed under the ipsilateral hip so that this desired position is maintained in a passive fashion. The lower extremity is prepared and draped in the usual standard fashion. The head of the fibula is palpated and marked, as is the lateral malleolus inferiorly. The peroneal nerve is palpated and marked. A vertical line connecting the two points is then marked. The vertical mark represents the intermuscular septum. A sheet of web roll is wrapped around the thigh and a tourniquet placed over it. Before inflating the tourniquet, the leg is exsanguinated using an eshmarkbandage. The tourniquet is inflated to 350 mm Hg.

A skin incision is made that extends from approximately 6 cm inferior to the head of the fibula to the lateral maleolus region. The incision is carried down to the fascia and exposes the

peroneus longus muscle (Fig. 8, 9). Dissection is continued under the fascia of the lateral compartment in a posterior direction towards the septum. At this point the muscle is retracted and raised off the fibula from a posterior to anterior direction until the anterior edge is reached (Fig. 10, 11).

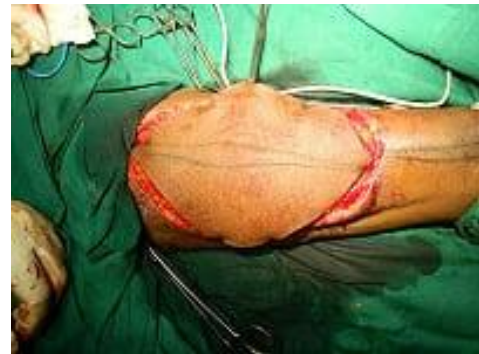

Fig. 8.

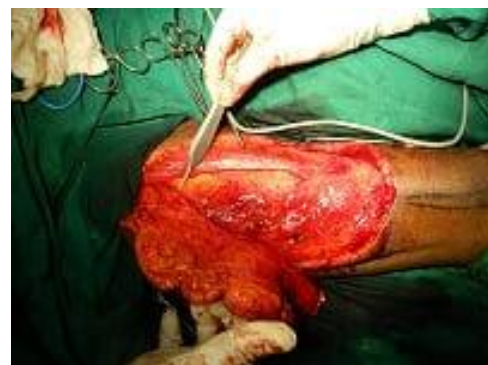

Fig. 9.

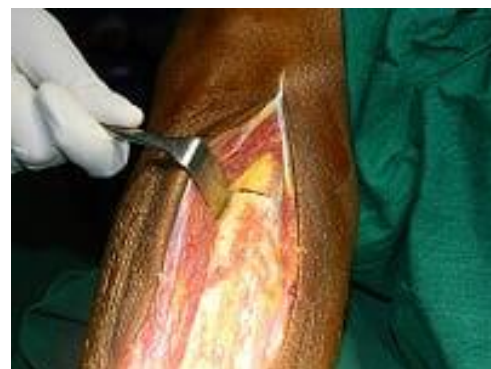

Fig. 10.

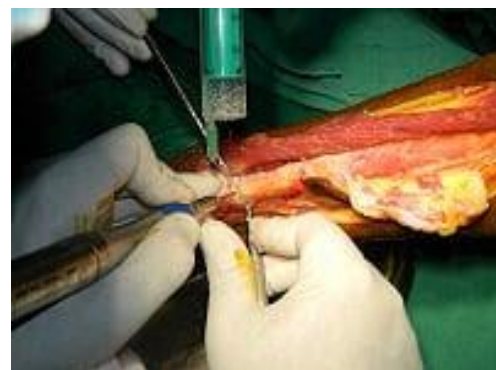

Fig. 11.

The anterior crural septum is then incised and the tissue reflected to give access to the anterior compartment. The anterior tibial artery and vein and the nerve are identified and preserved with gentle retraction (Fig. 9). Dissection is continued toward the interosseous septum. Once the septum is reached, it is incised and the posterior tibialis muscle is identified. This muscle is noted for the chevron appearance of its fibers. Dissection is then directed posteriorly and the soleus and flexor hallucis longus muscle are reflected off the fibula. With the aid of curved periosteal elevators, the periosteum is dissected approximately 8 cm above the inferior head of the fibula. This dissection is done carefully so as not to injure the peroneal vessels that run intimately close to the fibula on its medial aspect. Once the retractors are placed and visualized circumferentially, an osteotomy is made and repeated approximately 1 cm above. (Fig. 12, 13) The intervening free bone segment is removed and the peroneal pedicle is identified directly under the posterior tibialis muscle. (Fig. 14, 15) The pedicle is ligated and divided. A single osteotomy is made superiorly approximately 8 cm below the head of the fibula. Once this osteotomy is completed the fibula is able to be rotated laterally, which allows for a better dissection of the pedicle. The dissection is extended from inferior to superior while taking care to identify and ligate branches from the pedicle. Once the take-off of the peroneal artery is reached at the junction of the posterior tibial artery, the artery and the committal veins are isolated and the tourniquet is deflated (Fig. 10). Hemostasis is achieved while the flap is allowed to reperfuse for approximately 30 minutes before harvesting and transferring to the head and neck.

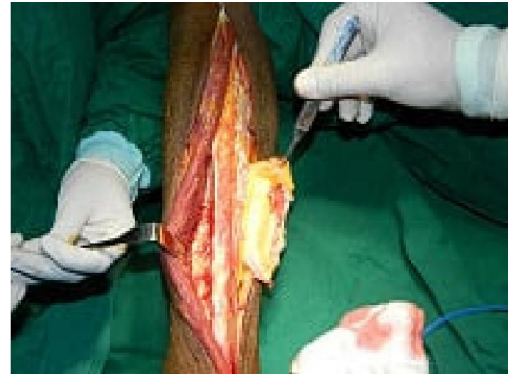

Fig. 14.

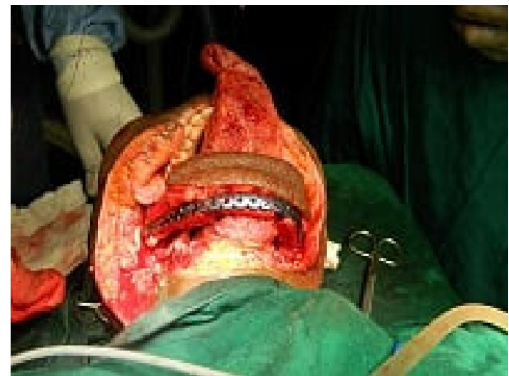

Fig. 15.

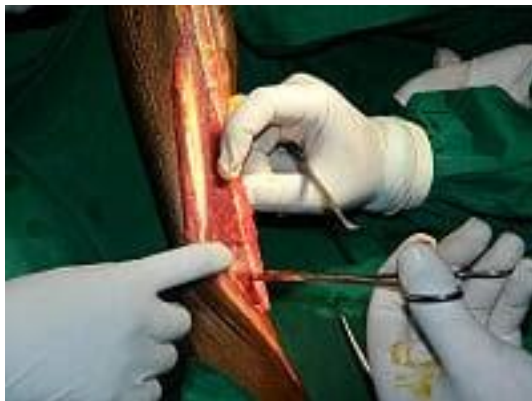

Fig. 12.

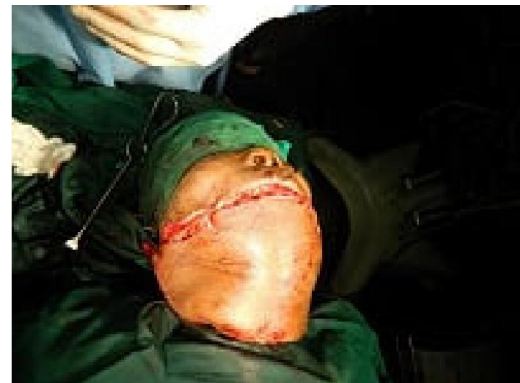

Fig. 16.

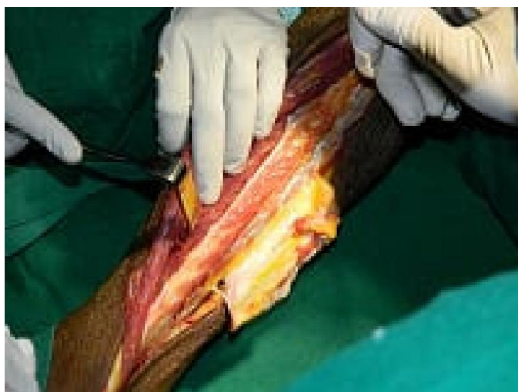

Fig. 13.



Fig. 17.

Raising an Osteoseptocutaneous flap

The raising of the fibula osteoseptocutaneous flap is slightly different from the bone-only flap because the dissection must incorporate the skin island flap. The initial marking of the flap incorporates the necessary island of skin to be harvested. The skin island is placed at the junction of the middle and lower third of the fibula, because skin perforators are of greater caliber in this region, particularly the septocutaneous perforators. The placement of the skin island can be facilitated with a Doppler image of the skin perforator before designing the skin paddle.

Once the incision is made and carried to the fascia, a subfascial dissection is directed out towards the intermuscular septum. At this point, attention is directed at identifying perforators to be incorporated on the skin flap. If the skin island is not centered over the perforators, the skin paddle can be readjusted to incorporate the perforators in a more ideal fashion. The elevation is the same until the posterior dissection is reached. The posterior aspect of the skin island is incised with careful attention to incorporate the perforators. In cases in which the perforators are tenuous, a cuff of the soleus and flexor hallucis longus muscle is incorporated to capture the musculocutaneous perforators to the skin paddle. The remainder of the flapelevation is the same as previously described. Closure of the fibula donor site is done by loose reapproximation of the muscles. Some clinicians advocate that the flexor hallucis longus muscle be sutured to the tibialis posterior muscle and the remaining interosseous membrane to preserve great toe flexion. The muscle closure is over a drain. The skin defect is grafted by harvesting a split-thickness skin graft from the thigh and transferring to the donor site. (Fig: 16) A bolster dressing may be placed followed by posterior splint. The leg is then elevated to decrease edema. The cast and bolster dressing are removed approximately 6 days later. The patient is then allowed to return to function with the aid of physical therapy.

Osteotomy of the fibula

Once the fibula is harvested, the flap is transferred to the head and neck, where the recipient site had been prepared. In cases in which only a straight segment is needed, the preparation is straightforward. When the bony segment to be replaced necessitates either a single or multiple osteotomies of the fibula to be made, we use a flexible plastic ruler to aid in measuring and planning the closing osteotomies. Once the segment is measured, a triangular segment is removed so as to give the necessary closing of the fibula bone to recapitulate the native curves of the mandible. Before performing the osteotomy, the periosteum is incised and elevated, and the pedicle is protected with periosteal elevators. The inset of the fibula is usually performed by placing a single screw from the construction bar into each fibula segment. Optimization of the height differential between the native mandible and the fibula in selected patients may be achieved by placing the fibula approximately 1 cm superior to the inferior border of the mandible. (Fig. 16,17)

This technique may take away the ideal facial contour. An alternative method to increase the bony height of the fibula to

improve the placement of dental implants is to perform a double-barrel fibulaplacement, which improves the height at the cost of decreasing the pedicle length. The remaining steps of the inset are done by arranging the most appropriate geometry of the pedicle, and then the anastomosis of the vessels is performed under the microscope using 9-0 nylon sutures.

Alt flap

Perforators were marked with the help of a hand held Doppler device (10 MHz) on a line extending from anterior superior iliac spine to the lateral border of patella. Two strong signals were found, about 4 cm apart both proximal and distal to the mid-point of the marked line. The 8x14 cm flap was marked around these perforators. The flap dissection was started in the usual manner that is from medial to lateral in the subfascial plane. After about 3 cm of the subfascial dissection the two perforators were identified which were coming from the medial half of the rectus femoris muscle and entering the overlying deep fascia (Fig. 11). Their positions corresponded to the Doppler marks. Both were > 1 mm in diameter. These two perforators were traced proximally by intramuscular dissection through the rectus femoris muscle and were found to be coming from a separate branch of lateral circumflex femoral artery. This vessel travelling in the septum between rectus femoris and vastus medialis muscle was traced. At this point, it was decided to identify the anterolateral thigh flap perforators before sacrificing these or changing the plan. The dissection was started from lateral to medial direction. No substantial perforator was found coming through the vastus lateralis or the lateral septum on which free flap could be raised. The skin paddle was raised according to the original plan based on these two perforators. A pedicle length of about 7 cm was harvested (Fig. 12). There were two veins accompanying a single artery. Proximally the vessel size was about 2 mm. The flap was inset in the forearm defect. End-to-side arterial anastomosis with brachial artery and two venous anastomosis were done. The flap survived completely. The donor site was covered by split thickness skin graft. The flap and donor site healed well.

DISCUSSION

Ameloblastic carcinoma is a rare neoplasm that represents a challenge in its diagnosis, treatment, and prognosis. Information regarding its clinical features is scanty. According to Benlyazid *et al.* in 2007 (Benlyazid *et al.*, 2007), a total of 67 cases of ameloblastic carcinoma have been reported in the literature including one case reported by them. Ameloblastic carcinoma has been reported to arise either de novo, ex odontogenic cyst, or ex ameloblastoma (Benlyazid *et al.*, 2007). Majority originates de novo and the remaining are malignant transformation of an ameloblastoma (Fig. 5).

Ameloblastic carcinoma shows cytologic features of malignancy but is otherwise recognizable as an ameloblastoma (Slootweg and Müller, 1984). The clinical presentation of ameloblastic carcinoma is variable, such as a cystic lesion with benign clinical features or a large tissue mass with ulceration, bone resorption, and tooth mobility. Clinically, they cause expansion of the jaw, grow rapidly, frequently cause pain and

results in perforation of the cortex (Eversole, 1999). 'Expansion' or hard mass' is the most common chief complaint followed by pain or discomfort, toothache or tooth mobility, a non-healing extraction site, ulcer or fistula, facial asymmetry and trismus. Perforation of the cortex and rapid growth of the lesion with parasthesia of the lower lip may also be the presenting features, though not essential features. Although rare, these lesions have been known to metastasize mostly to the lung or regional lymph nodes. It is located most frequently in the posterior mandibular region (Akrish *et al.*, 2007). Ameloblastic carcinoma does not seem to show any age group predilection, it appears more frequently in men (2/3 of cases) and involves more often the mandible (2/3 of cases). According to Sciubba *et al.* age range of the patients varies widely with a range of 51–84 years, with a mean age of 53.5 years and a male to female ratio of 1.5:1. The location of the tumour is 80% in the mandible as per the available literature (Dhir *et al.*, 2003). The differential diagnosis between ameloblastoma and ameloblastic carcinoma is dependent on the integration of histologic changes with demographic features and biologic behavior. The diagnostic criteria of an ameloblastic carcinoma that de-differentiated from ameloblastoma are based on cytologic atypia and an increased mitotic index (Slater, 2004). In cases where ameloblastic carcinoma arise de novo, the microscopic distinction from ameloblastoma is not always obvious and may be subjective. Because numerous mitotic figures are unusual in ameloblastoma, cases where they are sufficiently numerous probably justify the diagnosis of ameloblastic carcinoma. Available literature suggests that the diagnosis of ameloblastic carcinoma is based on several admittedly arbitrary features.

Analysis has shown that there are four features namely:

1. Higher proliferative mitotic index emphasized by higher mitotic activity (Gardner, 1996), higher proliferating cell nuclear antigen expression and higher Ki67 (Akrish *et al.*, 2007);
2. Nuclear atypia such as nuclear pleomorphism and basilar hyperplasia;
3. Hyperchromatic nuclei of basaloid cells; and
4. Other features of malignancy such as perineural or perivascular invasion.

The clinical course is reported as typically aggressive, with extensive local destruction and distant metastatic spread if left untreated. This criterion seems to be the major factor of prognosis, with preferentially a haematogenous spreading way. However, metastatic lymph nodes have been described. In addition, this relatively high risk of distant metastasis contrasts with the behaviour of squamous cell carcinomas that spread rather by the lymphatic way. The most involved site of metastasis is the lung, but brain or bony locations have been reported. Wide local excision is the treatment of choice. Some authors advocate 2–3 cm bony margins by the means of an en-bloc removal (Datta *et al.*, 2003; Avon *et al.*, 2003). Cervical lymph node dissection should be considered when there is obvious lymphadenopathy. Radiotherapy and chemotherapy seem to be of limited value; however, these methods need to be considered when there is a locally advanced or metastatic disease not amenable to surgical resection. Close periodic

reassessment with a long period of follow-up (at least 10 years) is mandatory.

Extensive composite defects of the lower jaw are defined as those that involve skin, mandible, oral mucosa, and soft tissues. The enormous size and multilayered nature of these defects challenge most of the current reconstructive techniques. For reconstruction of extensive composite mandibular defects in 36 advanced oral cancer patients, two free flaps were used simultaneously in a complementary fashion. The aim was to provide bone reconstruction and adequate soft-tissue coverage in an optimal form.

There are various methods available for reconstruction of segmental mandibular defects: nonvascularized bone grafts, titanium reconstructive splints or microsurgical techniques that allow the use of vascularized bone. Among these "modern" methods the fibula, iliac crest and the scapular flaps have a certain role in mandible reconstruction. Free rib or radius has only a limited place. First to perform mandible reconstruction using a free fibula transfer was Hidalgo (Eversole, 1999). In 1991 he also realized that this technique could be applied for most of the mandible reconstructions (Dhir *et al.*, 2003). Fibula has a double vascularization, i.e. endosteal and periosteal supply. This aspect is of particular importance, since it makes possible to perform multiple segmental osteotomies without jeopardizing bone viability that is due to added advantage of its periosteal vascularization. Such freedom is very important for mandible shape reconstruction. Fibula free flap is used for mandible defects reconstruction in oncology, osteomyelitis as well as for the treatment of comminuted fractures in selected edentulous patients with severely atrophic mandible. There is sufficient amount of fibula flap length available. The 25 cm availability exceeds the span of any mandible defect to be reconstructed. The flap has a long vascular pedicle (upto 8 cm) and vessels have a large caliber (2–3 mm the artery and 3–4 mm the vein).

Fibula is a bone with regular shape and constant thickness along its length and its characteristic segmental blood supply allows a great freedom for multiple osteotomies in multiple positions. If the osteotomies are performed before the vascular pedicle ligation, the ischemia time is shorter and the chances to transfer a viable bone increase. We increase the flap dissection and preparing time (3 hours) in order to decrease the ischemia time (1 – 1 ½ hours).

Free fibula flap in mandible reconstruction allows a good three-dimensional shaping especially for the mandibular basilar edge. However, the thickness of the fibula bone does not give the liberty of simultaneous reconstruction of both basilar edge and alveolar bone.

There are several procedures specially developed to overcome the lack of alveolar bone that leads to facial asymmetries due to lip or cheek ptosis on the operated side. Jones used a double fibular flap ("double barrel") folded in such a way to allow reconstruction of both basal mandibular edge as well as alveolar bone. The main disadvantage is the fact that the fibular fragment is too voluminous with respect to alveolar bone reconstruction needs. In this way the bone may fill the

vestibular cul-de-sac and induce ulcerations. To overcome these problems, Lee obtained alveolar bone reconstruction using a vascularized fibular segment to reconstruct the inferior basal portion of the neo-mandible, while a non-vascularized residual fibular segment was used to simulate the superior alveolar portion. The "double barrel"-type flap is not suitable for multiple mandible osteotomies; this disadvantage disappears for non-vascularized fibular bone flaps. To obtain a corresponding height of fibular bone Chiapasco proposes bone distraction. (Review and update of odontogenic carcinomas, Benlyazid *et al.*, 2007; Slootweg and Müller, 1984; Eversole, 1999; Akrish *et al.*, 2007; Dhir *et al.*, 2003; Slater, 2004; Gardner, 1996; Datta *et al.*, 2003; Avon *et al.*, 2003)

The most important issues in our experience was the type of the bone fixation. While the plastic surgeons preferred the miniplates, the OMF surgeon favored the reconstruction plates. The miniplates are easy to manipulate and offer an easy and safe fixation. However, especially in anterior mandibular defects, it is difficult to maintain the occlusal plane as requested by the OMF Surgeon. Finally, in order to maintain the occlusal relation we used the reconstruction plates. These were moulded over the mandible before the segmental resection to obtain the accurate template for the shape. The plate is taken to the donor leg for fibular bone shaping and fixation. Finally the complex bone-template is transferred and fixed to the mandible according to the previous plan. (Fig. 4)

The fibula has enough thickness and resistance to allow dental implants. However in our series none of the patient was interested in further improving the functional outcome. The anterolateral thigh flap can provide a large skin paddle nourished by a long and large-calibre pedicle and can be harvested by two-team work. Most importantly, the donor-site morbidity is minimal. However, the anatomic variations decreased its popularity. By adapting free-style flap concepts, such as preoperative mapping of the perforators and being familiar with retrograde perforator dissection, this disadvantage had been overcome gradually. Furthermore, several modifications widen its clinical applications: the fascia lata can be included for sling or tendon reconstruction. The bulkiness could be created by including vastus lateralis muscle or de-epithelization of skin flap.

The pliability could be increased by suprafascial dissection or primary thinning, the pedicle length could be lengthened by proximally eccentric placement of the perforator, and so forth. Combined with these technical and conceptual advancements, the anterolateral thigh flap has become the workhorse flap for soft-tissue reconstructions from head to toe.

We believe that in selected cases, the double free-flap procedure for one-stage reconstruction of massive mandibular defects is justified because it is safe and effective and improves the quality of life and the number of days spent outside the hospital for these patients.

REFERENCES

- Akrish S, Buchner A, Shoshani Y, Vered M, Dayan D. 2007. Ameloblastic carcinoma: report of a new case, literature review, and comparison to ameloblastoma. *J Oral Maxillofac Surg.*, 65(4): 777–783.
- Avon SL, McComb J, Clokie C 2003. Ameloblastic carcinoma: case report and literature review. *J Can Dent Assoc.*, 69(9):573–576.
- Benlyazid A, Lacroix-Triki M, Aziza R, Gomez-Brouchet A, Guichard M, Sarini J. 2007. Ameloblastic carcinoma of the maxilla: case report and review of the literature. *Oral Surg Oral Med Oral Pathol Oral Radiol Endod.*, 104(6):e17–e24.
- Datta R, Winston JS, Diaz-Reyes G, Loree TR, Myers L, Kuriakose MA, Rigual NR, Hicks WL Jr 2003. Ameloblastic carcinoma: Report of an aggressive case with multiple bony metastases. *Am J Otolaryngol.*, 24(1):64–69.
- Dhir K, Sciubba J, Tufano RP 2003. Ameloblastic carcinoma of the maxilla. *Oral Oncol.*, 39(7):736–741.
- Eversole LR 1999. Malignant epithelial odontogenic tumours. *Semin Diagn Pathol.*, 16(4):317–324.
- Gardner DG 1996. Some current concepts on the pathology of ameloblastomas. *Oral Surg Oral Med Oral Pathol Oral Radiol Endod.*, 82(6):660–669.
- Review and update of odontogenic carcinomas. *Oral Surg Oral Med Oral Pathol* 54(3):299–303.
- Slater LJ. 2004. Odontogenic malignancies. *Oral Maxillofac Surg Clin North Am.*, 16(3):409–424.
- Slootweg PJ, Müller H 1984. Malignant ameloblastoma or ameloblastic carcinoma. *Oral Surg Oral Med Oral Pathol.*, 57(2): 168–176.
