



ISSN: 0975-833X

CASE STUDY

A CASE –HEMANGIOMA WITH HEMORRHAGIC CYST OF UPPER EYELID

Dr. Hansa Thakkar, *Dr. Hetal Chhatbar and Dr. Rohit Dureja

Maneklal & Jagjivan Western Regional Institute of Ophthalmology, Ahmedabad

ARTICLE INFO

Article History:

Received 15th June, 2015
Received in revised form
15th July, 2015
Accepted 20th August, 2015
Published online 16th September, 2015

Key words:

Capillary hemangioma, Ultrasound bio
microscopy, Hemorrhagic cyst.

ABSTRACT

Capillary hemangioma is a common vascular lesion occurring in 1-2% in infants, predilection for girls. It presents as superficial cutaneous lesion, subcutaneous lesion or deep orbital tumour. A 1.5 year female child presented with sudden swelling of Right eye upper eyelid since ten days. No systemic complains. A purplish mass was seen over the right upper eyelid with conjunctival chemosis. On ultrasound and ultrasound biomicroscopy 21.13*21.48 mm vascular mass with hemorrhagic cyst was noted. On CT scan 2.7*2.0 cm well defined slightly hyper dense mass with fluid field level s/o hemangioma. Drainage of the mass was done and sent for analysis and supplemented by injection triamcinolone. Mass has regressed and patient is satisfied. Hence have reported a vascular tumour of upper eyelid. Early diagnosis and treatment plays a great role in this condition.

Copyright © 2015 Hetal Chhatbar. This is an open access article distributed under the Creative Commons Attribution License, which permits unrestricted use, distribution, and reproduction in any medium, provided the original work is properly cited.

Citation: Hetal Chhatbar, 2015. "A case–Hemangioma with hemorrhagic cyst of upper eyelid", *International Journal of Current Research*, 7, (9), 20102-20105.

INTRODUCTION

Capillary hemangioma is benign periorbital tumour. Its present in 1-2% of all births with 3:1 ratio of females to males. (Haik *et al.*, 1994; Iwamoto and Jakobiec, 1979; Drolet *et al.*, 1999) The incidence of orbit and eyelid hemangioma is 1/10 that of systemic hemangioma, which occurs in 10% of all children by one year of age. (Buckmiller *et al.*, 2009) It is abnormal proliferation of normal tissue in a normal location, namely endothelial cells. (Haik *et al.*, 1994; Iwamoto and Jakobiec, 1979) It present as a cutaneous, subcutaneous, or orbital lesion. (Haik *et al.*, 1979) It can cause mechanical ptosis, amblyopia from induced astigmatic anisometropia, strabismus, or occlusion. (Schwartz *et al.*, 2006) It may change colour with crying; and it may blanch with pressure and have a spongy consistency. It is without pulsation and no bruit. (Koursh *et al.*, 2009)

Case History

A 1.5 year old female child presented with a tender, right upper eyelid swelling of ten days duration. (Figure 1) Patient had consulted to an outside ophthalmology clinic and oral antibiotic medication in the form of syrup amoxicillin in dose of 50mg/kg given but the oedema

does not subside and gradually increased in size. This leads to the patient quite pain. He had no other systemic symptoms and no any facial muscle weakness. Past medical and surgical histories were unremarkable. Patient denied any eyelid surgery, injectables, or ocular history. The patient was not on any medications. Family and social history were non-contributory. Birth history full term, normal vaginal delivery with birth weight 2.6 kg with no neonatal care unit admission no any other postnatal complications.

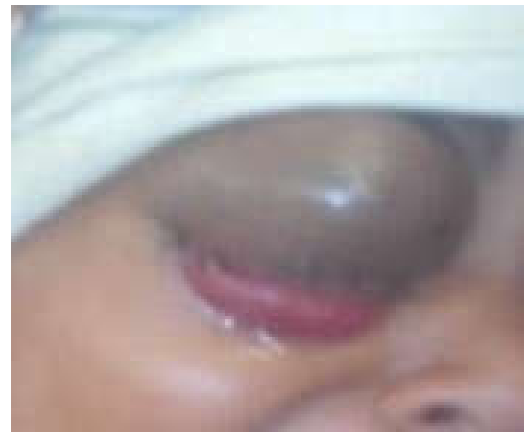

Figure 1. hemangioma involving right eye upper lid with Conjunctival Chemosis

*Corresponding author: Dr. Hetal Chhatbar,
Behind Rangchuli, Shyamji Road, Mandvi-Kutch, Gujarat

On clinical examination, the patient was uncooperative for visual acuity. Intraocular pressure by applanation was 17 mm Hg in right eye and 15 mm Hg in left eye. Ductions were full, and versions were comitant. Pupils were equal, round, and reactive to light. There was no afferent Pupillary defect. Ptosis evaluation was performed bilaterally: the right eye had a palpebral fissure of 6 mm, no lagophthalmos, with severe Ptosis and eyelid chemosis, while the left eye had palpebral fissure of 9 mm, no lagophthalmos. There was palpable purplish orbital mass over right upper eyelid and no resistance to retropulsion. Hertel exophthalmometry findings were normal, with 19 mm of protrusion bilaterally. Slit-lamp examination and dilated fundus examination were normal bilaterally, with no palpebral conjunctival follicles or lacrimal gland enlargement. Other than the isolated right eyelid swelling, the face was symmetrical, and there was no evidence of other facial swelling.

The patient had normal facial motor movement with no signs of weakness or paralysis. In addition, the patient had a relatively normal tongue on examination.

Laboratory testing done

Complete blood count, Metabolic panel, Thyroid stimulating hormone, thyroid-stimulating immunoglobulin index, erythrocyte sedimentation rate, C-reactive protein. Rheumatoid factor, HIV 1 and 2, Tuberculin skin tests. All investigations were within normal limits.

On ultrasound and ultrasound biomicroscopy 21.13*21.48 mm vascular mass with hemorrhagic cyst was noted. (Figure 2)

Drainage of the mass was done under general anaesthesia with help of 30 gauge hypodermic needle and sent for Histopathological examination also supplemented by injection triamcinolone. She is continuing to be followed for further monitoring of his eyelid oedema.

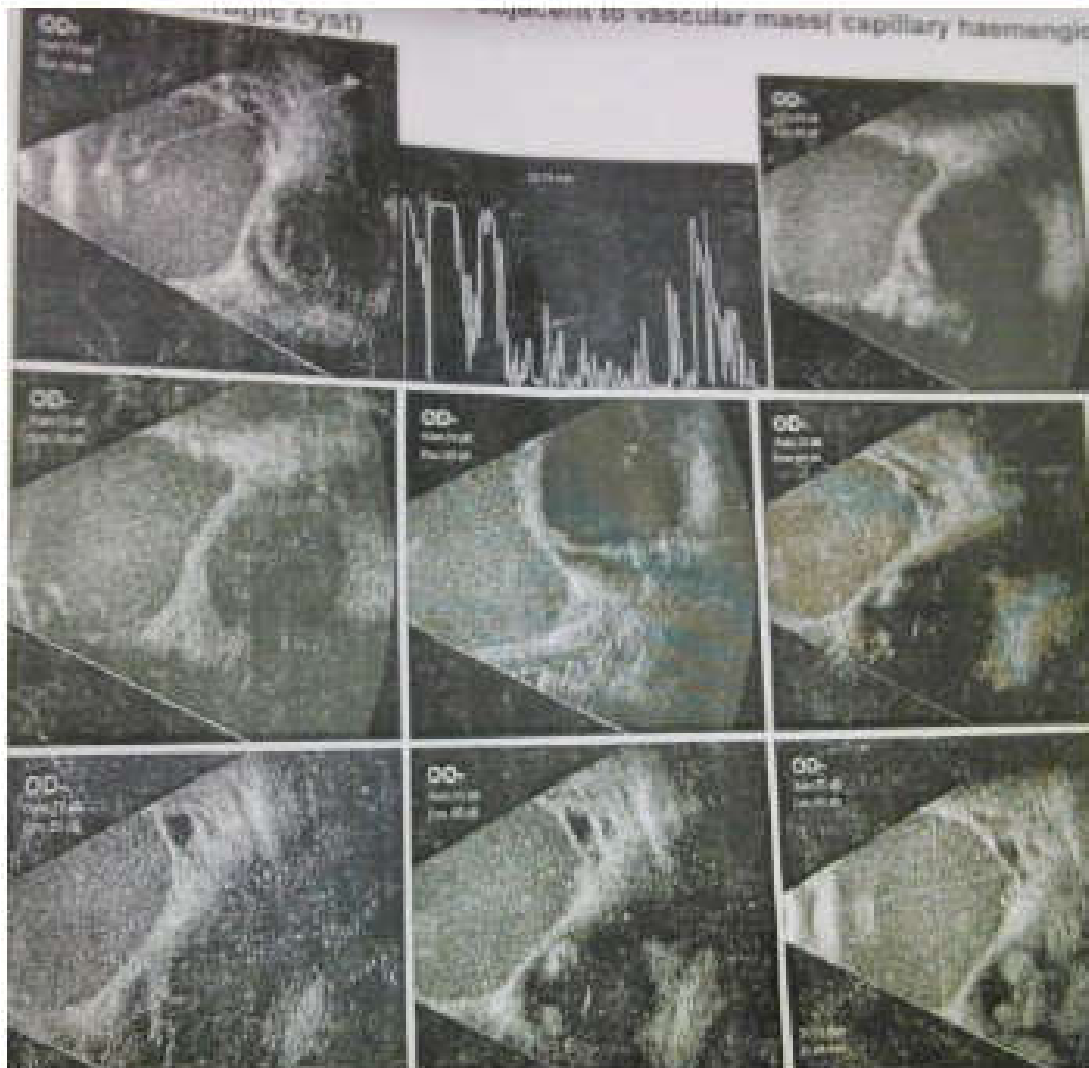


Figure 2. RE USG showing upper eyelid tumor displacing the globe

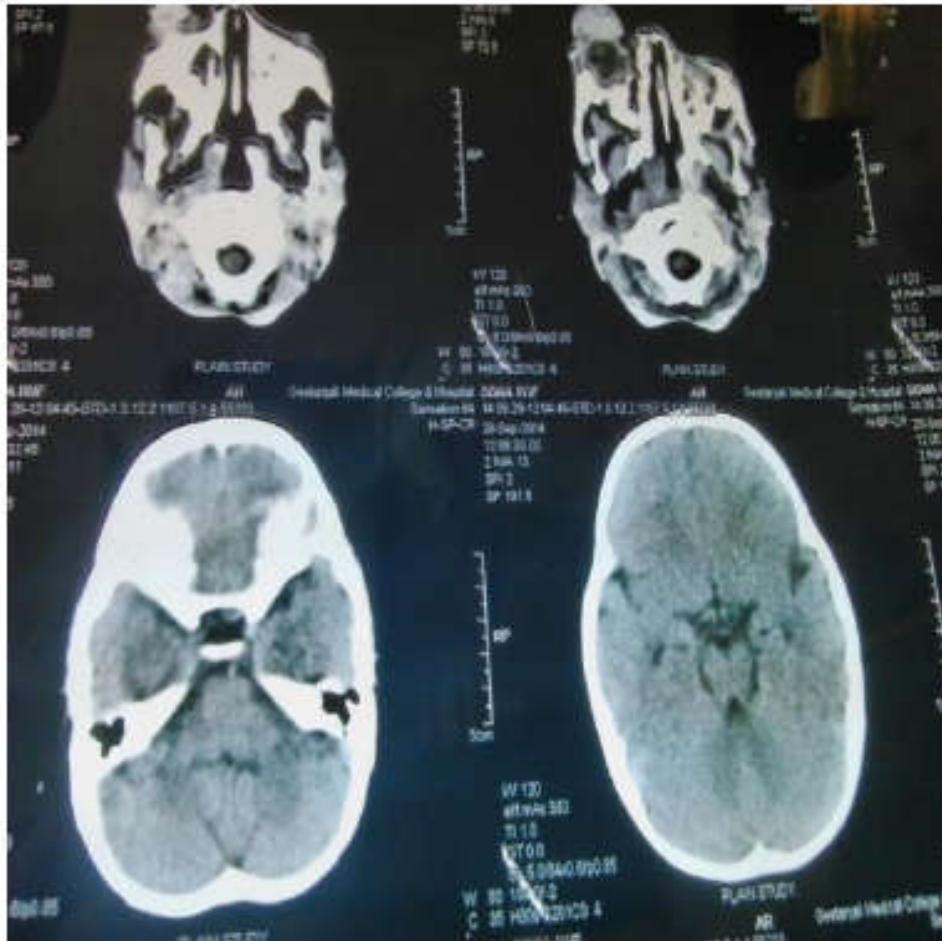


Figure 3. RE CT scan showing Hemangioma displacing the globe

DISCUSSION

Because of the nonspecific appearance of the eyelid oedema, the initial differential diagnosis was very broad, encompassing infection, thyroid orbitopathy, blepharochalasis, angioedema, lymphedema, allergic or contact dermatitis, eyelid malignancy, periorbital pseudotumor, and eosinophilic granuloma. Eyelid infections may present with eyelid oedema. Periorbital infections are preseptal and can be caused by trauma, bacteremia, or upper respiratory illnesses. Patients experience eyelid indurations, erythema, and tenderness. Orbital cellulitis have severe, including proptosis, pain on eye movement, ophthalmoplegia with diplopia, and decreased visual acuity. Thyroid orbitopathy can cause chronic eyelid oedema, although it is usually bilateral and occurs in older individuals (40-60 years of age). It is associated with lagophthalmos, eyelid retraction, and proptosis. It can be excluded by laboratory tests and orbital imaging studies. Blepharochalasis is usually bilateral, characterized by recurrent episodes of nonpainful, nonerythematous upper eyelid swelling that usually begins in childhood or adolescence. These episodes last for two days, but recurrent episodes can cause the eyelids to become discoloured, thin, and wrinkled, with classic appearance of tissue paper.

These episodes decrease in frequency as patient ages. Treatment is primary surgical. (Koursh *et al.*, 2009).

Lymphedema is usually the result of invasive surgical procedures that result in lymphoceles or lymph fistulas. Lymphorrhea is usually a clear, amber-colored fluid unlike the dark fluid seen in our patient.

Allergic or contact dermatitis could also present with eyelid swelling. It occurs with a variety of allergens, and patients present with pruritus and inflammation at the affected site. A unilateral presentation is uncommon. Diagnosis can be made clinically with detailed history, and is confirmed by patch testing. Eyelid malignancies, periorbital pseudotumor, and eosinophilic granulomas may be diagnosed by biopsy.

Owing to lack of response to oral antibiotic medications, CT scan of the orbits with and without contrast was obtained. The CT scan showed right globe normal in size, but displaced. Right periorbital oedema consistent with soft-tissue swelling was noted. (Figure 3)

Histopathological evaluation of the specimen showed well-developed, flattened, endothelium-lined capillary channels of varying sizes in a lobular configuration. Involuting lesions show increased fibrosis and hyalinization of

capillary walls with luminal occlusion. All stains, including Gram stain, and special stains for microorganisms (Periodic acid-Schiff and acid-fast bacilli) were negative, and no polarizable foreign material was identified. No eosinophils were noted. Based on the clinical symptoms, Histopathological results, ultrasound and CT scan a diagnosis of capillary hemangioma with hemorrhagic cyst was made. In our patient, after surgical drainage and with injection triamcinolone, the mass gradually regressed and patient will be carefully monitored for visual acuity and any signs of amblyopia or recurrence of mass.

REFERENCES

- Buckmiller L, Dyamenahalli U, Richter GT. Propranolol for airway hemangiomas: Case report of novel treatment. *Laryngoscope*, 2009;119(10):2051–2054.
- Drolet BA, Esterly NB, Frieden IJ. Hemangiomas in children. *N Engl J Med.*, 1999;341:173–181.
- Haik BG, Jakobiec FA, Ellsworth RM, Jones IS. “Capillary hemangioma of the lids and orbit: an analysis of the clinical features and therapeutic results in 101 cases.” *Ophthalmology*, 1979;86(5):760–792.
- Haik BG, Karcioglu ZA, Gordon RA, Pechous BP. Capillary hemangioma (infantile periocular hemangioma) *Surv Ophthalmol.*, 1994;38(5):399–426.
- Iwamoto T, Jakobiec FA. Ultrastructural comparison of capillary and cavernous hemangiomas of the orbit. *Arch Ophthalmol.*, 1979;97:1144–1153.
- Koursh DM, Modjtahedi SP, Selva D, Leibovitch I. The blepharochalasis syndrome. *Surv Ophthalmol.*, 2009; 54:235-44.
- Schwartz SR, Blei F, Ceisler E. Risk factors for amblyopia in children with capillary hemangiomas of the eyelids and orbit. *JAAPOS*, 2006;10:262–268.
